

UNIVERSITY OF STRATHCLYDE

# Evaluation of a Custom Made Anatomical Guide for Orthognathic Surgery

---

Submitted in Fulfillment of the  
Requirements for the Degree of Master of  
Philosophy (MPhil)

**Ms Elaine Baird**  
2019

Department of Design, Manufacturing and Engineering Management

Faculty of Engineering

University of Strathclyde

# Declaration of Authenticity

This thesis is the result of the author's original research. It has been composed by the author and has not been previously submitted for examination which has led to the award of a degree.

The copyright of this thesis belongs to the author under the terms of the United Kingdom Copyright Acts as qualified by University of Strathclyde Regulation 3.50.

Due acknowledgement must always be made of the use of any material contained in, or derived from, this thesis.'

*Ms Elaine Baird*

*2019*

# Abstract

Orthognathic surgery is a routinely used surgical technique for the correction of dento-facial deformities. During a Le Fort I orthognathic procedure the maxilla is surgically separated from the skull and the surgical positioning wafer is placed between the occlusal surfaces of the upper and lower dentition. However, the physiological response to general aesthesia results in loss of muscle tone in the mandible, which has a profound influence on the correct amount of maxillary advancement required. The expertise and visual judgement of the surgeon is relied upon to foresee and eliminate this potential source of error. However, this may not be possible to achieve in all cases, therefore there is a need for a device to guide the surgical position of the maxilla independent of the mandibular dentition.

The aim of this study was to design and validate a custom made anatomical repositioning surgical framework for accurately repositioning the maxilla independently of the mandible during a Le Fort I osteotomy.

A single plastic anatomical skull was scanned using a helical Computed Tomography (CT) scanner. Utilising 3D manipulation software, forty-three Le Fort I orthognathic surgery movements were planned. A custom made anatomical repositioning guide was designed and 3D printed for all movements. Each guide was used to reposition the maxilla of the physical skull and then laser scanned using a GOM blue light scanner. GOMinspect software was used to compare the planned and physical position of the repositioned maxilla. The results of the experiment were statistically evaluated.

# Acknowledgments

I would like to express my sincere gratitude to Professor A.F. Ayoub for providing me with the motivation and enthusiasm to undertake this study.

To Professor X. Yan for his support and providing access to all the necessary academic departments.

To Mr R. Sayer, thank you for your expert knowledge and assistance in operating the CAD computer software programmes. Your invaluable contribution was pivotal in the success of this project.

To Dr Xiangyang Ju for his help and assistance in the statistical analysis of this project.

To Mr F.S Walker, a true friend and colleague, you gave me the encouragement and self belief to undertake and complete my research project. I would like to take this opportunity to thank you for all your support throughout my study.

Thank you to the Head & Neck endowment fund for financially contributing to this study.

Last of all I would like thank my family for their unconditional support. Helen, thank you for all your support and encouragement, and also helping me maintain focus. It is to you I dedicate this thesis.

# Table of Contents

Declaration of Authenticity.....	ii
Abstract.....	iii
Acknowledgments.....	iv
Table of Contents.....	v
List of Tables .....	vii
List of Figures .....	viii
1.0 Introduction .....	1
1.1 Current Methods of Orthognathic Planning .....	4
1.1.1 Photo-cephalometric Planning .....	4
1.1.2 Model Surgery.....	9
2.0 Literature Review .....	13
2.1 Inaccuracies in Model Surgery .....	13
2.2 The Role of the Natural Head Position.....	20
2.3 Three-Dimensional Orthognathic Planning.....	25
2.4 Accuracy of 3D Orthognathic Planning and Rapid Prototyped Wafers .....	26
2.5 Replacing the Distorted Dentition .....	28
2.6 Accuracy of 3D Planning and Rapid Prototyped Surgical Wafers .....	34
2.7 Methods of Intraoperative Maxillary Positioning.....	38
2.8 Navigation Guided Orthognathic Surgery.....	39
2.9 Anatomically Repositioning the Maxilla .....	42
2.10 Custom Made Titanium Bone Plates.....	42
2.11 Custom Made Anatomical Repositioning Splints.....	46
2.12 Summary .....	56
3.0 Material and Methods .....	57
3.1 Aim of Study.....	57
3.2 Study Design.....	57
3.3 The Progress in Developing the Ideal Design of the Anatomical Guide .....	60
3.3.1 Design One .....	60
3.3.2 Design Two.....	62

3.3.3 Final Design .....	63
3.4 Design and Construction of the Anatomical Locating Plates .....	65
3.5 Preoperative Frame Design .....	74
3.6 Digital Simulation of the Orthognathic Surgical Movements of the Maxilla .....	86
3.6.1 Maxillary Advancement .....	86
3.6.2 Maxillary Vertical Height Change .....	87
3.6.3 Combination of Maxillary Advancement and Vertical Height Change .....	89
3.6.4 Maxillary Rotational Movements (Pitch, Roll and Yaw) .....	90
3.6.5 Maxillary Posterior Impaction (Pitch) .....	91
3.6.6 Differential Impactions (Roll) .....	93
3.7 Postoperative Frame Design .....	96
3.8 Physical Simulation of the Orthognathic Surgical Movements of the Maxilla .....	99
3.9 Assessment of the Accuracy of Repositioning the Maxilla with the use of the Custom Made Anatomical Repositioning Guide .....	99
3.10 Superimposition of the CAD Skull and Physical GOM ATOS Scan Data .....	102
3.11 Digitisation of the Anatomical Landmarks .....	105
3.12 Data Analysis .....	107
4.0 Results .....	108
4.1 Superimposition Accuracy of the Physical Skull and the CAD Skull .....	108
4.2 Landmarks Digitisation Errors .....	112
4.3 The Accuracy in Maxillary Repositioning using the Custom Made Anatomical Guide .....	114
5.0 Discussion .....	116
5.1 Error of the Method .....	120
5.1.1 Anatomical Resin Skull .....	120
5.1.2 Image Capture of the Skull .....	120
5.1.3 DICOM Data Imported in 3D Software Package .....	121
5.1.4 Maxillary Surgical Movements .....	122
5.2 Initial Design of the Custom Made Anatomical Repositioning Guide .....	123
5.3 Study Results .....	125
6.0 Conclusion .....	128
7.0 REFERENCES .....	1
8.0 APPENDICES .....	5

## List of Tables

<b>Table 3.6.1.1</b> The Measurements of maxillary advancement in mm .....	86
<b>Table 3.6.2.1</b> Linear height change in the vertical dimension defined as downgraft and impaction .....	88
<b>Table 3.6.3.1</b> Magnitude of maxillary advancement with combined impaction and downgraft.....	90
<b>Table 3.6.4.1</b> Measurement in degrees of maxillary rotation to the left for centre line correction.....	90
<b>Table 3.6.5.1</b> Measurement alteration to the pitch of the maxilla (posterior impaction).	92
<b>Table 3.6.6.1</b> Variation in differential impacts performed to level maxillary occlusal canting.....	94
<b>Table 3.11.1</b> Descriptions of the Twelve Landmarking Points on the Skull Vault and Maxillary Occlusal Surface of the Dentition.....	106
<b>Table 4.1.1</b> The iteration error of the CAD skull and the physical skull when superimposed using GOMinspect software had an error of <1.0mm .....	110
<b>Table 4.1.2</b> Superimposition error in the X, Y and Z coordinates for the six points digitised on the skull vault of the CAD skull and the physical skull.....	111
<b>Table 4.2.1</b> Reproducibility of digitisation of anatomical landmarks on the CAD and physical skull .....	113
<b>Table 4.3.1</b> X, Y and Z mean and median values of each digitised point on the occlusal surface of the maxillary dentition of the physical skull compared with the CAD skull .....	115

# List of Figures

Figure 1.1.1.1 Hard tissue anatomical points and planes identified on a lateral cephalogram .....	5
Figure 1.1.2.1 Clear acrylic final positioning wafer.....	10
Figure 1.1.2.2 Ivory intermediate positioning wafer .....	10
Figure 1.1.2.3 Plane line articulator used for single jaw surgery planning .....	10
Figure 1.1.2.4 Condylar face-bow with orbital pointer .....	11
Figure 1.1.2.5 Semi adjustable articulator .....	11
Figure 1.1.2.6 Skull image superimposed onto the articulator demonstrating the maxilla in relation to the skull transferred to the articulator .....	11
Figure 1.1.2.7 Mounted casts on a semi-adjustable articulator for bi-maxillary orthognathic surgery planning.....	12
Figure 2.1.1 Frankfurt horizontal plane and the axis-orbital plane parallel on the articulator .....	14
Figure 2.1.2 13° angle from the Frankfurt horizontal plane and the axis-orbital plane ....	14
Figure 2.1.3 Maxillary occlusal plane angle recorded by a face-bow following the manufacturer’s instructions.....	15
Figure 2.1.4 The actual maxillary occlusal plane angle recorded by the lateral cephalogram .....	15
Figure 2.1.5 Superimposed lateral cephalogram onto mounted models by face-bow .....	16
Figure 2.2.1 Frankfort horizontal plane marked on lateral photographs.....	21
Figure 2.5.1 Streak artefact visible on CT image .....	28
Figure 2.5.2 Sequence of digital dentition replacement .....	29
Figure 2.5.3 Virtual image of 3D splint design .....	30
Figure 2.8.1 Superimposed maxilla using the IGVD.....	41
Figure 2.10.1 Drilling guide and surface template in situ.....	43
Figure 2.11.1 Virtual design of anatomical repositioning splint .....	47
Figure 2.11.2 Virtual wafer with detachable locating plates.....	48
Figure 2.11.3 3D wafer positioned intraoperatively .....	49
Figure 2.11.4 Drill Guides attached to the occlusal wafer.....	50
Figure 2.11.5 Maxillary positioning arms.....	51
Figure 2.11.6 CAD/CAM designed Y splint .....	52
Figure 2.11.7 Printed Y splint in situ .....	53
Figure 2.11.8 Sectional splint design .....	54
Figure 2.11.9 Post-op splint in situ .....	54
Figure 2.11.10 Key and Keyhole Interlocked .....	56
Figure 3.2.1 DICOM data imported into Mimics software programme .....	58
Figure 3.2.2 STL File showing formation of triangles creating a mesh of a 3D object.....	59
Figure 3.2.3 Maxilla separated from the middle third of the skull.....	60
Figure 3.3.1.1 Frontal image showing preoperative (drill guide) anatomical guide in situ	61
Figure 3.3.1.2 Lateral view showing postoperative design of the anatomical guide in-situ .....	61



Figure 3.3.2.1 Second design of anatomical repositioning guide with independent zygoma plates and magnetic recesses incorporated demonstrating the pre and postoperative positions.....	63
Figure 3.3.3.1 Two magnet recesses in the right and left zygomaxillary locating plates ..	64
Figure 3.3.3.2 Presurgical positioning and drill guide framework.....	65
Figure 3.3.3.3 Lateral view of the final position locating framework in-situ.....	65
Figure 3.4.1 3D Nasal locator with counter sunk holes designed using Onshape CAD software .....	67
Figure 3.4.2 Basic shape of the zygomatic locating plates designed using OnShape CAD software .....	68
Figure 3.4.3 The locating plates overlaid onto the bony surface prior to carrying out a boolean subtraction.....	69
Figure 3.4.4 Boolean subtraction of the skull from the fitting surface of the locating plates .....	70
Figure 3.4.5 Anatomically shaped fitting surface of the locating plates .....	70
Figure 3.4.6 Process of separating the maxilla using "cut orthogonal to screen" function using the Mimics software programme.....	71
Figure 3.4.7 Maxilla separated from the cranial base of the skull .....	72
Figure 3.4.8 Nasal locator fused onto the maxillary segment.....	73
Figure 3.5.1 Presurgical skull imported into Solidworks CAD software programme .....	74
Figure 3.5.2 Nasal locator and left and right zygoma plates positioned onto the CAD assembly using shared co-ordinate systems for Mimics .....	75
Figure 3.5.3 CAD modelling tools were utilised to refine and introduce fixing features on the zygoma plates.....	76
Figure 3.5.4 Frame structure created and parametrically anchored to the nasal locator and the right and left zygoma plates .....	76
Figure 3.5.5 The nasal locator and right and left zygoma plates are now joined to the frame; creating the complete assembly .....	77
Figure 3.5.6 Magnet recesses were created from the split zygoma plates.....	77
Figure 3.5.7 Colour change in the zygoma plates indicate they have been separated from the framework assembly and are now ready for exporting as an STL file.....	78
Figure 3.5.8 Formlab Form2 SLA 3D printer used to print the custom made anatomical repositioning guide .....	79
Figure 3.5.9 Manual repositioning of the support struts prior to printing; ensuring no struts are placed on the fitting surface of the guide .....	80
Figure 3.5.10 Support structures applied post editing .....	81
Figure 3.5.11 Light curing unit used to post cure the guide .....	82
Figure 3.5.12 Framework post curing before the support structures were removed with the use of the snipping tool .....	82
Figure 3.5.13 0.5kg pull neodymium magnets secured within the recess of the guide using cyanoacrylate glue providing retention to the zygomatic plates .....	83
Figure 3.5.14 Magnetic retention secured in position on the zygomatic plates and on the opposing framework.....	84

Figure 3.5.15 Zygomatic locating plates and preoperative framework secured in position using six titanium self-tapping bone screws.....	85
Figure 3.6.1.1 Maxilla advanced 6mm using the "Repositioning" function within the Mimics manipulation programme .....	87
Figure 3.6.2.1 Downward movement of the maxilla increasing the vertical facial height .	88
Figure 3.6.2.2 Upward movement of the maxilla decreased the vertical facial height, reducing the amount of tooth show .....	88
Figure 3.6.3.1 Virtual maxillary advancement and impaction.....	89
Figure 3.6.3.2 Virtual maxillary advancement and downgraft .....	89
Figure 3.6.4.1 The point of rotation was selected on the maxilla posteriorly using "Restricting DOF" tool in Mimics .....	91
Figure 3.6.5.1 Rotational point positioned and fixed on the dental mid-line of upper central incisors.....	92
Figure 3.6.6.1 Rotational point placed on the lingual cusp of upper left first molar and maxilla rotated around the Y axis .....	95
Figure 3.7.1 Postoperative skull STL file with integrated nasal locator imported into Solidworks.....	96
Figure 3.7.2 Duplicate nasal Locator co-located onto the fused nasal locator using the CAD 'Mate' tool.....	96
Figure 3.7.3 Nasal locator on the assembly ready to be co-located with the nasal locator of the maxilla in the final position .....	97
Figure 3.7.4 Nasal locator co-located with the final position nasal locator automatically creating the CAD assembly of the postoperative framework .....	97
Figure 3.7.5 Postoperative framework fully visualised on the CAD skull prior to exporting as an STL file.....	98
Figure 3.7.6 Postoperative positioning framework designed Using Solidworks CAD/CAM software.....	98
Figure 3.9.1 GOM ATOS triple blue light surface scanner .....	100
Figure 3.9.2 Physical skull with postoperative guide secured in position and placed on the rotating table prior to capturing the scan image.....	101
Figure 3.9.3 GOM ATOS scanner capturing the surface image of the physical skull with the postoperative guide in situ .....	101
Figure 3.10.1 CAD skull model and physical scanned skull model imported into GOM Inspect software and initially aligned .....	103
Figure 3.10.2 Main alignment performed showing the CAD skull and the physical skull superimposed .....	104
Figure 3.10.3 "Local Best Fit" was performed by selecting only the skull vault excluding the dentition for further alignment .....	104
Figure 3.11.1 Six points digitised on anatomical landmarks of the skull vault.....	105
Figure 3.11.2 Six point digitised on the maxillary occlusal surface of the selected teeth	106

# 1.0 Introduction

Orthognathic model surgery is the technique used to predict and simulate the movements of the maxilla and mandible prior to the surgical correction of dentofacial deformities. This process plays an important part in obtaining a successful postoperative result. In model surgery the dental casts are repositioned in 3D, for the prediction of the final occlusion and the manufacture of occlusal wafers to guide the surgery. These wafers are used for repositioning the osteotomy segments perioperatively to the planned new position.

Le Fort I osteotomies are usually associated with a change in the vertical position of the maxilla referred to as impaction or down-graft in addition to the horizontal movements. In bi-maxillary (two jaw) surgery a Le Fort I osteotomy is carried out simultaneously with mandibular surgery and in these cases two wafers are constructed, one to guide the mandibular segment and the other to guide the maxillary osteotomy. Le Fort I and bi-maxillary osteotomies are planned using a semi-adjustable articulator with a face-bow registration taken to transfer the maxilla-cranial relationship from the patient to the articulator.

Semi-adjustable articulators and face-bows were designed for prosthetic dentistry and not intended for orthognathic model surgery planning. There are inherent anatomical inaccuracies with the use of these articulators for orthognathic surgery planning that result in unseen and unwanted movements which lead to an

inaccurate surgical outcome. The literature suggests several methods to overcome these errors (Gonzalez and Kingery, 1968; Ellis III et al., 1992; O'Malley et al., 2000; Walker et al., 2008).

In an attempt to overcome the errors associated with orthognathic surgery planning using articulators, 3D physical skull models with accurately replaced plaster dentition were utilised (M. O'Neil et al., 2010). The method allows the surgeon to assess the full complexity of the skeletal deformity in its entirety. However, the process is complex and has a significant cost implication; therefore it is generally reserved for complex cases.

In recent times, the development and use of 3D software programmes and the ability to rapid prototype sterilisable materials have attracted great interest from both the clinical and technical aspects of orthognathic surgery planning. Orthognathic surgery can be planned using Cone Beam CT data of the skull and dentition. The surgical movements of the osteotomy segments are carried out using one of the available 3D computer software packages. On completion of the planning process, a virtual intraoperative repositioning wafer is created which is then converted into a physical device using a 3D printer.

Three-dimensional orthognathic surgery planning negates the need for articulators and face-bow recordings which eliminates the inherent anatomical errors of using these devices for prediction planning. The printing of physical skull models is eliminated as the entire process is planned virtually using a computer software planning package.

Orthognathic surgery planning techniques are ever more advancing and the main focus is to eliminate the articulator systems and plaster models to improve the accuracy in the planning stages.

Another major source of inaccuracy in the prediction planning is using the mandible as a guide to place the maxilla in its correct antero-posterior position at the time of surgery. This source of error has not been resolved yet. It has been shown that during surgery, the patient is in the supine position, the muscles of mastication are relaxed and the mandible can be pushed inadvertently up to 2mm posteriorly, resulting in the maxilla being under advanced surgically (Boucher et al., 1961).

The aim of this pilot study is to utilise a 3D manipulation software package and introduce a new concept of a custom made, anatomically positioned, intraoperative guide for Le Fort I osteotomy without the guidance of the mandibular dentition. The objective of this study is to design and validate a new custom made anatomical repositioning guide to guide the Le Fort I maxillary position.

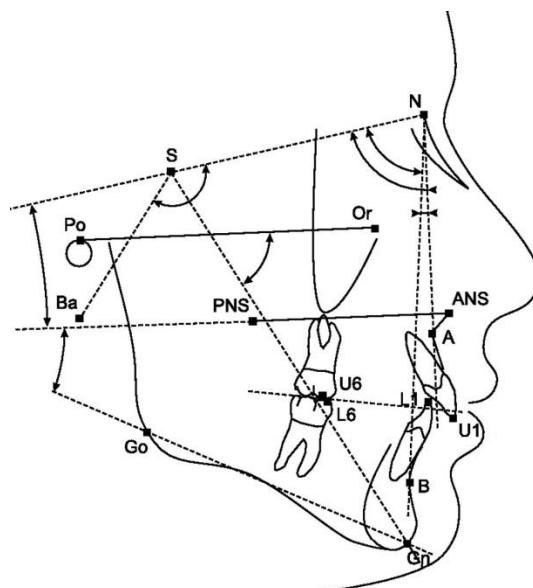
## **1.1 Current Methods of Orthognathic Planning**

Orthognathic surgery planning requires a multidisciplinary team approach; patients requiring orthognathic surgery are commonly referred to an orthognathic clinic for assessment. In some centres the patients are seen by a clinical psychologist first to assess their suitability for orthognathic surgery. A clinical assessment is carried out by the surgeon, orthodontist and a maxillofacial technologist. A facial assessment is performed analysing the lateral and frontal view with the patient in the natural head position (NHP) this enables the assessors to determine the magnitude of soft tissue and skeletal discrepancies. An intraoral assessment determines the magnitude of malocclusion, width and shape of the dental arches, inclination of the central incisors, spacing and crowding of the teeth, the presence of an occlusal cant and curve of Spee. Dental impressions are taken to produce study models to aid in the assessment of arch coordination.

### **1.1.1 Photo-cephalometric Planning**

Prediction planning for orthognathic surgery plays a vital role to achieve a successful surgical and orthodontic outcome in patients with dento-facial deformities. Two dimensional cephalometric planning is a diagnostic tool commonly used to identify dental and skeletal discrepancies of an orthognathic patient, relying on the use of a lateral radiograph (cephalogram) and a 1:1 ratio lateral transparent photograph of a patient.

Traditionally the lateral cephalogram would be used to identify and plot hard tissue anatomical landmarks of the skull, maxilla and mandible with the soft tissue profile also being identified from the lateral cephalogram. This process is known as cephalometric tracing, whereby a sheet of clear matt acetate or tracing paper is secured over the lateral cephalogram and the anatomical landmarks are identified and traced. Linear planes are then identified by linking the anatomical points together. For example, the anatomical point porion (Po) is joined by a line to orbitale (Or), this plane is known as the Frankfort Plane (FP). Planes are also identified for the maxilla, mandible and the upper and lower incisor inclinations. Angular measurements are obtained by linking the anatomical point Sella to Nasion (SN plane) to A point of the maxilla, which is the most concaved aspect of the dental alveolus and SN plane to B point which is defined as the most concaved aspect of the mandibular symphysis. This information is used to assess the relationship of the maxilla to the skull, the maxilla to the mandible and the angle of the upper and lower incisors in relation to the maxilla and mandible respectively (Fig. 1.1.1.1). This is an example of the many diagnostic measurements used to assess skeletal discrepancies.



**Figure 1.1.1.1 Hard tissue anatomical points and planes identified on a lateral cephalogram**

Following the completion of this process, the tracing is placed and correctly aligned on top of the 1:1 lateral photograph providing a hard and soft tissue analysis tool. Using the measurements gathered from the tracing, the dental and skeletal discrepancies can be identified and compared against a set of standardised average measurements in relation to population, gender and age groups. The lateral cephalogram and the 1:1 photograph is then cut up and the maxilla and mandible moved in relation to the skull to achieve an acceptable harmony of the facial profile. The linear movements of the jaws are measured using a ruler and angular changes are recorded using a clear protractor or an ortho grid.

Modern advancements in computer software programmes have enabled two dimensional cephalometric planning to be performed using dedicated software programmes such as computer assisted simulation system for orthognathic surgery (CASSOS) (SoftEnabled Technology Group Limited, Hong Kong), Dolphin Imaging Software (Chatsworth, CA) and Opal Image Viewer (British Orthodontic Society, London, UK). The principle of these software systems are similar to the traditional method of 1:1 cut ups as previously mentioned, however instead the lateral cephalogram and 1:1 photograph are downloaded into the software programme and the hard and soft tissue landmarks are identified digitally. The software system provides linear and angular measurements of the patient's hard and soft tissue profile preoperatively and then from a database of population, age and gender it predicts the estimated angles and linear measurements required to move the maxilla, mandible or a combination of both to produce a harmonious facial profile.



Although 1:1 lateral cephalometric tracing and computer assisted cephalometric tracing provide similar information regarding prediction planning of the surgical correction of dento-facial deformities, there are advantages to utilising the computer based method. Storage of the information is held on a computer database and can be easily accessed. Software programmes provide a more accurate measurement of the hard tissue movements and reduce operator error in manually measuring the movements using a ruler and protractor. The ability to better predict soft tissue changes following hard tissue movements is enhanced, although not fully accurate.

Jones et al., (2007) carried out a study to validate soft tissue prediction using CASSOS prediction planning software when compared to the postoperative cephalogram. Twelve soft tissue landmarks were identified and analysed: glabella (G), nasion (N), pronasale (Pn), columella (Cm), subnasale (Sn), superior labial sulcus (SLs), labrale superius (Ls), labrale inferius (Li), labiomental fold (Lf), soft-tissue pogonion (Pogs), soft-tissue gnathion (Gns) and soft-tissue menton (Mes). The soft tissue prediction plans for both groups were compared against the postoperative lateral cephalograms and evaluated the median difference between each corresponding landmark horizontally and vertically. The author reported that the computer prediction plan underestimated the position of the lips following maxillary advancement in seventeen cases (Group A). The greatest median differences between the CASSOS prediction plan and the postoperative cephalogram were reported at horizontal superior labial sulcus -1.54mm, horizontal

labrale superious -1.20mm and horizontal labiomental fold -1.20mm. Vertical pronasale and vertical menton where the only landmarks to have 95% confidence intervals for median difference greater than  $\pm 2$ mm, the remaining ten landmarks less than  $\pm 2$ mm. CASSOS software prediction programme underestimated the position of soft-tissue menton and overestimated pronasale vertically. Similarly in bi-maxillary osteotomies, in sixteen cases (Group B) out of thirty-three cases evaluated both upper and lower lip positions were reported to be underestimated when compare to the final postoperative lateral cephalogram.

Two-dimensional cephalometric planning allows the patient a greater appreciation as it provides an estimated postoperative photographic prediction in a lateral view that the patient can easily interpret. At the time of consultation the patient must be informed that it is a prediction of the soft tissues and not a guaranteed final result.

Computer assisted cephalometric planning may have greater advantages over traditional methods however it should be noted that both modalities of cephalometric planning are two-dimensional and focus on the lateral skeletal view of a patient. Identifying hard tissue landmarks can be difficult to accurately identify. This may be due to varying factors such as image quality of the cephalogram. Identifying the correct aspect of bi-lateral landmarks such as gonion and the patient's dentition making accurate identification difficult as observed in asymmetric cases (McClure et al., (2005), Gateno et al., (2011)). The operator's lack of experience and ability to accurately locate hard tissue landmarks could also have an effect on the prediction planning. However, the greatest limitation of

cephalometric planning is the inability to accurately predict the postoperative appearance in asymmetric cases (Gateno et al., (2011).

In summary, two-dimensional prediction planning is an acceptable adjunct to orthognathic surgery planning in the vertical and horizontal planes. However, its limitations must be recognised in the diagnosing and planning of asymmetry cases. Predicting asymmetries of the maxilla and mandible is imperative to a successful surgical outcome and patient satisfaction. Therefore, two-dimensional prediction planning is a tool to be used in conjunction with model surgery planning to have a full understanding of the underlying dentofacial deformity.

### **1.1.2 Model Surgery**

Orthognathic model surgery is the technique used to predict and simulate the movements of the maxilla and mandible prior to surgical correction of a dentofacial deformity and plays an important role in obtaining a successful postoperative result. Model surgery simulates the surgical movements of the jaw bones and osteotomy segments for the manufacture of intermediate and final occlusal wafers used to guide the osteotomy segments to the predicted new position (Fig 1.1.2.1 & Fig. 1.1.2.2).

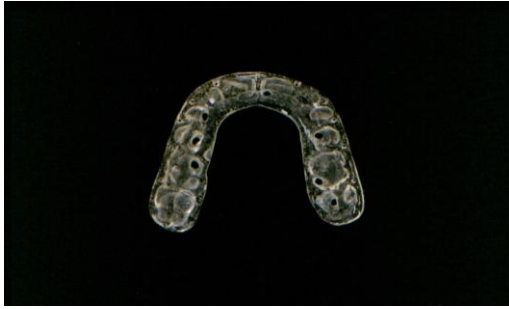

Figure 1.1.2.1 Clear acrylic final positioning wafer

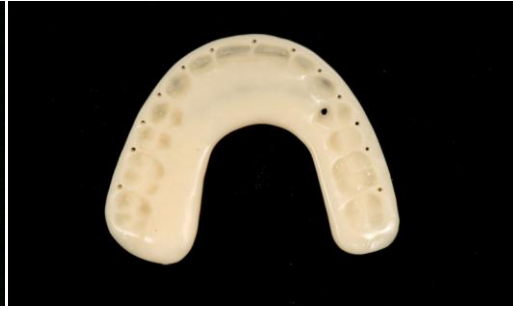

Figure 1.1.2.2 Ivory intermediate positioning wafer

Single jaw surgery including mandibular advancement, setback or maxillary advancement without vertical height change may be simulated successfully using a plane line articulator (Fig 1.1.2.3).

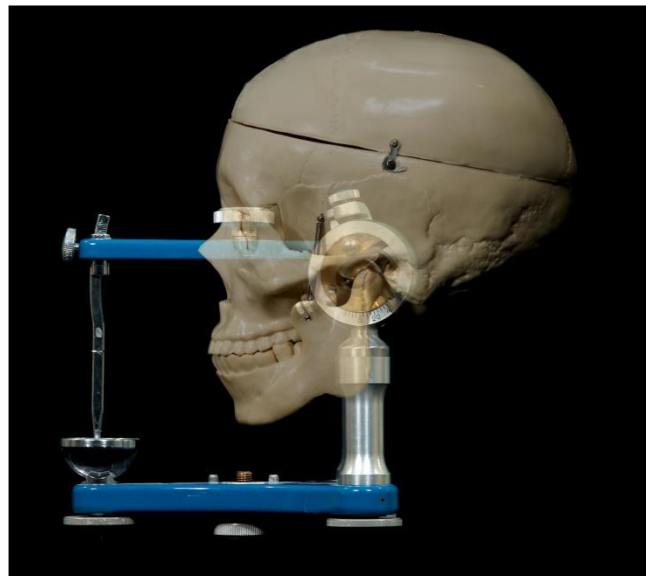

Figure 1.1.2.3 Plane line articulator used for single jaw surgery planning

However, in bi-maxillary (two jaw) surgery or a change in vertical height i.e. maxillary impaction or a downward movement is required, orthognathic model surgery must be carried out on a semi-adjustable articulator with a face-bow registration taken (Fig 1.1.2.4 & 1.1.2.5). The face-bow records and transfers the relationship of the maxilla to the base of the skull from the patient to the articulator (Fig 1.1.2.6).




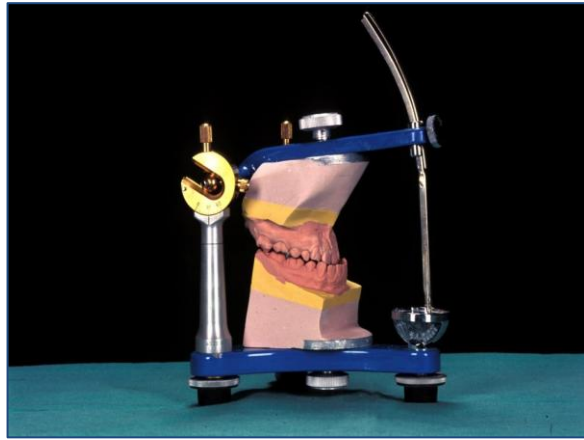
Figure 1.1.2.4 Condylar face-bow with orbital pointer    Figure 1.1.2.5 Semi adjustable articulator



**Figure 1.1.2.6 Skull image superimposed onto the articulator demonstrating the maxilla in relation to the skull transferred to the articulator**

The face-bow registration also records the antero-posterior position of the maxilla in relation to the hinge axis of the mandible. Additionally, a third anatomical point such as orbitale or nasion is recorded to allow the maxillary cast to be mounted on the articulator in a similar anatomical position to that of the maxilla in relation to the base of the skull. The mandibular cast is related to the mounted maxillary cast using a wax registration to record either centric occlusion or the rest position for a class III skeletal deformity. This will enable the dental casts to be moved into their

final postoperative position, simulating what has to be achieved at the time of surgery (Fig 1.1.2.7).



**Figure 1.1.2.7 Mounted casts on a semi-adjustable articulator for bi-maxillary orthognathic surgery planning**

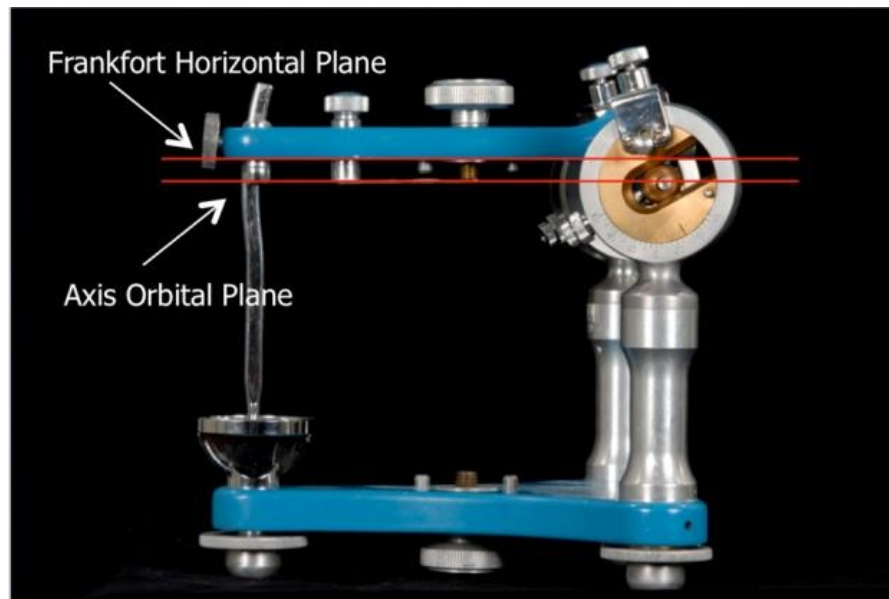
It is important to emphasise that articulator and face-bow systems are mainly designed for prosthetic dentistry and not for orthognathic surgery planning (Sharifi et al., (2008). It is well documented that using dental articulators, according to the manufacturer's instructions for orthognathic surgery planning, introduce concealed and unwanted movements of the dental casts due to the fact that it records the maxillary occlusal plane angle steeper than its accurate anatomical position. These errors are then transferred to the patient during surgery. This problem has been recognised and several studies suggested modifications to reduce this error (Gonzalez and Kingery, 1968; Ellis III et al., 1992; O'Malley et al., 2000; Walker et al., 2008) however these are arbitrary solutions and may not be suitable for all the cases.

## 2.0 Literature Review

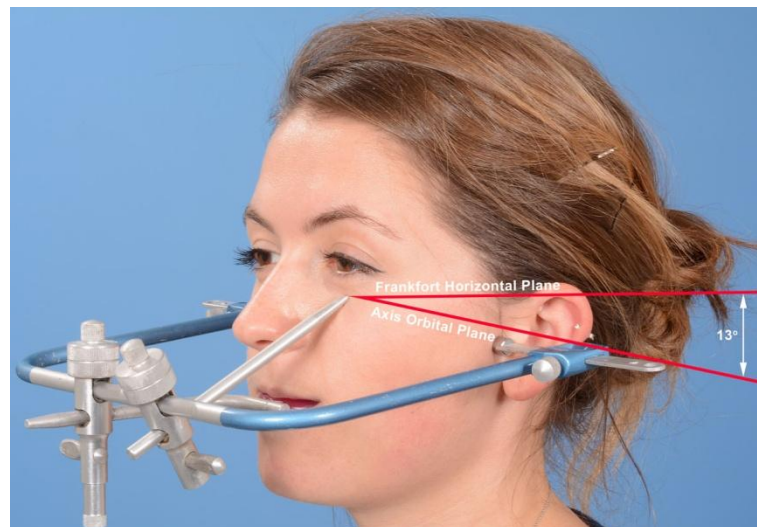### 2.1 Inaccuracies in Model Surgery

The surgical planning for bi-maxillary and Le Fort I osteotomies is traditionally carried out using a semi-adjustable articulator and face-bow for the prediction of the postsurgical dental occlusion. Several studies suggested that there is a varying degree of inaccuracy in recording the maxillary occlusal plane angle when using these instruments (Gonzalez et al., 1968, Ellis III et al., 1992, Pitchford et al., 1991, O'Malley et al., 2000, Walker et al., 2008). The inaccuracies are manifested when transferring the face-bow to the articulator for the mounting of the maxillary dental casts. The difficulty to accurately identify hard tissue landmarks underlying the soft tissue is well documented (Bamber et al., (1996). The semi-adjustable articulator is designed for the top arm of the articulator to represent the Frankfort horizontal plane (FHP) as described by the articulator manufacturers. The orbital guidance plane is attached to the top arm which replicates orbitale. Following the manufacturer's instructions, the face-bow is transferred to the articulator and the condylar rods of the face-bow are attached to the condylar elements of the articulator. The orbital pointer is positioned to contact the underside of the orbital guidance plane, recording the anatomical point of orbitale on the articulator. Anatomically, this represents the axis-orbital plane (AOP). In standard articulators these two planes of reference are parallel (Fig 2.1.1), however clinically these anatomical planes are not parallel with an average angle of 13° apart (Pitchford et

al., 1991) (Fig 2.1.2), this anomaly produces obvious errors when the mounted casts are used in the planning process.



**Figure 2.1.1** Frankfurt horizontal plane and the axis-orbital plane parallel on the articulator




**Figure 2.1.2** 13° angle from the Frankfurt horizontal plane and the axis-orbital plane

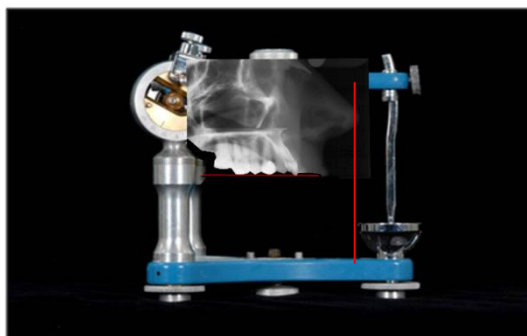
On completion of the prediction planning, acrylic intermediate and final surgical repositioning wafers for bi-maxillary surgery are fabricated. In the case of single jaw




surgery one wafer is required. The purpose of the final wafer is to guide the movement of the osteotomy segments to the pre-planned position. However, the inaccuracies of the face-bow recording impact on the precision of the position of the osteotomy segments during surgery, resulting in additional unwanted anterior movements of the maxilla as a direct result of the errors in mounting dental models on articulators (Fig 2.1.3, 2.1.4, 2.1.5) as reported by Ellis III et al., (1992); O'Malley et al., (2000); Walker et al., (2007). Within the published literature, suggestions have been proposed to reduce the potential introduction of these errors (Gonzalez and Kingery 1968; Ellis III et al., 1992; O'Malley et al., 2000; Walker et al., 2008).



**Figure 2.1.3 Maxillary occlusal plane angle recorded by a face-bow following the manufacturer's instructions**



**Figure 2.1.4 The actual maxillary occlusal plane angle recorded by the lateral cephalogram**



**Figure 2.1.5 Superimposed lateral cephalogram onto mounted models by face-bow**

Gonzalez and Kingery (1968) explored which anatomical planes of reference should be used to transfer the face-bow and maxillary cast to the articulator accurately. The planes of reference studied were the axis-orbital plane and the maxillary occlusal plane in relation to the Frankfort horizontal plane. Twenty-one patients had lateral cephalograms taken and cephalometric tracings completed for each case. On the lateral cephalogram, a line was drawn from porion to left orbitale (Frankfort horizontal plane). The axis-orbital plane was registered with a line drawn from the centre of the condyle to left orbitale and the maxillary occlusal plane was registered with a line taken from the incisal tip of the maxillary central incisor to the lowest cusp of the first maxillary molar.

This allowed the angle of the maxillary occlusal plane and the axis-orbital plane to be measured in relation to the Frankfort horizontal plane for each patient. The angle between the Frankfort horizontal plane and the axis-orbital plane was also evaluated. The mean distance between the Frankfort horizontal plane and the axis-orbital plane was  $7.1^\circ$ . The relationship of the planes on the articulator were

analysed and the height of the condyles and the height of the orbital plane indicator were measured, showing the axis-orbital plane was parallel to the top arm of the articulator which represented the Frankfort horizontal plane.

Lateral cephalometric tracings showed that the axis-orbital plane was indeed not parallel to the Frankfort horizontal plane for all of the twenty-one patients in this study. As a result of paralleling these two planes of reference during mounting the maxillary cast on the articulator using a face-bow, it increased the posterior inclination of the mounted maxillary cast when articulated, recording the maxillary occlusal plane angle too steep.

Gonzalez et al., (1968) suggested the orbital pointer of the face-bow to be placed 7mm below orbitale; this will place the condylar axis point and the Frankfort horizontal plane on the same level. They also recommend that the face-bow should be moved up anteriorly until the orbital pointer is 7mm above the orbital plane indicator. The authors state the second option is their preferred method.

However, the 7mm measurement is arbitrary and to obtain a more accurate method the distance between the two reference plane angles should be measured for each individual patient on the lateral cephalogram. Although this method reduces the maxillary occlusal plane angle to a more accurate representation to that of the patient's actual maxillary occlusal plane angle, it has to be noted that these reference planes may actually be parallel in some patients, therefore by moving the pointer up 7mm would in fact build in an error in prediction planning.

Ellis III et al., (1992) examined the accuracy of face-bow transfer following the manufacturer's instructions and recommended that the maxillary occlusal plane angle recorded by the face-bow should be similar to that of the lateral cephalogram. The Hanau semi-adjustable articulator and face-bow was selected for their study. This particular system recorded three points of reference: the maxillary occlusal plane, external auditory meati and orbitale. Lateral cephalograms were taken for twenty-five patients; the angle between porion, orbitale and the maxillary occlusal plane was the "gold standard" for the maxillary occlusal plane angle. Dental impressions were obtained, the maxillary dental casts were mounted on the articulator using the face-bow system following the manufacturer's instructions and the maxillary occlusal plane angles were recorded. This was achieved by measuring the angle between the top arm of the articulator (F.H.P) and the maxillary occlusal plane. The mean difference between the two recorded angles showed an inaccuracy of 7° recorded by the face-bow. The study highlighted that the maxillary occlusal plane angle was recorded correctly in only two of the twenty-five patients and there was an increased occlusal plane angle when compared to the lateral cephalograms in the remaining twenty-three.

The authors suggested that the face-bow should be taken as recommended by the manufacturer and casts mounted on the articulator. The occlusal plane angle should be compared against the lateral cephalograms and if there are evident inaccuracies then the face-bow should be rotated either upwards or downwards until a similar

angle to that of the lateral cephalogram can be reproduced for the accurate representation of the maxillary occlusal plane angle.

O'Malley et al., (2000) compared the angle of the maxillary occlusal plane when recorded using three semi-adjustable articulator and face-bow systems: Dentatus Type ARL, Denar MkII and the Whipmix Quickmount 8800. The study also assessed the influence of systemic errors in positioning the study casts on the articulators used in orthognathic model surgery planning. This study was carried out on twenty patients, ten class II skeletal relationships and ten class III skeletal relationships. One trained operator completed all three face-bows for each patient, following the manufacturer's instructions. Each face-bow was mounted on the corresponding articulator and the angle of the maxillary occlusal plane was ascertained by measuring the angle of the bite-fork using a Rabone angle setter. Lateral cephalograms were obtained to identify the maxillary occlusal plane angle which was the reference gold standard. The mean maxillary occlusal plane angle was  $14.6^{\circ}$  with a SD of  $8.7^{\circ}$  for the entire patient cohort. Five patients were then randomly selected to assess the errors of the method, the face-bow measurements and cephalometric tracings were repeated after twenty-four hours to test the reproducibility of the two methods.

The results showed that in all three semi-adjustable articulator systems the occlusal plane angle was recorded shallower to the Frankfort horizontal plane when compared to that of the lateral cephalogram. The Whipmix Quickmount articulator system recorded the maxillary occlusal plane angle  $2^{\circ}$  shallower than the

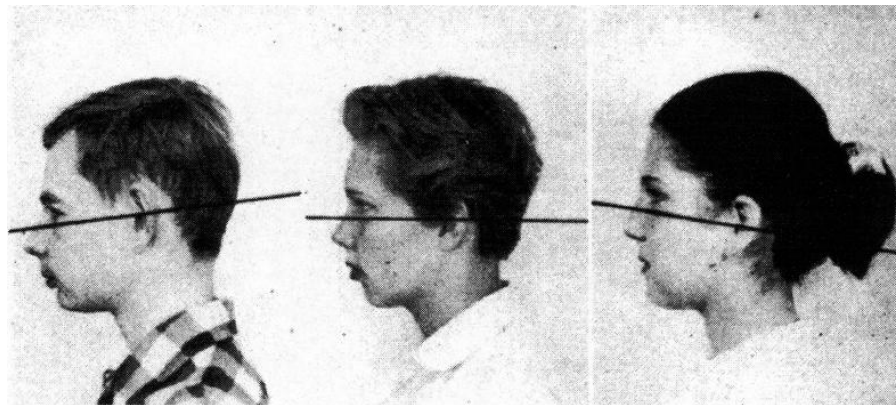cephalometric measurement. The Dentatus recorded the angle  $6.5^{\circ}$  shallower and the Denar recorded the maxillary occlusal plane angle  $5.2^{\circ}$  shallower. This was the only study that reported the maxillary occlusal plane angle to be recorded shallower when analysed against that of the lateral cephalogram.

In summary, it is evident that semi-adjustable face-bow and articulator systems do not record the correct maxillary occlusal plane angle relative to the base of the skull which contributes to the inaccuracy of the physical planning of orthognathic surgery. The previous suggested methods for overcoming these anomalies are arbitrary and would not be accurate for every case. This is due to the fact that for certain patients the Frankfort Plane may be more horizontal and adjusting the face-bow by the suggested 7mm may record the angle of the maxillary occlusal plane inaccurately.

## **2.2 The Role of the Natural Head Position**

Recording the natural head position (NHP) plays a vital role in the analysis and planning of orthognathic surgery. The NHP has been utilised in orthodontics dating back to the late 1950s (Downs 1957) and remains a reliable reference position than that of the Frankfort Horizontal Plane (FHP) for orthognathic surgery planning (Cassi et al., 2016). The FHP, although still widely used, has been shown to be an unreliable plane of reference to use in diagnostic analysis due to the fact that it is not horizontal in all patients as reported by Downs in 1957.

Downs (1957) stated the Frankfort horizontal plane should be level when a person is standing looking straight forward (NHP). Downs conducted a study in which one hundred children were photographed standing in front of a mirror looking into their own eyes (NHP). On the lateral photograph a line was drawn from the superior margin of the auditory meatus (porion) to orbitale recording the Frankfort horizontal plane (Fig 2.2.1). The data was analysed and Downs stated that the FHP can deviate up or down as much as  $10^{\circ}$  from the level position. Therefore, the transfer to the articulator is inaccurate and will position the maxillary cast at an overly steep angle.



**Figure 2.2.1 Frankfort horizontal plane marked on lateral photographs**

A more reliable method is to record the NHP for analysis and orthognathic treatment planning which ensures the patient's head is in a natural position and therefore the true extent of the dental and skeletal discrepancies can be evaluated

and not masked or altered by head posture (Moorrees et al.; (1958). Recording the NHP also plays an important role in patients with significant skeletal asymmetries that would otherwise be impossible to use standard anatomical reference points. Studies have reported that patients can reliably and repeatedly adopt their NHP (Moorrees et al., 1958; Sandham et al., 1988; Walker et al., 2008) ensuring that at each stage of the planning process from clinical evaluation, image acquisition, orthodontic analysis and face-bow recording for orthognathic prediction planning, that the NHP remains consistent throughout. A more reliable method of recording the correct maxillary occlusal plane angle relative to the base of the skull in orthognathic surgery planning must be sought as it is a vital element in producing more accurate model surgery planning.

Walker et al., (2008) aimed to establish an accurate method of recording the NHP and introduced a modified face-bow system, assessing the ability to replicate the position of the maxilla relative to the base of the skull on the articulator. The variability of accurately reproducing the NHP in ten subjects was assessed.

Each subject had two soft tissue landmarks identified, one on the right condylar region and the second on the right side of the tip of the nose. The participants were asked to sit on a backless chair at a distance of two metres facing a full length mirror and stare into their own eyes. This procedure encouraged each subject to adopt their NHP. A lateral photograph captured each subject in their NHP and this process was carried out on three separate occasions at set intervals of no less than one hour apart. On the photograph, a horizontal line was drawn across each image



and a second line joined the markers on the soft tissue. These were linked and the angle created from the two lines was measured using a protractor, with a measurement accuracy of  $0.5^{\circ}$ . Friedman non-parametric test confirmed the accuracy of a single subject reproducing the NHP which was sufficient to ensure accurate mounting of the maxillary cast onto the articulator.

Upon establishing an accurate method of recording the NHP Walker et al., (2008) validated a modified face-bow. Six patients requiring corrective jaw surgery had lateral cephalograms taken and two face-bows recorded. A standard Dentatus face-bow with orbital pointer and a second Dentatus face-bow, which was modified by replacing the orbital pointer with a bubble spirit level, were used for this study. This was used to record the NHP, enabling the maxillary casts to be accurately positioned relative to the base of the skull when the head is in the NHP. Dental casts were obtained and duplicated to allow each cast to be mounted on the articulator using both face-bow methods. A comparative study of the maxillary occlusal plane angles recorded by the two face-bows for each patient was conducted. Cephalometric tracings were used to define the "gold standard" maxillary occlusal plane angle of each patient, and the two maxillary casts mounted on the articulators were measured with the use of an adapted protractor and a flat plane held onto the occlusal surface of the maxillary dentition.

The modified face-bow with the use of a spirit level recorded the maxillary occlusal plane angle within  $1^{\circ}$  of that measured on the lateral cephalogram. The standard Dentatus face-bow with the orbital pointer measured an inaccuracy between  $10.75^{\circ}$

and  $11.5^\circ$  compared to the maxillary occlusal plane angle recorded on the lateral cephalogram. Therefore, the modified face-bow was a more accurate method of recording the maxillary occlusal plane angle for the use of orthognathic surgery planning. Walker et al., (2008) demonstrated that the NHP is reliably reproducible and records the maxillary occlusal plane with greater accuracy and therefore should be considered as one of the reference planes recorded for planning orthognathic surgery.

However the modified face-bow still relies on the accurate location of the condylar heads as a vital reference point, which can be influenced due to the operator's interpretation. More importantly, it cannot accurately record maxillary occlusal canting due to the inability to independently record each condylar height separately. Walker et al., (2008) highlighted that using semi-adjustable articulators systems for planning orthognathic surgery requires a modified approach and although the proposed method does not eradicate the inaccuracies, it does reduce the magnitude of the discrepancies observed.

The existing articulator systems produce errors in recording the correct maxillary occlusal plane angle and therefore transferring these to the patient peroperatively. Modifications to the manufacturer's instructions have been offered to limit the inaccuracies observed. However these are not applicable to every patient and Walker et al., (2008) suggested replacing the orbital pointer with a spirit level to record the NHP. This method can be easily adopted and reduces the amount of

error in mounting the maxillary dental model in the correct inclination. There is a need for a more accurate method to plan orthognathic surgery.

### **2.3 Three-Dimensional Orthognathic Planning**

With the advent of three dimensional technologies, virtual orthognathic surgery planning eliminates the need for articulators and face-bow recordings. This paradigm shift eliminates the inaccurate recording of the maxillary occlusal plane angle when using a face-bow to mount the dental casts onto the articulator and the ambiguity of manually moving the casts in the X, Y and Z direction which is operator sensitive. 3D planning also has the advantage of displaying greater potential for new splint design concepts to allow surgical repositioning of the osteotomy segments.

The 3D planning process is based on the data generated from the Cone Beam CT scan (CBCT) of the skull, allowing the conversion from a Digital Imaging and Communications in Medicine file (DICOM) to a Standard Tessellation Language file (STL) when imported for analysis using 3D software packages. This file conversion enables orthognathic planning to be predicted within the virtual environment using specific orthognathic planning software programmes. STL files are recognised by 3D printers and therefore can be utilised for rapid-prototyping of the 3D surgical wafers on completion of the planning process.

## **2.4 Accuracy of 3D Orthognathic Planning and Rapid Prototyped Wafers**

3D orthognathic surgery planning is still in its relative infancy and the literature suggests that there is a varying degree of accuracy within 3D prediction planning and surgical positioning wafers when compared to conventional orthognathic planning and the standard methods of wafer construction.

Xia et al., (2007) evaluated the accuracy of a 3D surgical planning method for the correction of craniofacial deformities. The CBCT scans of five patients were imported into a 3D software package creating virtual skull models, from which the magnitude of the deformity was measured. 3D planning was performed, firstly by moving the maxilla then the mandibular segment and a genioplasty completed the process. On completion of the planning process, 3D surgical splints were designed and manufactured using stereolithographic technology. In conjunction, conventional planning and acrylic wafers were provided as a surgical alternative if the 3D planning did not favourably position the jaws. Six weeks' postoperative CBCT scans were superimposed using "surface best-fit" with the pre-planning images for measuring and evaluating the accuracy of the planning process. The linear differences between the pre-planned and postoperative outcomes were within 1.99mm, with the largest median distance of 0.85mm. The largest angular difference was 3.48° and the largest median difference was 1.70°. The "surface best-fit" accuracy was 0.12mm with a SD <0.19mm between two of the three landmarks identified.

The authors did not evaluate the accuracy of the replacement of the distorted dentition of the CBCT scan with the scanned dental models. The dentition replacement process may have had a negative impact on the overall accuracy of the prediction planning. Although the study reported an acceptable level of accuracy between the planned and post surgical outcome, a robust evaluation cannot be obtained based on a sample size of six cases.

Tucker et al., (2010) retrospectively validated the ability of accurately predicting orthognathic surgery using CBCT scan data and a 3D software programme (CMF application software). Preoperative and four to six weeks' postoperative CBCT scans of twenty patients were imported into the 3D software programme. Fully automated rigid registration facilitated the superimposition of the two images on the cranial base. The fourteen bi-maxillary and six Le Fort I advancements were retrospectively simulated, compared and validated by one operator. The postoperative 3D scans were used as the guide for validating the virtual surgical movements. The planned and postoperative positions of the jaws were measured and evaluated using selected anatomic areas: condyles, lateral rami, lateral mandibular corpi, anterior corpi, chin, lateral maxillary body and anterior maxillary body.

Students' t test showed that the difference between the eleven pre and postoperative positions were no greater than 0.5mm, meaning these were statistically insignificant.

## 2.5 Replacing the Distorted Dentition

The main disadvantage of 3D prediction planning using CBCT is that the scanners are set to capture the bony skeletal structures of the skull for diagnostic and planning purposes. However, it does not accurately capture the upper and lower dentition due to streak artefacts produced from the metallic restorations and orthodontic brackets (Fig 2.5.1) as well as the magnification of the teeth (O'Neil et al., 2012). This is evident when the DICOM file is converted to a 3D STL file within the planning software. The resulting factor is that the dentition is magnified and rendered inaccurate for the use of prediction planning and surgical wafer manufacturing. Dental amalgam restorations and orthodontic fixed appliances also have a profound negative effect on the quality of the CBCT scan due to streak artefact which distorts the teeth (Swennen et al., 2007; Nairn et al., 2013; Yang et al., 2015). Therefore, the distorted dentition must be replaced with an accurate representation of the dentition within the 3D software.

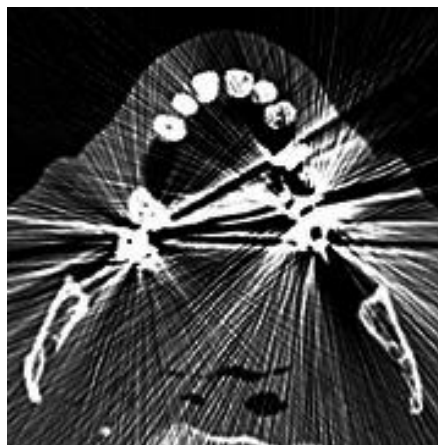
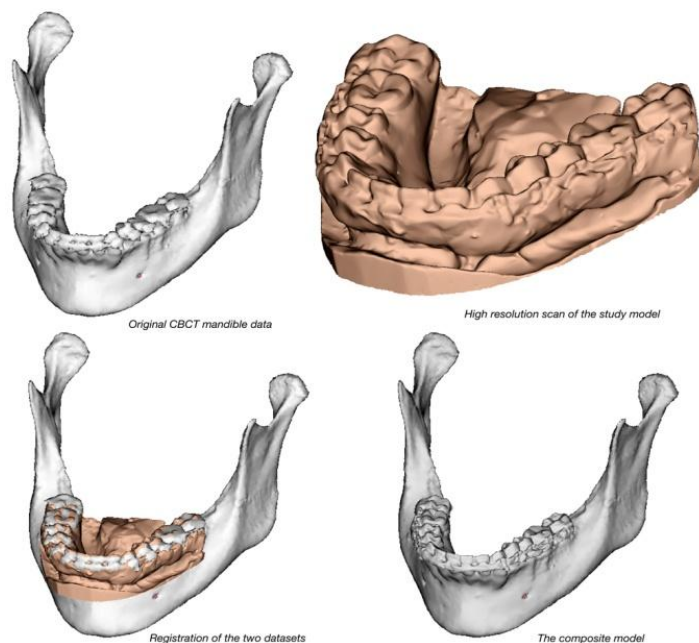


Figure 2.5.1 Streak artefact visible on CT image

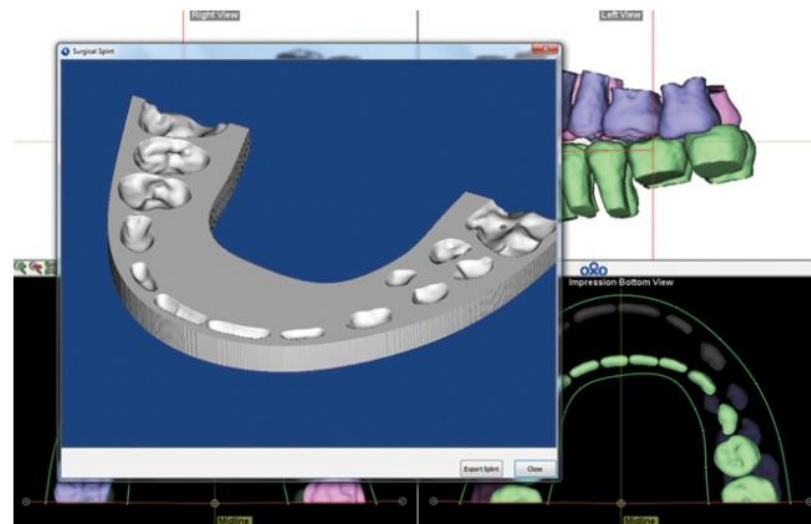
Replacing the inaccurate 3D dentition has been achieved using the laser scanned plaster dentition obtained from dental plaster models, scanning the dental impressions or capturing a 3D image of the upper and lower dentition using an intraoral laser scanner. Dedicated software packages including KLSMartin IPS Case design (Tuttlingen, Germany), Dolphin Imaging 3D Surgery (Chatsworth, CA 91311 U.S.A) and Pro Plan CMF Materialise (Leuven, Belgium) utilise algorithms to replace the distorted dentition captured by the CBCT scan with an accurate representation of the dentition (Fig 2.5.2).



**Figure 2.5.2 Sequence of digital dentition replacement**

This process allows orthognathic prediction planning and surgical splints to be accurately designed within the virtual environment (Fig 2.5.3). The 3D surgical splints are designed and rapid prototyped in sterilisable and bio-compatible light

cure resin material using a 3D printer that allows the splints to be used within the oral cavity.



**Figure 2.5.3 Virtual image of 3D splint design**

With 3D orthognathic prediction planning gaining interest, studies have been undertaken and offer other methods of replacing the inaccurate dentition with accurate virtual dental models of the upper and lower arches. The authors' suggestions would negate the need to rely on the planning software's algorithm for dentition replacement.

Swennen et al; (2007) evaluated the accuracy of utilising a hard splint with fiducial markers positioned along the buccal and lingual aspect of the splint to accurately replace the distorted dentition in the virtual environment. Ten dry human skulls with intact dentition were selected and alginate impressions were obtained for the



upper and lower arches from which dental casts were created. Hard acrylic radio-opaque non-toxic splints with twelve 1.5 mm spherical gutta percha markers were fabricated for each skull, the corresponding splints were positioned on to the dentition of the dry skulls and all ten skulls were CT scanned. Each splint was then used to occlude the corresponding upper and lower dental casts and again CT scanned, both images were imported into a viewing software programme (Maxillim 1.3.; Medicim NV, Sint-Niklass, Belgium). The splint with the fiducial markers allowed automatic rigid registration to fuse the image of the skull with the plaster dentition. The automatic rigid registration was evaluated and the author reported an overall mean registration error of  $0.14 \pm 0.03\text{mm}$ .

Nairn et al., (2013) assessed the accuracy of dentition replacement in CBCT images with the use of intraoral radiopaque hexagonal fiducial markers positioned within upper and lower acrylic plates. The plates were worn by the patients in the CBCT scanner and during intraoral impression taking. The hexagonal markers were used to superimpose the laser scanned images of the dental arches to the CBCT images. The images were imported into VRMesh (Seattle City, WA, USA) and the superimposition accuracy was validated. Nairn et al., (2013) reported that the maxillary dentition was replaced with an accuracy of 0.26mm - 0.71mm and the replacement of the mandibular dentition was within 0.37mm - 1.05mm. Yang et al; (2015) carried out a similar study replacing the dentition on the upper and lower arches using a acrylic palatal and lingual plates with four fiducial markers attached

with an accuracy of  $0.20 \pm 0.03\text{mm}$  for the maxillary dentition and  $0.27 \pm 0.05\text{mm}$  on the mandibular dentition.

Almutairi et al., (2018) evaluated a method of replacing the distorted dentition of the CBCT scans for orthognathic surgery planning. Orthodontic brackets were fixed on to the dentition of six dried skulls then hexagonal fiducial markers were fabricated using dental stone and attached to the brackets at the upper central incisor and on the right and left premolar of the maxilla. CBCT images were captured for each skull and an intraoral laser scanner was used to capture the maxillary dentition in 3D. The two sets of images for each skull were imported into a 3D software programme VRMesh (Seattle City, WA, USA). The skull with the fiducial markers attached to the brackets and the 3D capture of the dentition were manually aligned using the six points on the fiducial markers. Iterative closest point (ICP) was utilised to ensure fine alignment of both images. The dry skulls were additionally scanned using a Faro 3D laser scanner (Scantec, Coventry, UK) to produce a superior image to that of the CBCT scan, this was considered the gold standard and used to validate the study.

The dentition captured using the Faro laser scanner and the intraoral scanner were aligned as previously described and the absolute mean distance between the two images were evaluated. These ranged from 0.13-0.19mm when registered using the fiducial markers and 0.11-0.20mm when registered with the surface of the skull with no statistically significant differences between the measurements.

Although the study reported an accurate method of replacing the distorted dentition utilising fiducial markers attached to the orthodontic brackets, the study was executed on dry skulls in a controlled environment. Adopting this technique in a clinical setting may produce more challenging obstacles such as the ease of attaching and ensuring the hexagonal fiducial markers remain static throughout the image acquisition process. The Faro laser scanner captured a far superior image to that of the CBCT scan and by utilising this image of the skull for validation purposes it may have produced more accurate results than if the CBCT scan had been used. Validating the dentition replacement using the CBCT data would better replicate the clinical environment.

The techniques suggested offer alternative methods in replacing the distorted dentition with an acceptable degree of accuracy as reported when utilising the fiducial marker systems. These systems have been proven to replace the dentition accurately, however technology is ever-advancing and the ability of the 3D software planning will enable the dentition to be replaced without adding a further process as suggested. Comparison studies to evaluate the accuracy of dentition replacement using a fiducial marker system with that of the 3D orthognathic predict the planning software's algorithm used to replace the dentition would be advantageous.

## **2.6 Accuracy of 3D Planning and Rapid Prototyped Surgical Wafers**

3D orthognathic surgery planning is still in its relative infancy and the literature suggests that there is a varying degree of accuracy within 3D prediction planning and surgical positioning wafers when compared to conventional orthognathic planning and the standard methods of wafer construction.

Aboul-Hosn et al., (2012) ascertained the advantages of applying 3D prediction planning and the fabrication of CAD/CAM surgical repositioning splints for the correction of dento-facial deformities. Sixteen patients requiring the correction of varying degrees of dento-facial deformities were selected; fifteen patients required bi-maxillary surgery and the remaining patient was planned for mandibular surgery only.

CT and CBCT preoperative images were captured and the surgical correction was planned using conventional physical model surgery planning. Virtual planning was executed using software programme (Simplant PRO OMS 10.1 Materialise) where the 3D dentition was replaced with laser-scanned images of the plaster dentition utilising surface registration and final manual movements and rotational fine-tuning. Three dimensional rapid prototyped intermediate splint and final positioning splints were designed and manufactured and the second set of splints was constructed manually from acrylic resin based on the conventional planning method.

The 3D and conventional wafers were tried intraoperatively for each patient and measurements of the jaw positions for each wafer were recorded. Reference points were taken on the bone above the osteotomised segment of the maxilla. The space between this immobile segment and the osteotomised segment recorded the antero-posterior and transversal positional measurements for both wafers. Postoperative CT and CBCT scanned images taken three months following surgery were superimposed to measure the degree of surgical movement and compare the final outcome with that of the predicted movements using the 3D software programme.

On comparison of the 3D wafer and conventional wafer for each patient, the findings were categorised into one of three groups: high level concordance differences <1mm in the three planes, moderate concordance, when the difference between the two wafers were <1mm in two planes and low concordance, when the difference between both wafers was <1mm in one or none of the planes. The results showed that nine cases gave almost identical results. In six cases the similarity was described as “moderate” in two out of the three planes measured and the remaining case showed “low” similarity.

Although nine cases displayed almost identical results compared to the planned position, a larger sample size may have showed different results. The three months postoperative scanning may include surgical relapse from the original postoperative position which would camouflage and confuse the analysis (Hoffman et al., 2004).

Hsu et al., (2013) presented a multicentre study which was carried out over a five year period to evaluate the accuracy of 3D surgical planning following a specified protocol. The study was carried out at three centres on a cohort of sixty-five patients requiring bi-maxillary surgery with or without a genioplasty. Clinical evaluations were carried out with the inclusion of a CT scan, clinical photographs, dental casts and a face-bow with a modified bite jig that recorded the NHP. The bite jig recorded the centric occlusion with the addition of fiducial markers which facilitated virtual replacement of the inaccurate dentition of the CT scans with that of the 3D scanned plaster dentition (3shape A/S, Denmark). Each patient was CT scanned with the face-bow in place for the purpose of transferring the maxillary position into the virtual environment. Virtual planning was performed using a 3D software package (Simplant OMS, Materialise) operated by the company's service centre engineers with guidance from the respective surgeon from each centre. 3D rapid prototyped surgical wafers were used to reposition the maxilla and mandible intraoperatively. CT scans were obtained six weeks' post surgery to assess the accuracy of the surgical positioning of the maxilla, mandible and chin. Superimposition of the preoperative and the postoperative images was carried out using a computer graphics programme (3D Max, Autodesk Inc, San Rafael).

The collated data from all three centres reported that the difference between the position and orientation of the planned and postoperative position of the maxilla and mandible were not statistically significant. The position of the maxilla was within an absolute difference of 0.6mm to 1.0mm and the largest orientation

difference was  $1.5^{\circ}$ . It was reported that the achieved postoperative position of the mandible was within 0.6mm-1.1mm and the greatest orientation difference was  $1.8^{\circ}$ .

Shqaidef et al., (2014) reported similar results regarding the magnitude of mandibular deviation when retrospectively comparing conventional surgical wafers (gold standard) with 3D rapid prototyped wafers in ten cases. Pre-planned articulated single jaw osteotomies and conventional wafers were surface laser scanned (NextEngine desktop 3 dimensional laser scanner). Each wafer had three hexagonal markers attached, one anteriorly and two posteriorly. A blank virtual wafer was produced using a scanned image of the conventional wafer with the occlusal indentations filled in using dental wax. Independent upper and lower dental casts were laser scanned and superimposed onto the articulated models using VRMesh (Seattle City, WA, USA) utilising the iterative closest point (ICP) algorithm. The blank virtual wafers were inserted between the dentition and a Boolean subtraction was performed to produce the final wafers. This STL data was utilised to rapid prototype the final 3D wafer. The articulated dental casts were occluded using the printed 3D wafers and then laser scanned. Evaluation of the accuracy of the 3D surgical wafer was determined by superimposition of the articulated casts occluded by the conventional wafer and the articulated casts occluded by the printed 3D wafer. The positioning error ranged from 0.04mm to 1.73mm.

The literature confirmed that utilising 3D software and rapid prototyped surgical wafers is accurate for predicting and carrying out orthognathic surgery. However, inaccuracies still remain within these developing technologies. This can be observed within the process of dentition replacement. The virtual design of the 3D surgical wafer may also introduce unpredictable post surgical results. This is due to the inability of the available software programmes to recognise interdigitation interferences or premature contact of the upper and lower occlusal surfaces of the teeth during the planning stage. A solution to this problem would be to scan the upper and lower plaster dental models in the final occlusion using a surface laser scanner and import the data into the planning software. This will provide an accurate wafer with the dentition in a fully occluded bite, ensuring a more reliable position for the maxilla and mandible during surgery.

## **2.7 Methods of Intraoperative Maxillary Positioning**

Wafers serve as templates for positioning the upper and lower teeth into occlusion intraoperatively. The intermediate wafer in bi-maxillary surgery or a final wafer in Le Fort I osteotomies guides the maxilla into the prescribed antero-posterior position. This is achieved by surgically disarticulating the maxilla from the cranial base. Once the maxilla is mobilised, the respective wafer is used to occlude the maxillary and mandibular dentition in the predetermined antero-posterior position. Intermaxillary fixation is temporarily applied, and then the maxillo-mandibular complex is autorotated to adjust the vertical position. Relying on the mandible to guide the horizontal position of the maxilla into the planned position introduces a



potential source of inaccuracy. This error arises due to the loss of muscle tone of the muscles attached to the mandible in an anaesthetised patient in the supine position. Boucher et al., (1961) suggested that the relaxed mandible can be pushed inadvertently posteriorly by up to 2mm, therefore under advancing the maxilla intraoperatively. This error may not be recognised at the time of surgery peroperatively, producing an unfavourable postoperative result. To avoid this source of error, researchers considered two approaches: navigation guided orthognathic surgery or the fabrication of an anatomic wafer.

## **2.8 Navigation Guided Orthognathic Surgery**

Stereotactic navigational technology has been explored to accurately reposition the maxilla intraoperatively. These systems allow the maxillary position to be tracked and repositioned in real time intraoperatively. The concept of these systems has been compared to global positioning systems (GPS) in motor vehicles. Navigational systems comprise of four components: an infra-red camera, GPS positioning probe or surgical instrument, a satellite (headset) and the CT scan data visualised on the computer screen. A fiducial headset is attached to the patient, usually onto the cranium with the use of bone anchorage or a form of head band/clamp to secure it in position. The role of the headset is to align and register the patient with the on-screen CT data which is linked to the tracking camera and the surgical probe/tool. Global registration is complete when the system registers the accurate position of the three components.

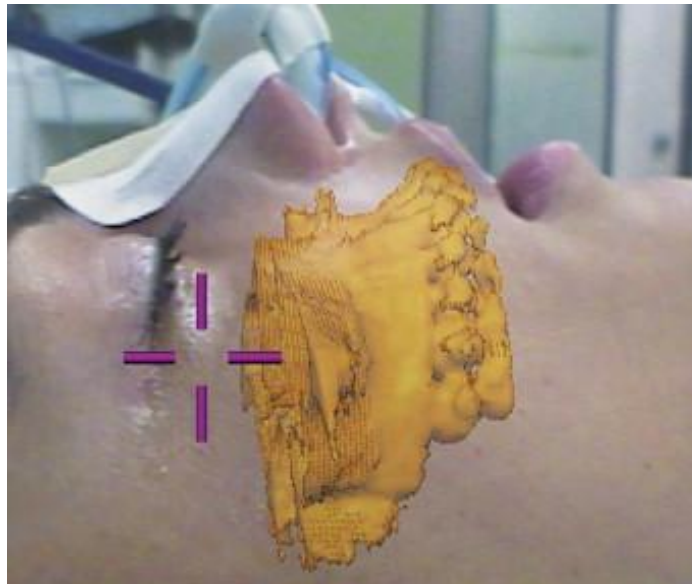
Navigational systems are more commonly used for reconstructive surgery, oncology and craniofacial trauma. There is limited literature on the use of navigational systems for orthognathic surgery.

Zinser et al., (2013) assessed the clinical versatility and accuracy of repositioning the maxilla in sixteen cases utilising surgical navigation combined with an interactive image guided visualisation display (IGVD). Clinical assessments, cephalometric analysis and preoperative CT data recorded the magnitude of skeletal positional discrepancies within this cohort of patients.

Virtual orthognathic surgery planning was completed without the replacement of the inaccurate dentition using a software programme (I-plan CMF, BrainLab). The method allowed the transfer of the virtual planned movements of the maxilla to the operating theatre. In theatre, image to patient referencing was registered using a navigational unit (BrainLab, Vector Vision) with the use of a Mayfield clamp in six cases and a skull mounted referencing star for the remaining nine cases. An IGVD was linked to the navigation system superimposing the virtually planned maxillary position with that of the real time surgical position (Fig 2.8.1) and provided the surgeon with an enhanced perspective of the maxillary position in real time intraoperatively. Each maxilla was repositioned according to the pre-planned location using the fore mentioned navigational system and fixed using two L shaped micro plates. Six months postoperative CT scans and the virtual planned position of the maxillas were compared and evaluated. The positioning of the maxillary occlusal

plane angle was within  $0.41^{\circ}$  and the greatest linear error was observed in the vertical dimension recording a difference which was within 0.67mm.

Although navigational guided surgery appears to produce acceptable results, the authors reported that surgical time increased by sixty minutes when adopting this technique sensitive method. It was also reported that during surgery they experienced two technical breakdowns as a result of the Mayfield clamp moving due to applied forces when the maxilla was down-fractured. It resulted in the entire registering process to be repeated, further increasing the surgical time.



**Figure 2.8.1 Superimposed maxilla using the IGVD**

## **2.9 Anatomically Repositioning the Maxilla**

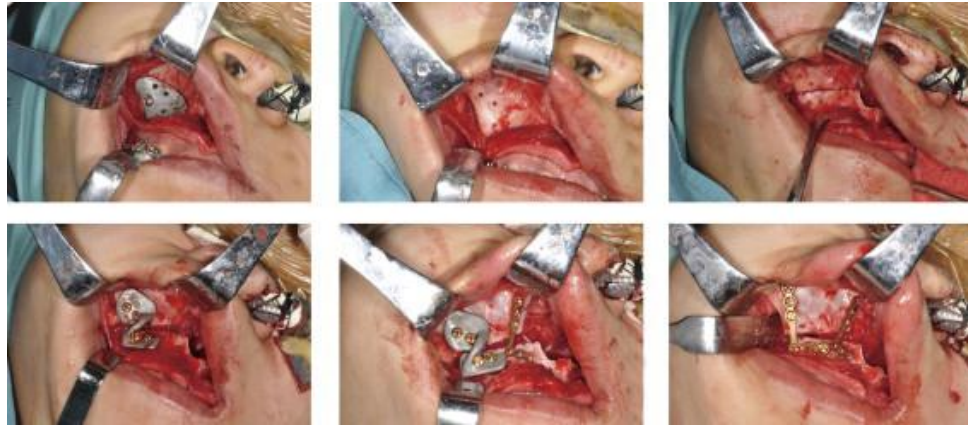
Advances in 3D technology for prediction planning have enabled the introduction of computer-aided design and computer-aided manufacturing (CAD/CAM) software to be utilised for correctly positioning the maxilla without mandibular guidance. CAD/CAM engineering allows the operator to design and 3D manufacture surgical cutting and anatomical repositioning guides in sterilisable and biocompatible material for use in theatre, negating the requirement for surgical occlusal wafers and eradicating their previously described weaknesses.

## **2.10 Custom Made Titanium Bone Plates**

Bai et al., (2010) published a case study introducing an alternative technique of intraoperatively repositioning the maxilla in the correction of a dento-facial deformity using surface templates without the use of a conventional intermediate occlusal wafer.

The patient's CT data was transferred into a 3D software package (Mimics Materialise, Belgium) for 3D prediction planning. The patient required bi-maxillary orthognathic surgery, however only the maxillary movement was planned using the 3D software. The mandibular surgical movement was planned on a conventional articulator and acrylic final occlusal wafer made. On completion of the planned maxillary movements, the 3D data was imported into a CAD/CAM software package (Geomagic Studio) to allow the design and fabrication of pre and postoperative surface templates. The preoperative templates acted as a drilling and location guide

for the bone screws and the postoperative surface templates were used to guide the maxilla into the desired final position (Fig 2.10.1).



**Figure 2.10.1** Drilling guide and surface template in situ

The design of the postoperative surface templates would not have allowed the removal of the plates intraoperatively during the process for achieving the optimal maxillary position. The plates and screws would need to be inserted and removed several times until the surgeon is satisfied that the maxilla is sitting passive with the surface templates. This process would increase operating time and has the potential to cause bony damage and widening of the screw holes, introducing an inaccuracy in maxillary repositioning.

Gander et al., (2015) introduce a novel technique in repositioning the maxilla using patient-specific implants (PSIs) and an osteotomy/drill guide. The study was carried out on one case which was planned for a two part Le Fort I osteotomy. CBCT data was utilised for planning the surgery in a virtual environment (iplan 3.0.5). During planning the inaccurate dentition was not replaced as it was deemed of little

significance due to the presence of hypodontia. The maxilla was repositioned in relation to the base of the skull and the mandible. On completion of the maxillary movement, a virtual drill/osteotomy guide and PSIs were designed using CAD/CAM software (Cati 3D software, France). The thickness of the PSIs was 0.6mm and encompassed the alveolar zygomatic buttress and the anterior nasal aperture bilaterally. The PSIs were processed by laser sintering and the drill guide was manufactured in polyamide (KLS MARTIN, Germany). The drill/osteotomy guide provided the desired location for the screw holes and cutting plane for the Le Fort I procedure. The PSIs located and fixed the maxilla in the pre-planned position. Superimposition of the 3D prediction plan and postoperative scans reported minimal discrepancies. Therefore, it was concluded that by adopting the use of drill/osteotomy guides and PSI the need for occlusal splints was eliminated and the rapid and reliable repositioning of the maxilla was ensured. However the study was a subjective evaluation and limited to one case, which is inadequate to draw a robust conclusion.

Brunso et al., (2016) introduced and assessed the accuracy of a virtual orthognathic positioning system (OPS) consisting of bone-supported positioning guides and custom made titanium mini-plates. The study was carried out on six patients for the correction of Class II or III skeletal deformities. Each patient underwent a non contrast helical CT scan, dental impressions were taken and the dental models were scanned (Lava Scan St scanner). Both digital images were imported into a 3D software package (Simplant Pro OMS), for replacing the inaccurate dentition using a

best-match algorithm feature within the software programme. Virtual osteotomies were carried out on the maxilla and mandible with the surgical cut lines and pre-determined screw holes defined on each of the virtual skulls. Upon the completion, the pre and planned virtual images of each patient were imported into a CAD/CAM software package (PowerShape, Birmingham, UK) for designing the drill guide to facilitate the bone cut and custom plates for maxillary fixation. The custom plates were machined from grade 5 titanium (Createch Medical, Spain) and the anatomically shaped bone-supported drill guides were rapid prototyped from bio-compatible resin. Mandibular drill guides and custom made titanium plates were also provided.

One month post surgery, a helical CT scan was recorded for each patient. These were utilised to measure the accuracy of the surgical outcomes of the virtual planning. This was achieved by selecting anatomical markers on the cranium and superimposing the pre and postoperative images using iterative closest point (ICP) surface matching. The discrepancies were illustrated using a colour-grade scale.

The authors reported that greater accuracy was noted in smaller advancements of <6mm of the maxilla with a SD of 0.14mm (92% within 1mm) and a SD of 0.34mm (86% within 1mm) recorded for the mandible. In advancements >10mm greater inaccuracies were reported with an SD of 1.3mm, in 66% of the cases the maxilla was within 1mm. In the mandible SD of 0.67mm, in 73% of the cases the mandible was within 1mm.

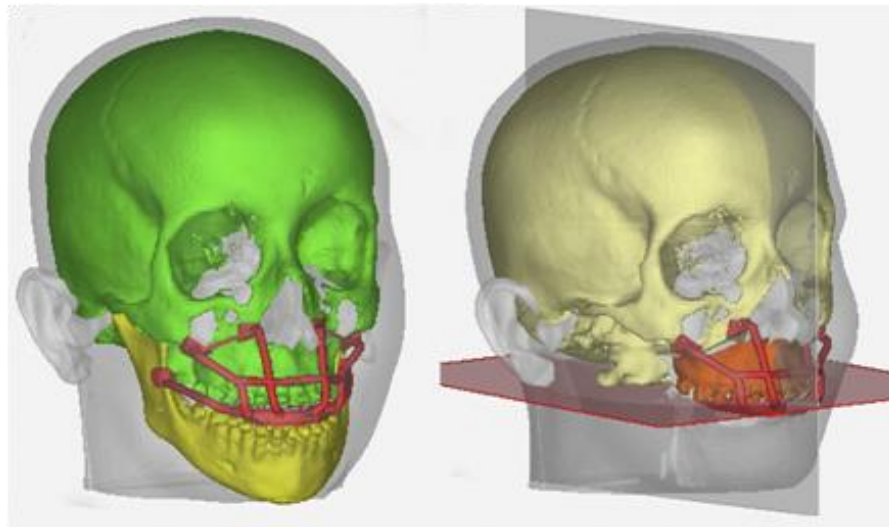
The custom bone plates that guided and fixed the maxilla into the final position had to be positioned and removed several times intraoperatively to ensure the maxilla was positioned favourably. This repetitive process is time consuming and again could cause bony damage at the site of the screw holes. It is essential the screw holes remain viable as their main function is to secure the maxilla in the final position. A larger sample size is essential to reach to a robust conclusion regarding the accuracy of the proposed method.

## **2.11 Custom Made Anatomical Repositioning Splints**

As technology becomes increasingly popular and affordable, there has been an increase in reporting of new and novel techniques for anatomically repositioning the maxilla without the guidance of the mobile mandible. These techniques rely on a combination of virtual osteotomy planning and CAD/CAM software to design the repositioning splints and rapid prototyping technology to manufacture the splints.

Zinser et al., (2012) validated a technique of 3D virtual orthognathic surgery planning and patented 3D anatomical repositioning surgical splints. The study was carried out on eight adults requiring bi-maxillary osteotomies. Surgical planning was performed using Simplant software (Simplant pro crystal, Materialise Dental, Leuven, Belgium). The final predictions plans were imported into a CAD/CAM software programme for the design and production of three anatomical repositioning surgical splints for each patient to facilitate the correction of the dento-facial deformity (Fig 2.11.1).





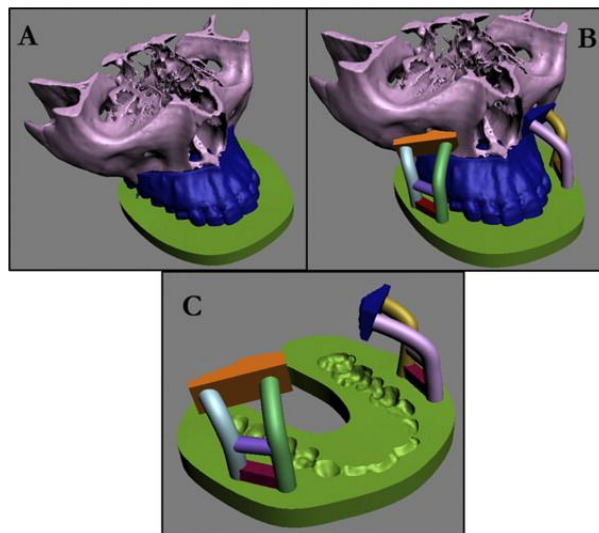
**Figure 2.11.1 Virtual design of anatomical repositioning splint**

Superimposition of the preoperative and postoperative CT and CBCT scans enabled the 3D planned position of both the hard and soft tissues to be evaluated.

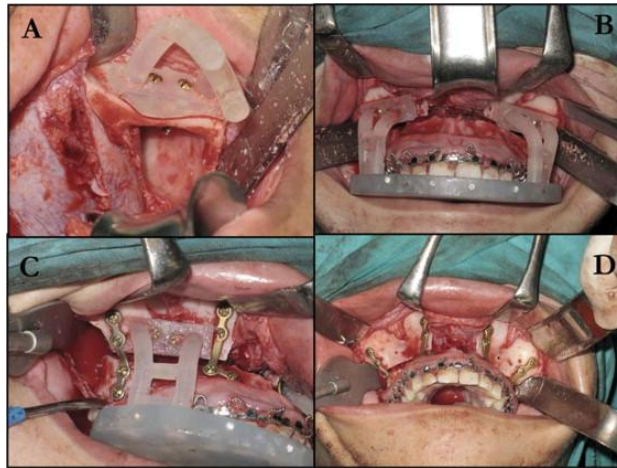
The proposed method of 3D orthognathic surgery planning and three CAD/CAM surgical splint design achieved an accuracy within 0.23 mm in the maxillary position, 0.33 mm in the mandibular position, 0.19 mm in the condylar positions and 2.52mm in soft tissue prediction.

The proposed three-stage splint design and surgical process would appear to be time consuming due to three separate splints being designed and printed: two splints for the maxilla and one splint for the mandible. The position of the vertical struts within the framework would restrict access to the underlying bony regions for the purpose of fixation with bones plates and screws.

Shehab et al., (2013) evaluated the capabilities of a novel tooth/bone supported virtual orthognathic splint in repositioning the maxilla in the X, Y and Z direction without the guidance of the mandible. Six patients requiring the correction of vertical maxillary excess alone or combined mandibular retrognathism were selected. Presurgical imaging was captured, the data from the multi-slice CT scans of each patient was used to plan the orthognathic surgery using 3D software package (Voxim, IVS Solutions, Germany). The occlusal maxillary repositioning splint was designed using a second 3D software programme (3 days Max 2009, Autodesk Inc), and comprised of a 3D occlusal wafer with bi-lateral detachable locating plates (Fig 2.11.2). Vertical struts rested on the anterior wall of the nose and the body of the zygoma and were held in place using two bone screws for each locating plate (Fig 2.11.3).



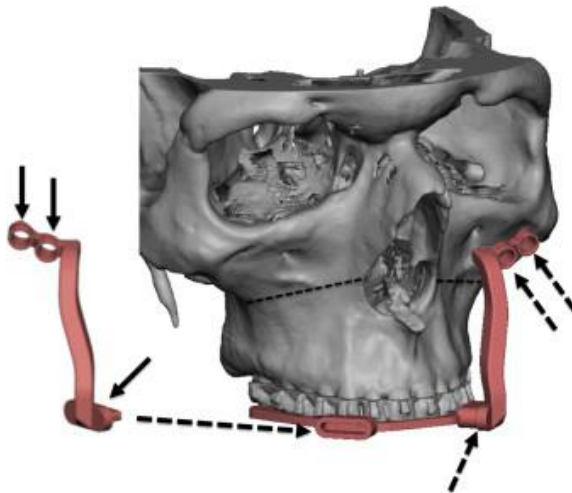
**Figure 2.11.2 Virtual wafer with detachable locating plates**



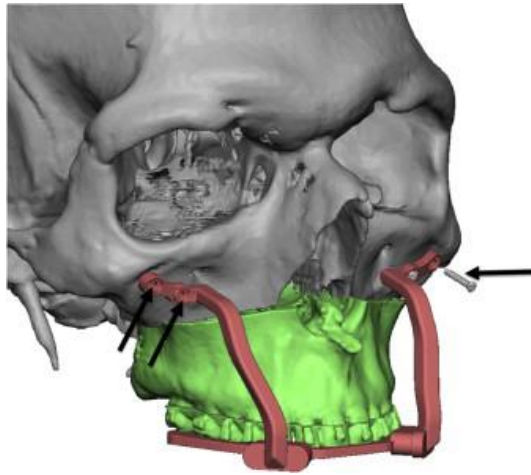
**Figure 2.11.3 3D wafer positioned intraoperatively**

This structure was designed to guide the mobile maxilla into the new pre-planned position. Postoperative lateral cephalograms were obtained within a six-month period. The authors compared the pre and postoperative lateral cephalograms for all six patients and each measurement was carried out by two observers to assess the errors of the method which were not statistically significant. The difference between the pre-planned and surgical vertical movements in five of the six patients was equal to or less than 1mm and in one case it was 1.2mm. The horizontal movements in four of the six cases were 1mm or less. The overall design of the surgical wafer and the supporting struts appeared substantial in dimensions which may be problematic in clinical use as it will restrict the surgical access.

Polley et al., (2013) presented a case study and introduced a new concept of anatomically-positioned orthognathic surgery splints for the guidance of the maxilla, mandible and chin during the surgical correction of dento-facial deformities. Orthognathic surgery planning was performed using 3D software and a CAD/CAM technology company (Medical Modeling, Golden, CO) to produce rapid prototyped surgical repositioning splints. The maxillary repositioning device consisted of a surgical occlusal splint with two sets of removable right and left lateral arm attachments (Fig 2.11.4). The first set of arms were attached to splint prior to maxillary disarticulation and served as a drill guide. The second set of arms guided the maxilla into the planned position (Fig 2.11.5).



**Figure 2.11.4 Drill Guides attached to the occlusal wafer**

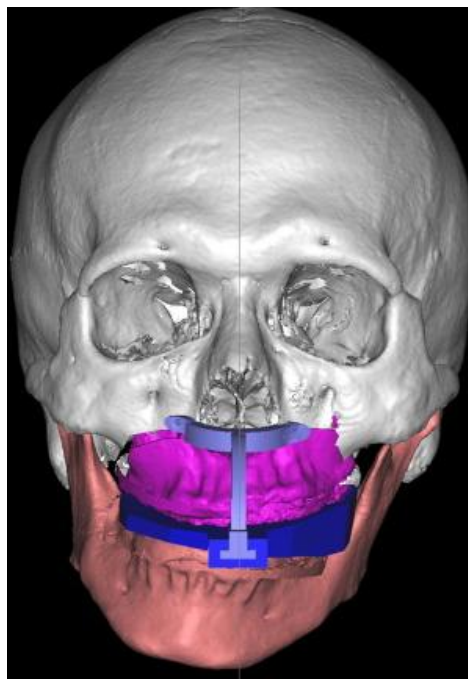


**Figure 2.11.5 Maxillary positioning arms**

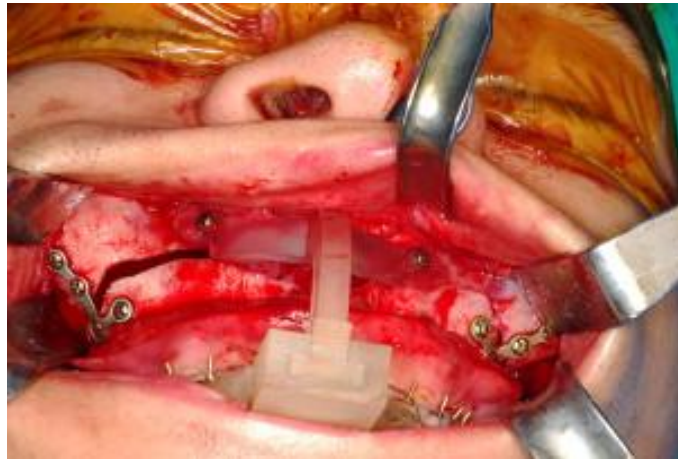
The proposed concept demonstrated a potential solution in the quest for the surgical repositioning the maxilla irrespective of the mandible. However the authors did not evaluate the accuracy of this method.

Kang et al., (2014) introduced a Y-splint wafer assembly for repositioning the maxilla during orthognathic surgery, without the guidance of the mandible to achieve the correct vertical height and antero-posterior position. The CT scan data was imported into a 3D software package (Mimics, Materialise Co) creating a 3D image of the skull and mandible. The inaccurate dentition was replaced by importing the scanned data of the patient's plaster dental models. A second set of plaster dental models (in the planned final occlusion) was imported into the virtual environment. These would determine the final occlusion and mandibular position. The Le Fort I osteotomy was simulated using 3-Matic (Materialise) software, according to the treatment plan. The occlusal surgical wafer was designed using the classic horseshoe shape in 3D and the connecting Y-shaped bar was designed using

CAD/CAM engineering (Fig 2.11.6). The two components were interlinked with a T-bar male and female connector, allowing the wafer and Y-bar to be separated from each other intraoperatively. The Y-bar's function was to secure the mobile maxilla with the use of a single bone screw on either side of the piriform aperture (Fig 2.11.7). On completion of the Le Fort I osteotomy, mini plates and screws were used as standard to fixate the maxilla in the new final position and the occlusal wafer and Y-bar were removed.



**Figure 2.11.6 CAD/CAM designed Y splint**



**Figure 2.11.7 Printed Y splint in situ**

Pre and postoperative CT scans were taken and the surgical movement was compared to that of the virtual 3D osteotomy plan. The sample size was small  $n=1$  and no results were provided, therefore a robust evaluation of the proposed method could not be reported.

Ying et al., (2015) presented a similar design and investigated its efficacy on fourteen patients requiring bi-maxillary surgery. For each case a sequence of radiographs were taken which included panoramic, posterior-anterior, lateral radiographs and CBCT scans. Mimics software (Materialise, Belgium) was used for the surgical planning. The initial planning stage included the CAD/CAM designed and rapid prototyped occlusal wafer with “bridge” attachments which engaged on to two locators on each zygomatic buttress (Fig 2.11.8). This three-part design determined the start position of the maxilla prior to surgery and provided a reproducible position for the locators. The virtual orthognathic predictions were finalised as planned for each patient and a second set of “bridge” attachments were

designed and rapid prototyped. These attachments guided the maxilla into the planned position (Fig 2.11.9). A standard rapid prototyped wafer was fabricated and used to guide the mandible into the postoperative position.

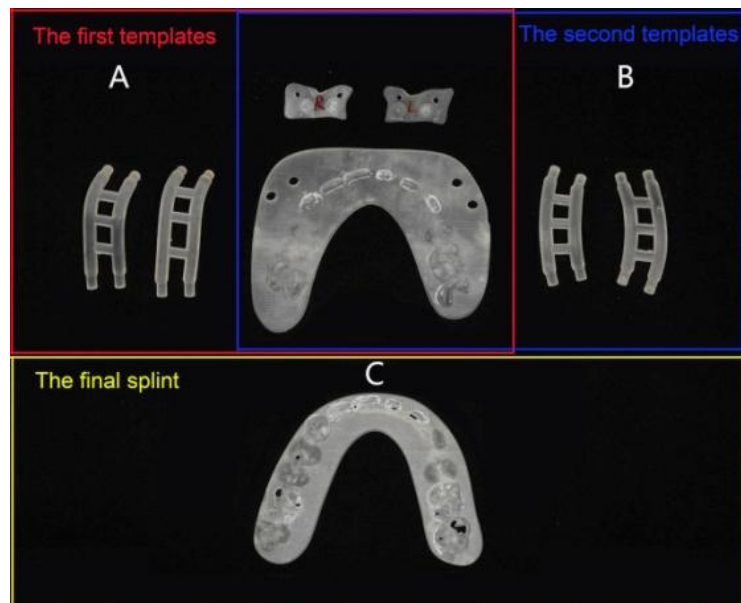


Figure 2.11.8 Sectional splint design

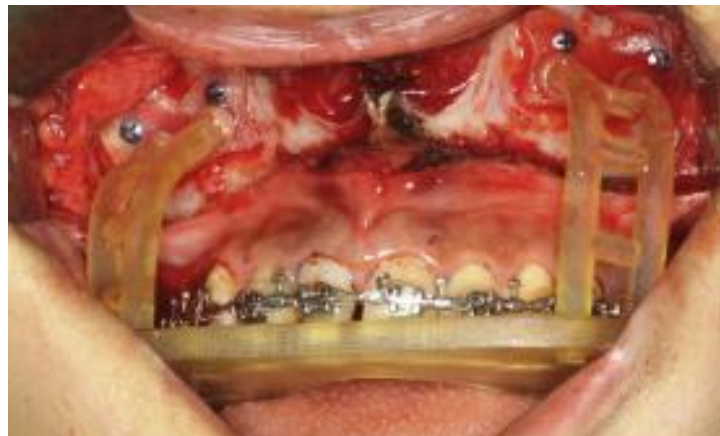

Figure 2.11.9 Post-op splint in situ

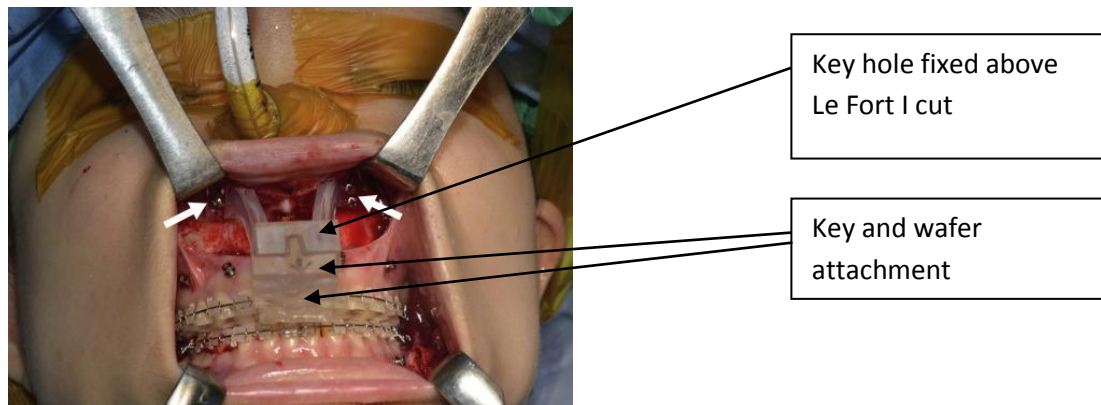
Radiographs were repeated at seven days, six months and one year postoperatively for all fourteen patients. The CBCT scans were analysed to assess the correction of asymmetry and magnitude of postoperative relapse. The analysis of the data



captured at seven days and at one year postoperative demonstrated no statistically significant differences between the maxillary height, ramal height, mandibular height and chin height in all fourteen patients. Although postoperative relapse was not statistically significant no evaluation was carried out to assess the accuracy of the maxillary guide in positioning the maxilla in the planned position.

Lee et al., (2015) introduced a new concept of repositioning the maxillo-mandibular complex in orthognathic surgery using a key and keyhole CAD/CAM device, eliminating the need for a conventional occlusal wafer. This was tested on one case planned for the correction of mandibular prognathism and the associated facial asymmetry. Dental impressions of the upper and lower arches were taken and the produced stone models were scanned using a light-emission diode scanner (Identica Standard, Korea). The casts were articulated in the presurgical position and an acrylic wafer constructed in full occlusal contact. A CBCT scan was captured with the occlusal wafer in place and the data was imported into Simplant (Materialise Medical Software, Leuven, Belgium) from which the virtual surgical plan and CAD/CAM design of the keyhole system was performed. The keyhole system consisted of a block 3cm x 4cm in diameter with an embossed cross which locked into the anterior aspect of the wafer (key). The second element of the design consisted of an arm which was fixated at the piriform aperture using bone screws and extended downwards to locate onto the key by means of interlocking (keyhole). During the virtual planning stage, the “key” remained static as the extension arm dictated the final maxillary position. The maxilla was deemed to be in the correct

pre-planned position when the key and keyhole interlocked without interference (Fig 2.11.10). After the removal of the key and keyhole device, the maxilla was fixed using four mini-plates and screws in the zygomatic buttress and in the area of the piriform aperture. The key and arm attachment were removed from the wafer and then used as a final wafer to guide the mandible into position.



**Figure 2.11.10 Key and Keyhole Interlocked**

The design of the proposed method appears to be a reasonable option for accurately placing the maxilla in the final position intraoperatively, unfortunately the authors did not evaluate the accuracy of the proposed concept and did not evaluate this method.

## **2.12 Summary**

The literature demonstrated that the maxilla can be surgically repositioned using CAD/CAM and 3D rapid prototyped designed repositioning devices. Although there is little robust evidence regarding the accuracy of the proposed concepts, this highlighted the need for technological advancements within this area for

orthognathic surgery to provide a greater accuracy in the surgical planning. The simplicity in applying a guiding device peroperatively is essential. Therefore, it is important that the anatomical guide should be easy to apply, does not restrict the surgical site and should not complicate the surgical procedure, but robust enough to hold the osteotomy segment during surgical repositioning.

## 3.0 Material and Methods

### 3.1 Aim of Study

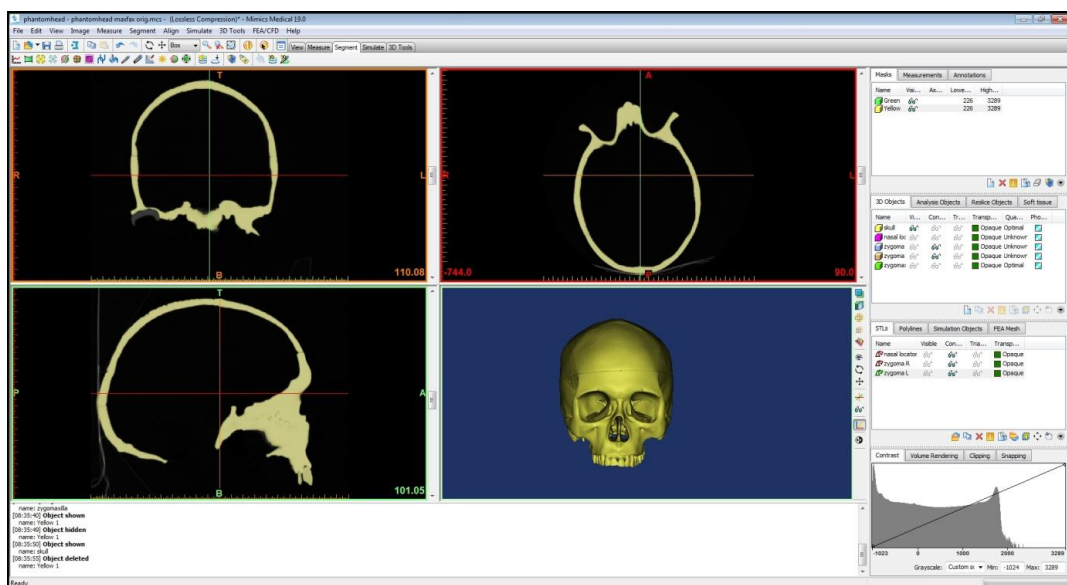
This study was carried out to evaluate if an accuracy of 0.5mm could be achieved using a novel method to guide the surgical repositioning of the maxilla at a Le Fort I level independent of the mandible with the aid of a custom made repositioning guide. The null hypothesis was that the accuracy of repositioning the maxilla using the newly developed guide is within 0.5mm in all directions.

### 3.2 Study Design

A single plastic anatomical skull without the mandible was scanned using a Philips Brilliance 64 helical Computed Tomography (CT) scanner to obtain Digital Imaging and Communications in Medicine (DICOM) data. The CT scanner was readily available within the hospital which contributed to its selection in this study. The skull could have been scanned using a laser scanner, however that was not available at the commencement of this study. This study was performed on a plastic skull

therefore there was no requirement for the dentition to be replaced as there was no streak artefact or dental magnification secondary to the CT scanning.

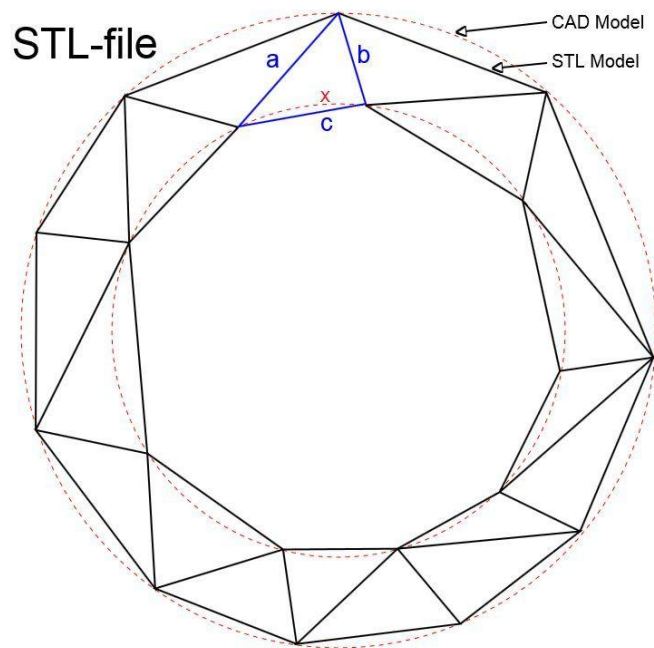
The DICOM data of the plastic skull was imported into a 3D software package Mimics Innovation suite 19.0 (Materialise Medical Software, Leuven, Belgium), to create a virtual 3D image of the skull (Fig 3.2.1).



**Figure 3.2.1 DICOM data imported into Mimics software programme**

Utilising the Mimics software programme, the DICOM data was converted into Standard Tessellation Language file format (STL file). STL files are created from a series of triangles forming a mesh of the 3D object (Fig 3.2.2). The conversion from DICOM to STL file will enable the 3D data to be manipulated in a computer-aided design (CAD) software programme for rapid prototyping 3D physical models or custom made medical devices using a 3D printer.

The threshold value selected for the DICOM conversion was a predefined threshold set (Bone CT) ranging between 226-3071 within the software programme. This provided optimum 3D image quality as can be observed in image (3.2.1). Custom threshold values were also explored however; there was no improvement to the quality of the 3D image.



**Figure 3.2.2 STL File showing formation of triangles creating a mesh of a 3D object**

The virtual image of the skull was initially orientated on the screen utilising the shared coordinate system of the CT scanner. The skull was then orientated to replicate the NHP using the repositioning functions within the Mimics manipulation software. The maxilla was separated from the cranial base of the skull using the “Cut Orthogonal to screen” tool within the Mimics software programme. This

segmentation process allowed the maxilla to be repositioned in the axis independent of the skull (Fig 3.2.3).

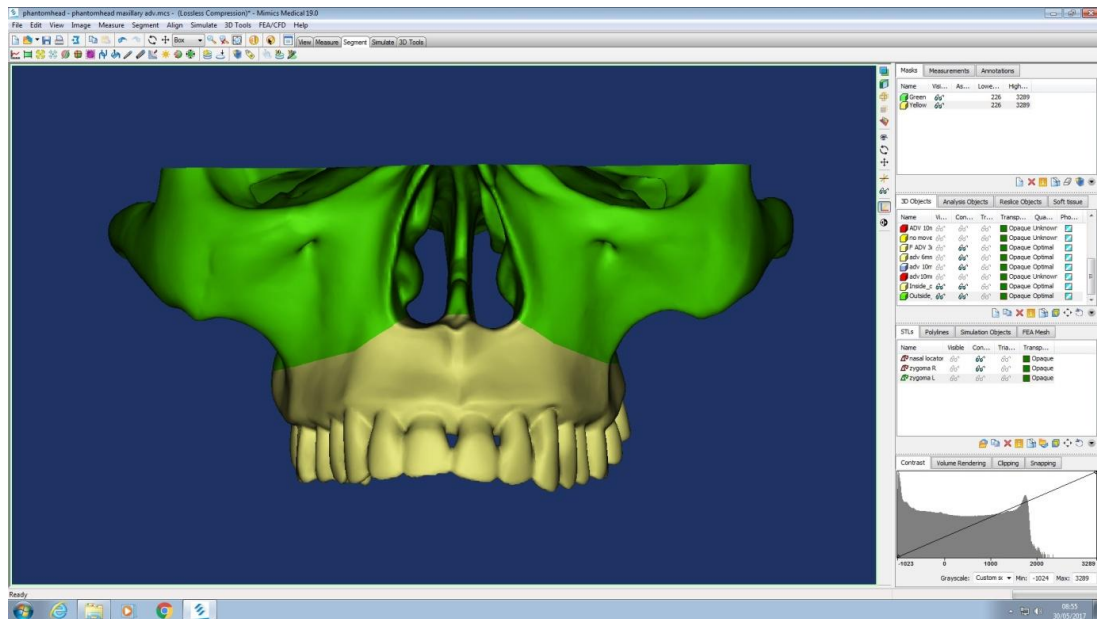


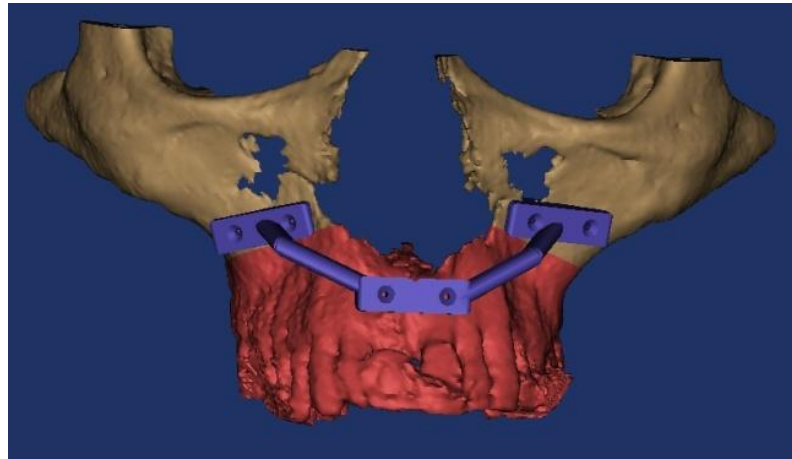
Figure 3.2.3 Maxilla separated from the middle third of the skull

## 3.3 The Progress in Developing the Ideal Design of the Anatomical Guide

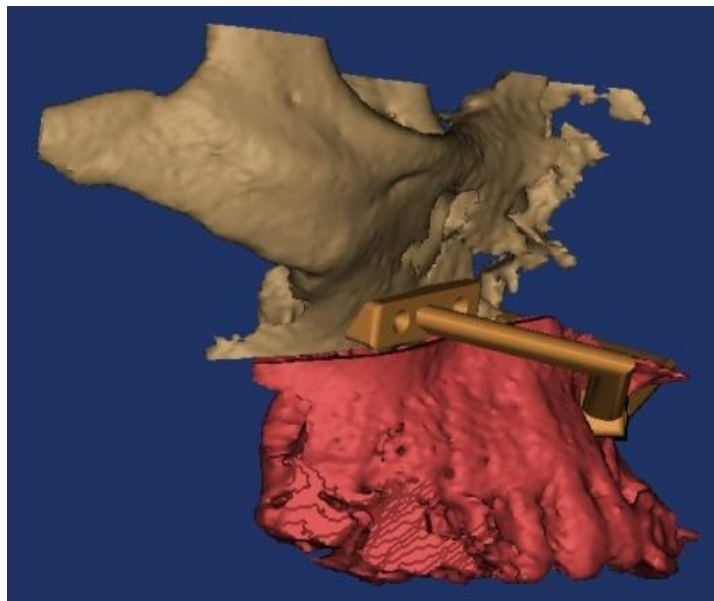
### 3.3.1 Design One

A single unit framework was explored. This initial concept comprised of three fixed anatomical locating plates measuring 20mm x 6mm that were joined with two rigid oval shaped struts with a diameter of 4mm x 5mm. Two guides were designed and printed. The first guide served as a drill guide (Fig 3.3.1.1) for the placement of retention holes in the bone that provide the correct placement of the final maxillary positioning guide (Fig 3.3.1.2). Once the screw holes had been drilled into the bone, the guide was removed and the Le Fort I osteotomy cut was performed. The maxilla

was mobilised and the final positioning guide was fixed in position using six titanium bones screws. The maxilla would be deemed to be in the correct final position when all three plates are passively seated against the bony anatomy.



**Figure 3.3.1.1 Frontal image showing preoperative (drill guide) anatomical guide in situ**



**Figure 3.3.1.2 Lateral view showing postoperative design of the anatomical guide in situ**

During routine orthognathic surgery, repeated trimming of the bone is required to ensure optimal positioning of the maxilla is achieved. It appeared that the design

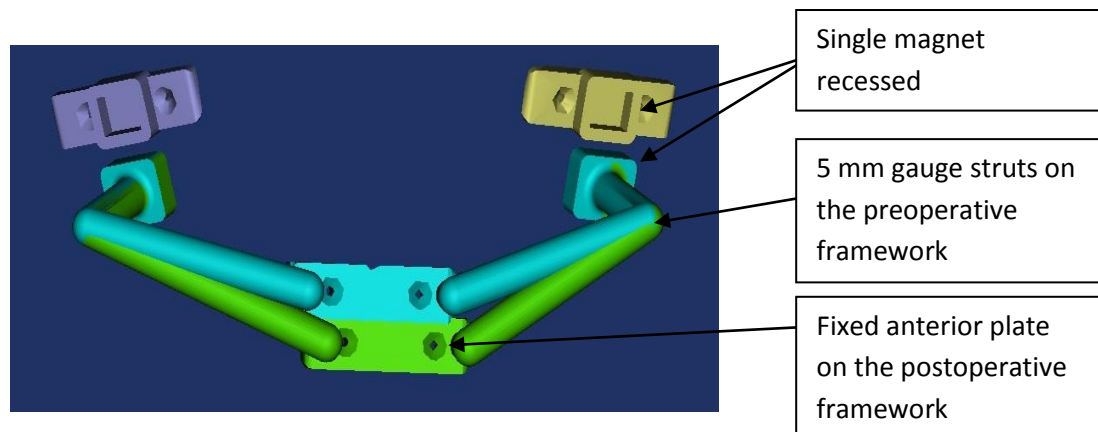
would not allow for the guide to be easily removed and replaced several times without causing damage to the screw holes which will impact on the accuracy and precision of applying the guide. The size and placement of the locating plates restricted the access for securing the maxilla in its new position with the use of titanium bone plates. The struts on the framework also displayed unacceptable posterior movement of the maxilla. It was concluded that the angle and projection of the struts emerging from the locating plates increased the unwanted posterior movement due to design flexibility.

### **3.3.2 Design Two**

Modifications to the initial design concept incorporated the development of independent zygoma locating plates with two removable frameworks designed in the preoperative and post surgical positions (Fig 3.3.2.1). The anterior locating plate remained rigidly connected to the redesigned larger gauge struts that measured 6mm in diameter to eliminate unwanted posterior movement of the maxilla. Magnetic retention (5 x 4 x 1.5 mm neodymium 0.5kg pull magnets) was selected to position and retain both frameworks to the anatomically fixed locating plates. One magnet was positioned and recessed within each locating plate and one magnet in each of the corresponding plates within the framework. The rationale behind this design was the fact that the magnets would allow the framework to be placed and removed during surgery without having to remove the locating plates and produce bone damage due to the repeated application around the zygomatico-maxillary area. This design was advantageous; it facilitates ease of removal of the framework



independent of the locating plates however the magnetic join introduced an area of weakness. It was evident that when a downward pushing force was applied to the guide, the framework and maxilla could be displaced vertically and posteriorly. This would manifest in an unwanted movement and potentially inaccurate final position of the maxilla if this was unnoticed during the surgical procedure. As a result, it was not possible to ascertain whether the larger gauge struts would reduce the amount of posterior movement of the maxilla or if the limited number of magnets reduced the forces of retention.



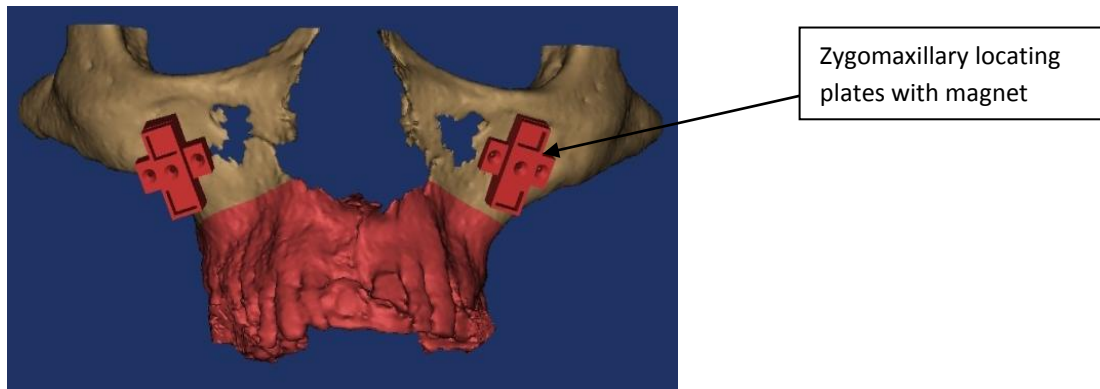
**Figure 3.3.2.1 Second design of anatomical repositioning guide with independent zygoma plates and magnetic recesses incorporated demonstrating the pre and postoperative positions**

### **3.3.3 Final Design**

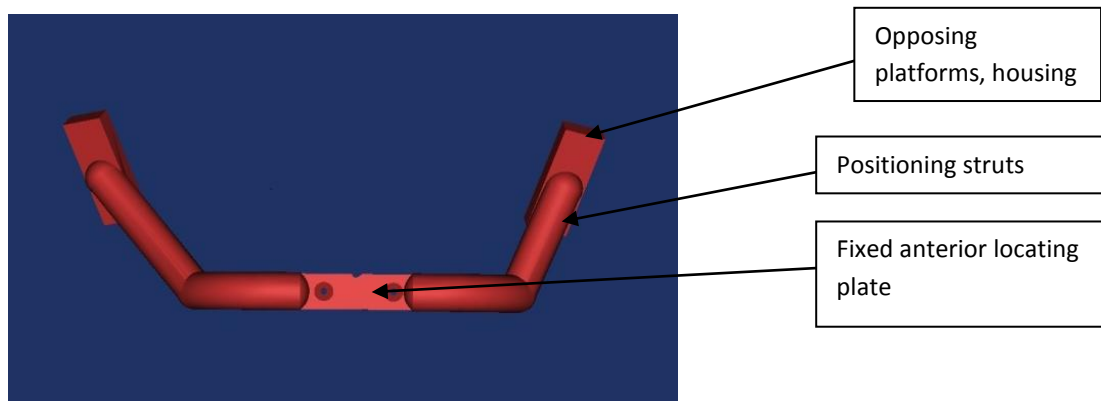
Prior design concepts highlighted areas of weakness that required to be addressed within the multi component framework; the magnetic retention and rigidity of the guide was deemed a priority. The projection and the angle of the struts were modified to be positioned closer to the anatomical structure and to the contour of

the maxilla. This design was adopted to further reduce the unwanted posterior movement of the maxilla. The design of the frame allowed greater access to the area of bone around the piriform aperture to enable the titanium bone plates and screws to be placed, securing the maxilla in its final surgical position. The struts were increased to 6mm in diameter to ensure that there was minimal vertical posterior movement of the maxilla. A 50% increase in diameter reduced the deflection by 5 times; this is due to the deflection of a beam with a circular cross section being inversely proportional to the 4th power of the diameter.

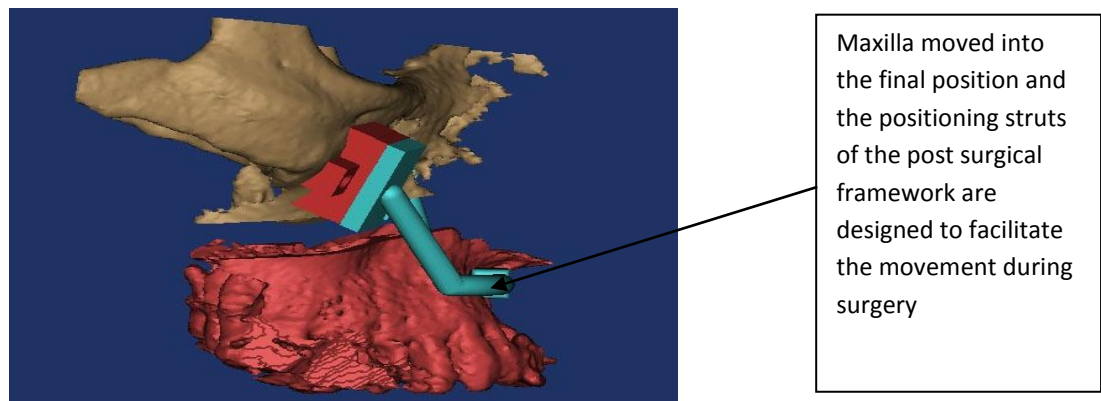
The repositioning guide comprised of four components; two 18mm x 15mm zygomatic locating plates that housed two magnets in each plate (Fig 3.3.3.1) and a presurgical (Fig 3.3.3.2) and a final position locating frame (Fig 3.3.3.3) which housed two magnets on either side.



**Figure 3.3.3.1 Two magnet recesses in the right and left zygomatic locating plates**



**Figure 3.3.3.2 Presurgical positioning and drill guide framework**



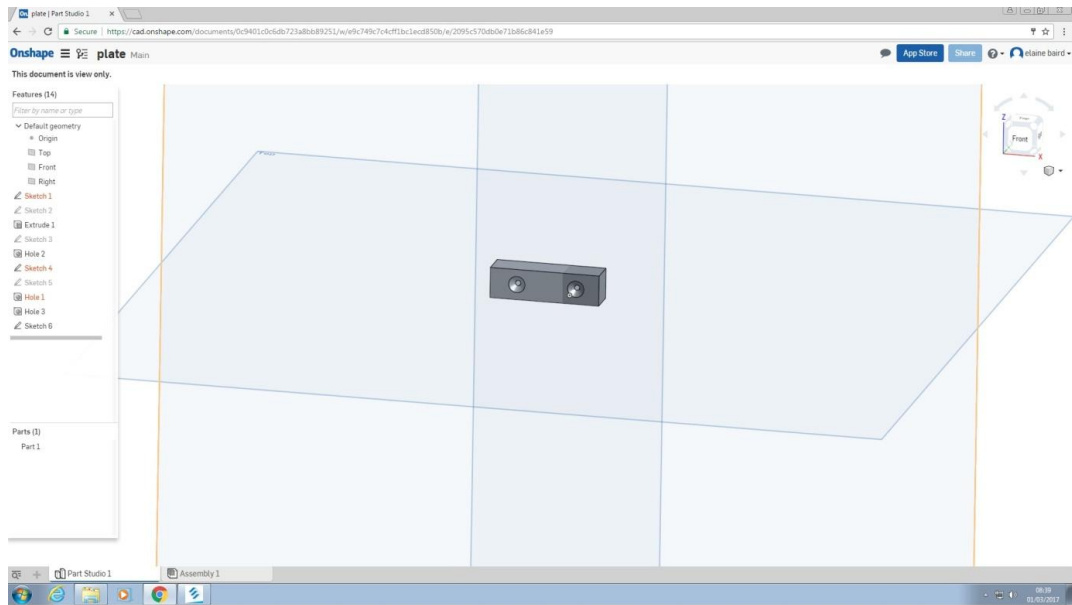
**Figure 3.3.3.3 Lateral view of the final position locating framework in situ**

### **3.4 Design and Construction of the Anatomical Locating Plates**

The DICOM data of the plastic skull was imported into the Mimics manipulation software programme. A defined protocol was followed for the generation of the 3D image of the virtual plastic skull. Firstly the data was thresholded; the software programme enabled the threshold to be set for a variety of soft and hard tissue including skin, muscle, fat tissue and enamel. The software allowed a custom setting to be selected if none of the available preset threshold values were adequate. The preset “Bone” threshold was sufficient for this study as it provided optimal image

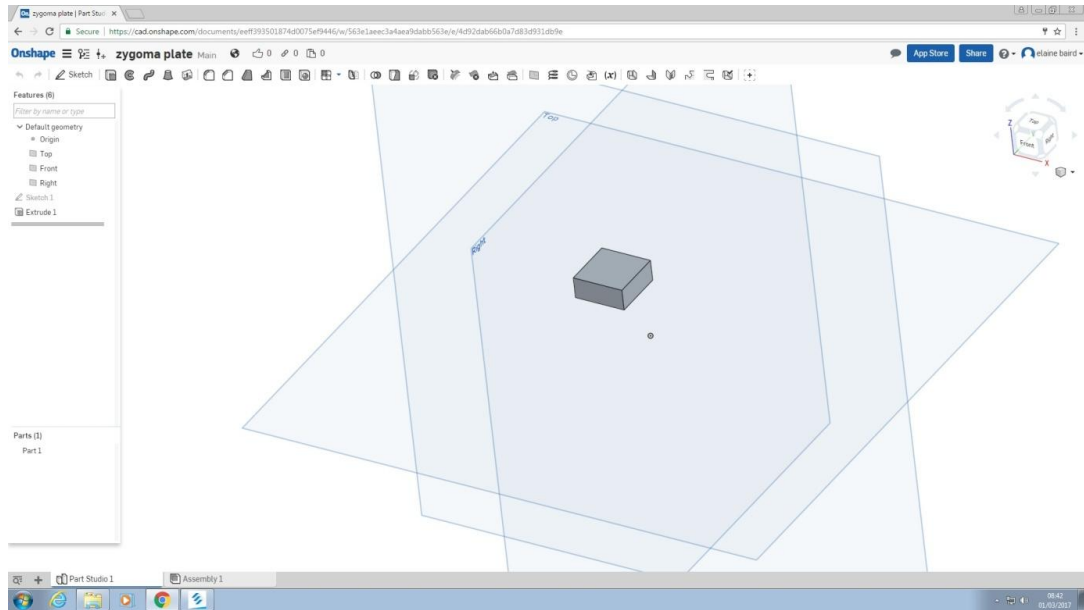
quality without image loss or distortion. Custom threshold settings were explored and disregarded as they displayed no benefit to the image quality. Increasing the threshold value created image noise, and a decrease in threshold values resulted in image loss. Once the threshold was selected, the data was converted into a 3D virtual image using the “calculate in 3D” function.

Three locating plates were CAD/CAM designed using OnShape CAD Software (Cambridge, MA 02140). The first locating plate (nasal locator) which sat anatomically onto the maxillary bone underneath the anterior nasal spine was designed using the “sketch” tool to create a 20mm x 6mm rectangle. The “extrude” function was utilised to create a 3 dimensional rectangle; two 2mm holes, 10mm apart, were digitally created and then counter sunk (Fig 3.4.1) to receive the titanium bone screws for maxillary fixation before surgery.



**Figure 3.4.1 3D Nasal locator with counter sunk holes designed using Onshape CAD software**

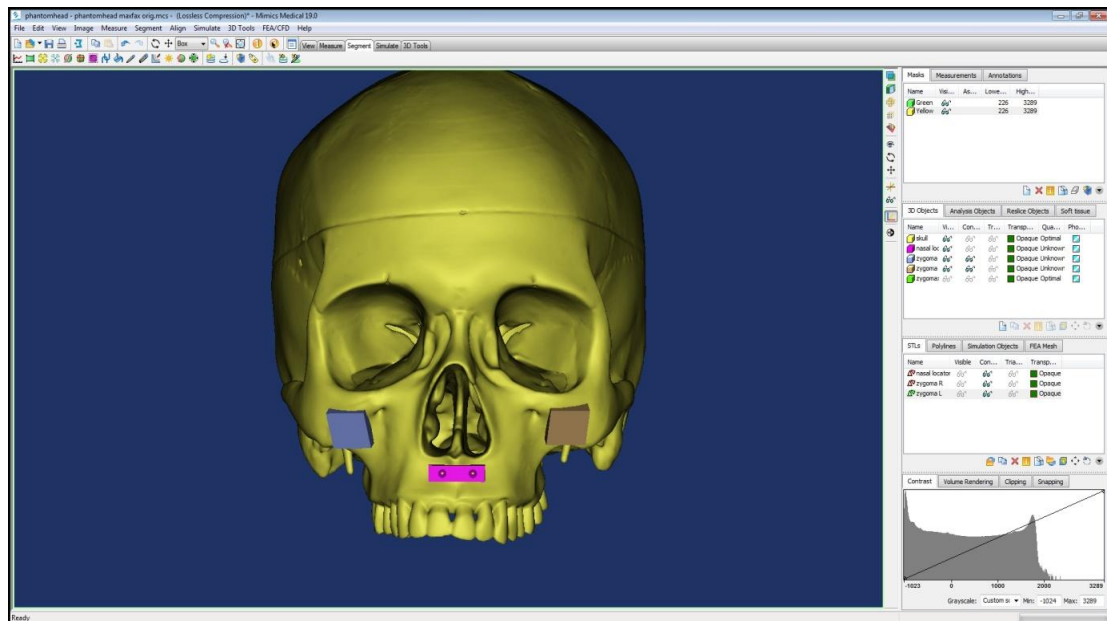
The right and left zygomatic locating plates were initially designed as solid blocks using the same technique adopted for the nasal locator (Fig 3.4.2). The zygomatic plates were designed to cover a greater surface area of bone to house two retention magnets and two fixation screw holes later in the design process. The two plates were designed using Onshape CAD programme and on completion all three plates were exported individually as STL files and imported in to the Mimics manipulation software programme.



**Figure 3.4.2 Basic shape of the zygomatic locating plates designed using OnShape CAD software**

The “repositioning” tool was utilised to position all three locating plates independently onto their correct anatomical position within the virtual environment. The nasal locating plate was positioned to overlay the area inferior to the anterior nasal spine below the Le Fort I osteotomy cut line. This ensured the locator was positioned 7-8mm superior to the root apexes of the upper anterior teeth which are approximately 10 millimetres in length. The screws used to retain the nasal locator therefore would not impinge on the roots of the upper anterior teeth. The right and left zygomatic plates were placed over the zygomatic buttress region of the 3D virtual skull (Fig 3.4.3). Based on the surgeon’s recommendation, the anatomical position of the zygomatic plates was selected to ensure that the surgeon could easily access the surgical site with minimal inconvenience. The plates were positioned laterally to the piriform aperture to allow surgical access for

anterior fixation with the use of titanium bone plates and screws once the maxilla had been moved to the final prescribed position.



**Figure 3.4.3 The locating plates overlaid onto the bony surface prior to carrying out a boolean subtraction**

The fitting surface of the right and left zygomatic and nasal locator plates were anatomically contoured to fit the skeletal morphology. This was achieved in the 3D environment using a “segmentation” function within the 3D software package to perform a Boolean subtraction between the fitting surface of the locating plates and the surface of the host bone (Fig 3.4.4). This process subtracted the anatomical shape of the zygomatic bone from the fitting surface of the zygomatic plate to produce a fitting surface that sat passively onto the specific area of bone (Fig 3.4.5). The advantage of this method is that it would be visually evident if the locating plates have been incorrectly positioned during surgery. The framework would be

misaligned with pronounced gaps between the host bone and the fitting surface of the locators.

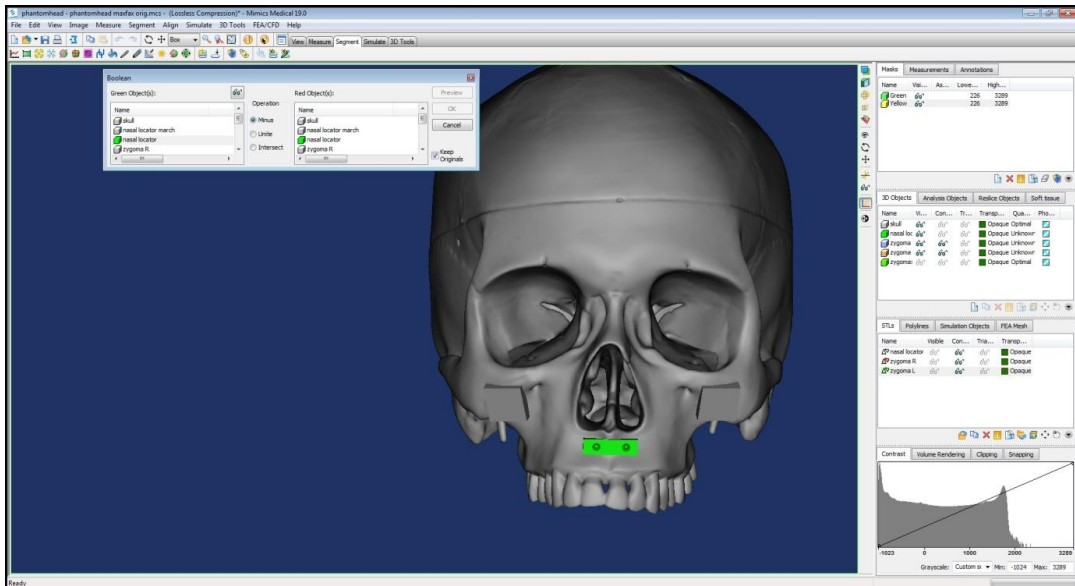


Figure 3.4.4 Boolean subtraction of the skull from the fitting surface of the locating plates

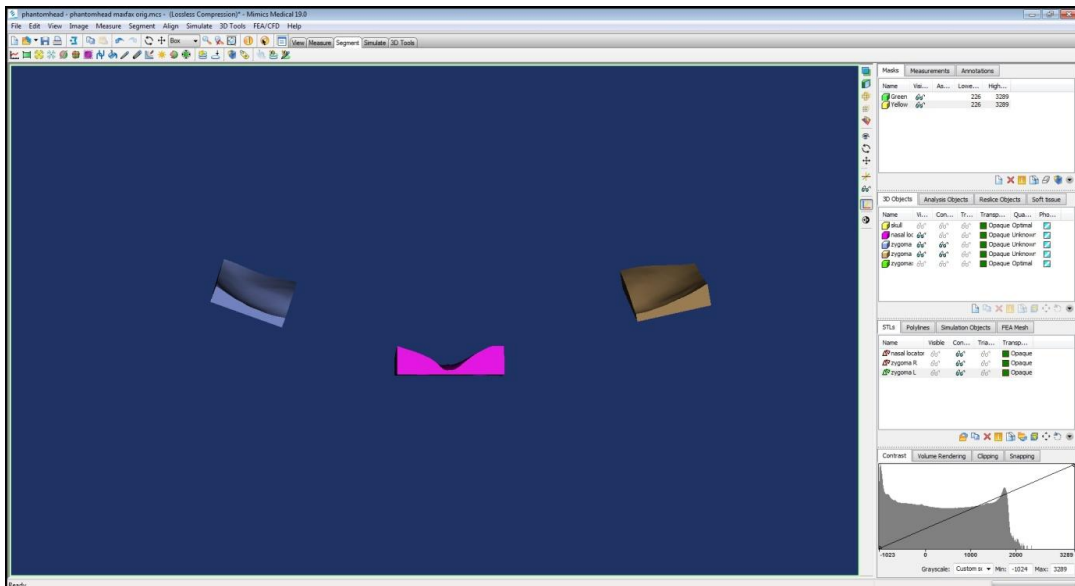
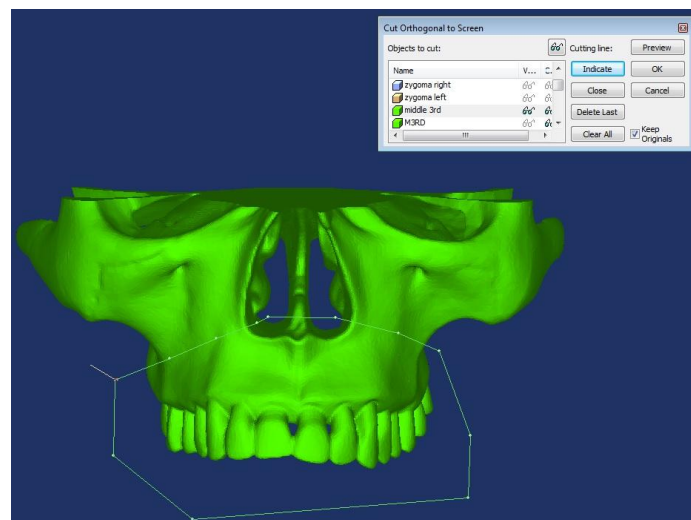


Figure 3.4.5 Anatomically shaped fitting surface of the locating plates



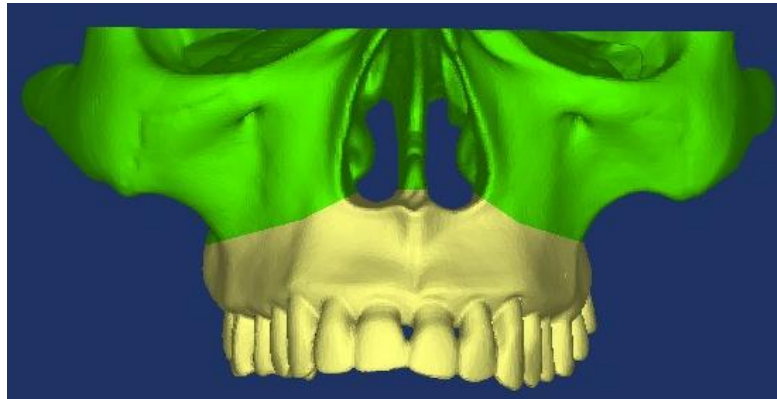
The skull was cropped to reduce the data file size for exporting and importing purposes to external CAD software programmes. The middle third of the skull provided sufficient information to perform the surgical movements of the maxilla and for the production of the anatomical repositioning guide.

The maxilla was separated from the base of the skull to be repositioned into the desired location while the skull remained in the static position. This process was performed using the “cut orthogonal to screen” function. Points were plotted depicting the cut line that was required to separate the maxilla from the skull (Fig 3.4.6).



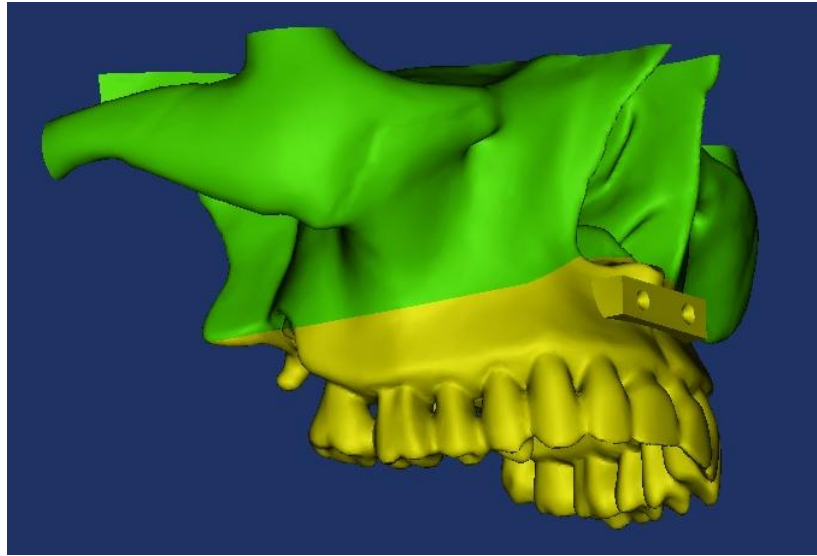
**Figure 3.4.6 Process of separating the maxilla using "cut orthogonal to screen" function using the Mimics software programme**

The maxilla was split from the skull that created two masks, the first mask was renamed “middle 3<sup>rd</sup>” and the second mask was named the “maxilla” (Fig 3.4.7).



**Figure 3.4.7 Maxilla separated from the cranial base of the skull**

A duplicate nasal locator was created and fused to the maxilla using the “boolean tool” to unite the maxilla with the nasal locator (Fig 3.4.8). This process ensured the nasal locator was carried in the correct position along with the maxilla when maxillary movements were performed. If this fusion was not completed the maxilla would move to the prescribed position and the nasal locator would stay static in the original position. The position of the nasal locator played a vital role in the accurate surgical positioning of the maxilla. At this stage in the process virtual 3D surgical movements could be performed.



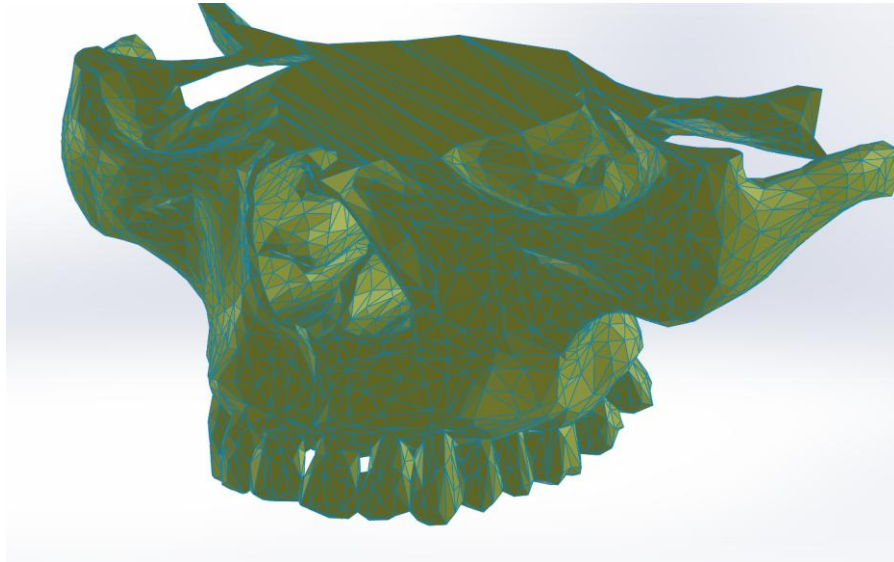
**Figure 3.4.8 Nasal locator fused onto the maxillary segment**

The anatomically shaped right and left zygomatic plate, nasal locator and the middle third of the skull with the fused nasal locating plate were exported individually as a binary STL files and imported into Solidworks (Massachusetts USA) CAD software.

The aforementioned process provided the foundations to CAD/CAM the anatomically shaped surgical locating plates and finalise the design of the repositioning framework. This stage was completed with the expertise obtained from the clinical engineering department at the National Health Service Greater Glasgow and Clyde Medical Devices Unit, whom possessed advanced knowledge and skills in operating the Solidworks CAD programme.

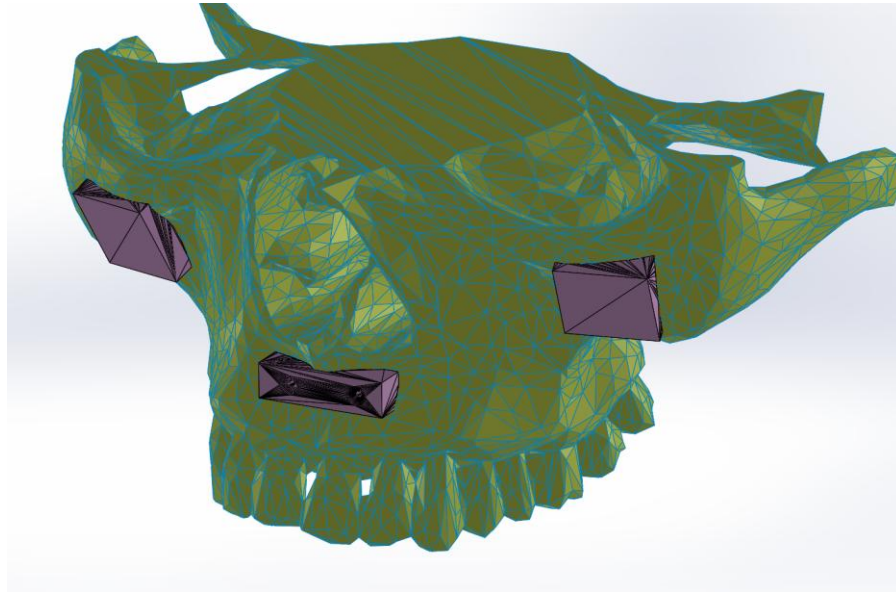
### 3.5 Preoperative Frame Design

The presurgical skull was imported as an STL file into Solidworks as a CAD assembly file (Fig 3.5.1).



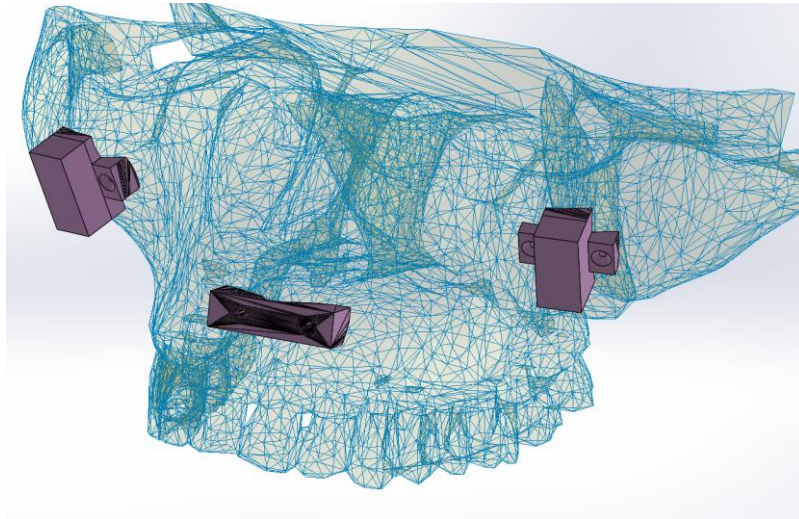
**Figure 3.5.1 Presurgical skull imported into Solidworks CAD software programme**

The nasal locator and left and right zygoma plates (designed in Mimics) were each imported into a CAD assembly file in the correct position against the skull. Shared co-ordinate systems from Mimics ensure that this correct position was achieved (Fig 3.5.2).



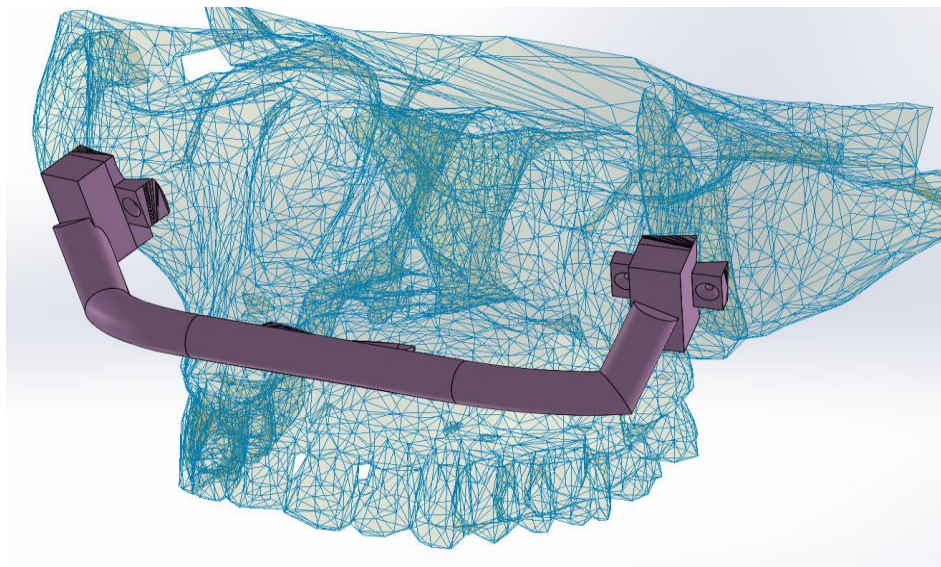
**Figure 3.5.2 Nasal locator and left and right zygoma plates positioned onto the CAD assembly using shared co-ordinate systems for Mimics**

A copy of the nasal locator was imported into the CAD assembly file in Solidworks for use at later stage. The design of zygoma plates was refined using Solidworks CAD modelling tools, to introduce fixing features and the removal of unnecessary material (Fig 3.5.3).



**Figure 3.5.3 CAD modelling tools were utilised to refine and introduce fixing features on the zygoma plates**

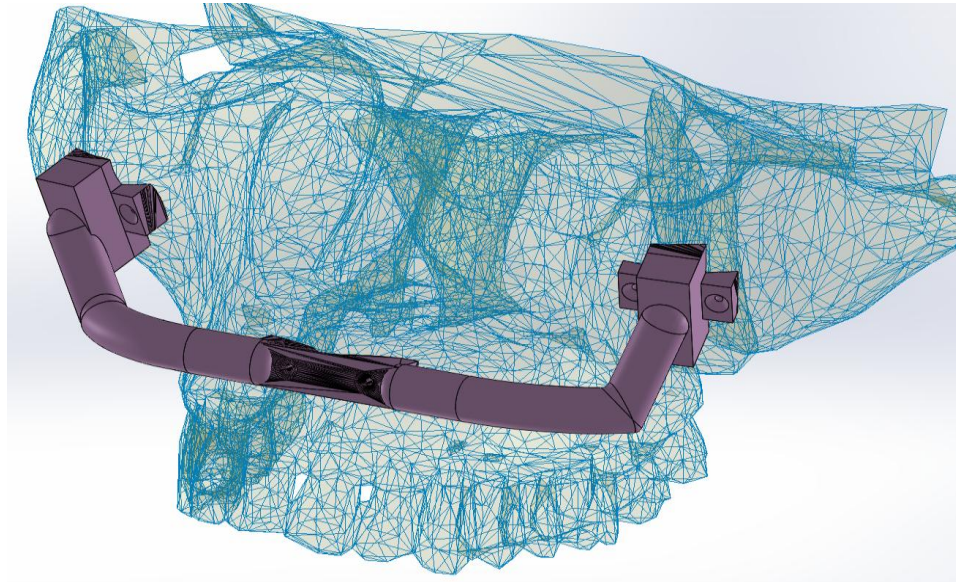
The frame structure was created using CAD modelling tools, parametrically anchored to the nasal locator and left and right zygoma plate (Fig 3.5.4).



**Figure 3.5.4 Frame structure created and parametrically anchored to the nasal locator and the right and left zygoma plates**

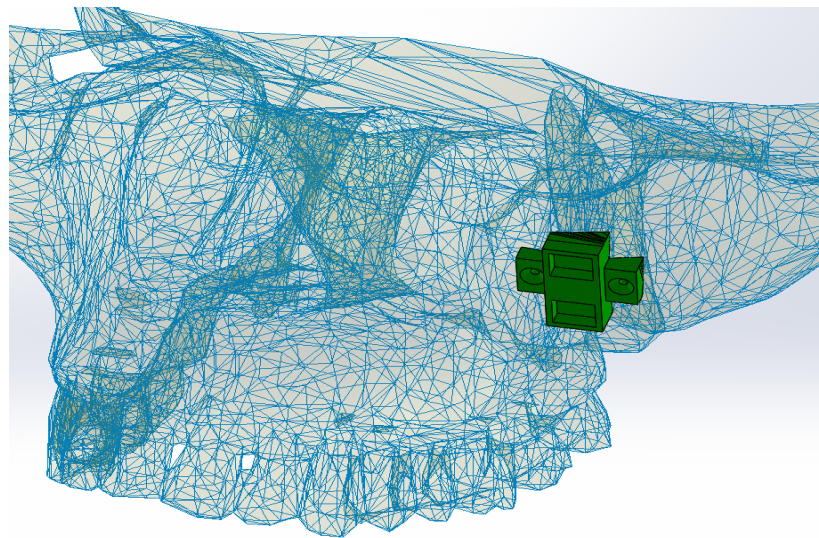
The nasal locator and zygoma plates were then joined to the frame (Fig 3.5.5).





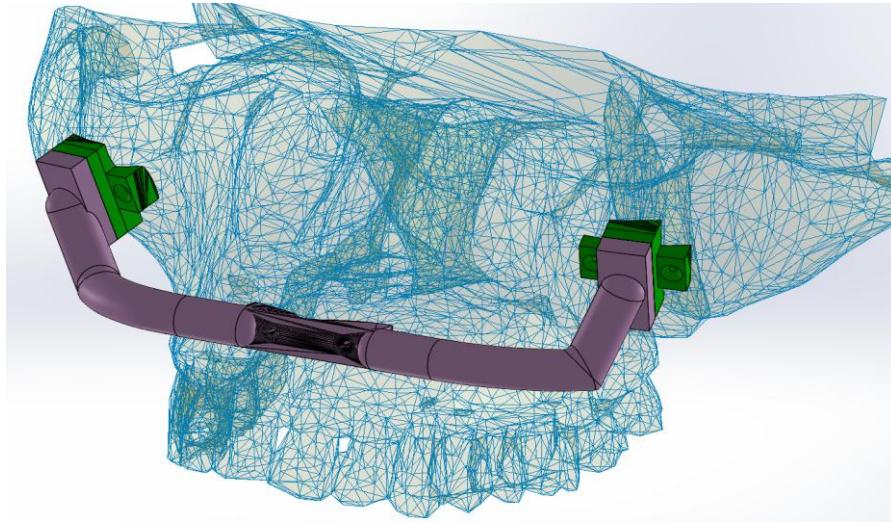
**Figure 3.5.5** The nasal locator and right and left zygoma plates are now joined to the frame; creating the complete assembly

The zygoma plates were split to allow the introduction of magnet recesses (Fig 3.5.6).



**Figure 3.5.6** Magnet recesses were created from the split zygoma plates

The preoperative frame and (split) zygoma plates were saved as separate STL files (Fig 3.5.7).



**Figure 3.5.7 Colour change in the zygoma plates indicate they have been separated from the framework assembly and are now ready for exporting as an STL file**

The preoperative assembly was saved as an STL file and rapid prototyped using a stereolithographic (SLA) 3D printer with a printing layer thickness of 25 microns (Formlab2, Massachusetts, USA) (Fig 3.5.8). Stereolithography, commonly referred to as 3D printing is an additive manufacturing technology that converts liquid materials into solid parts. This is a layer by layer process using a light source for photopolymerisation. This type of technology is widely used in engineering, jewellery making, dentistry, model making and education to create models, patterns and production parts.

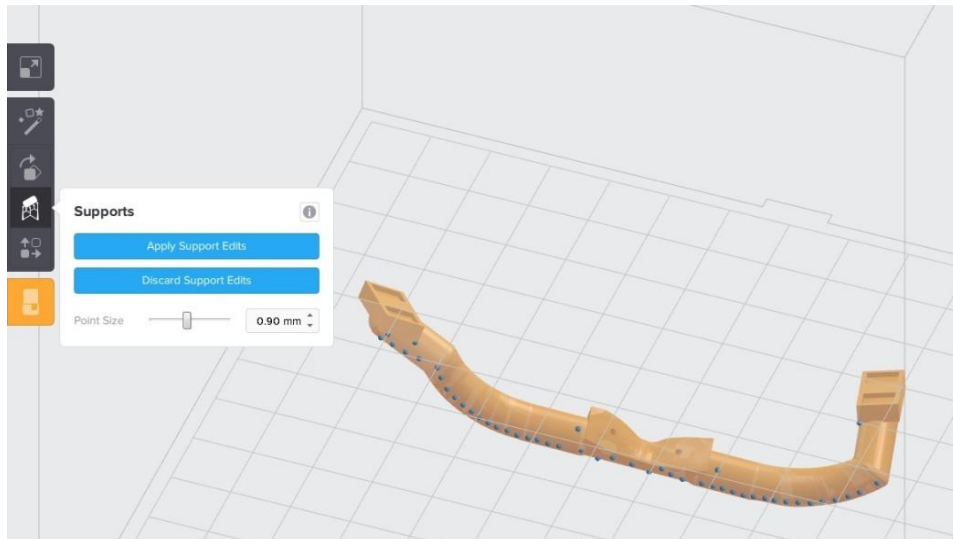




**Figure 3.5.8 Formlab Form2 SLA 3D printer used to print the custom made anatomical repositioning guide**

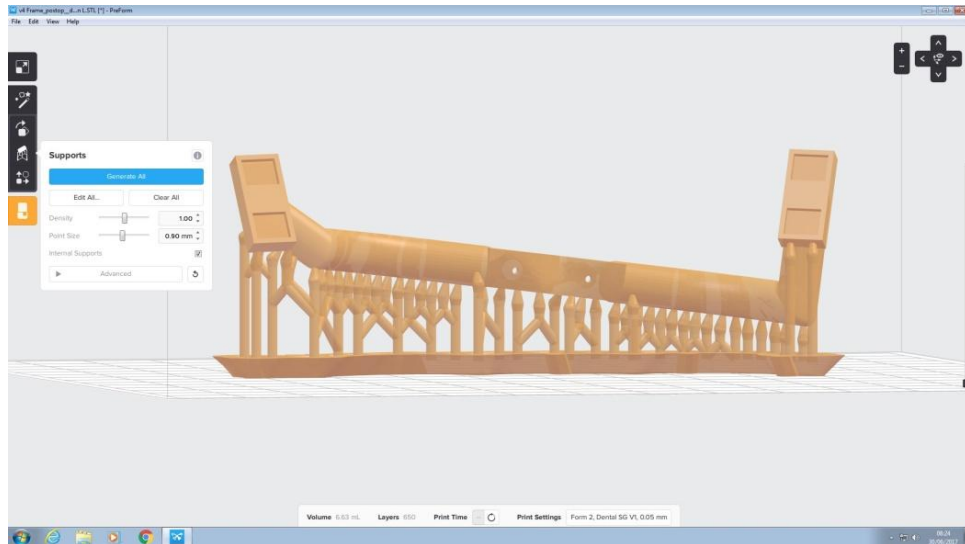The Form2 is classed as an inverted SLA printer. This method utilises a resin tank with a transparent bottom through which the light source (laser) cures the resin from below onto a non-stick build platform. The resin is slowly heated to 31°C then the platform is automatically lowered into the resin tank. The light source traces the pattern of the print and with each completed layer the build platform moves in an upward direction to allow the next layer to be laid. This process continues until the build process of the guide is complete.

The 3D printer's software generated support struts which prevented the structure from deformation during the printing phase. These supports were manually repositioned prior to printing to ensure the supports were not placed on the fitting surface of the locating plates within the framework (Fig 3.5.9).



**Figure 3.5.9 Manual repositioning of the support struts prior to printing; ensuring no struts are placed on the fitting surface of the guide**

Each blue dot on the surface of the preprint image represented where each support structure was attached to the final print. By using the edit function within the software each dot was highlighted and dragged to the desired position. The amended support structures were then applied and the 3D printer was activated for printing (Fig 3.5.10).



**Figure 3.5.10 Support structures applied post editing**

On completion of the 3D print, the full assembly was soaked in 90% isopropyl alcohol (IPA) in a rinse station that consisted of two small buckets filled with equal amounts of IPA. The assembly was agitated for thirty seconds and then allowed to soak for ten minutes in the first bucket of IPA, then the assembly was transferred to the second bucket and the process was repeated. This process is in keeping with the manufacturer's instructions to ensure an accurate and successful print as it rinses off any residual uncured resin on the surface of the printed parts.

On completion the assembly was placed in a light curing unit (BB cure midi, Meccatronicore, Trento, Italy) to post print cure (Fig 3.5.11). The recommended guidelines for post print curing is to cure the printed part for ten minutes to 108 watts each of Blue UV-A (315 – 400 nm) and UV-Blue (400 – 550 nm) light, in a heated environment at 60°C (140°F). This stage ensured optimal printed part properties such as strength and stability as recommended by the manufacturer.



**Figure 3.5.11 Light curing unit used to post cure the guide**

Upon post curing, the supports structures were removed with the aid of a snipping tool supplied as part of the accessory kit with the Formlab 2 3D printer (Fig 3.5.12).



**Figure 3.5.12 Framework post curing before the support structures were removed with the use of the snipping tool**

The frame was designed to be inter-changeable from the fixed locating plates with the use of magnetic retention (5 x 4 x 1.5 mm neodymium 0.5kg pull magnets).

These were secured into the recesses of the locating plates and the abutting locators on each frame with the use of cyanoacrylate glue (Loctite Precision) (Fig 3.5.13).

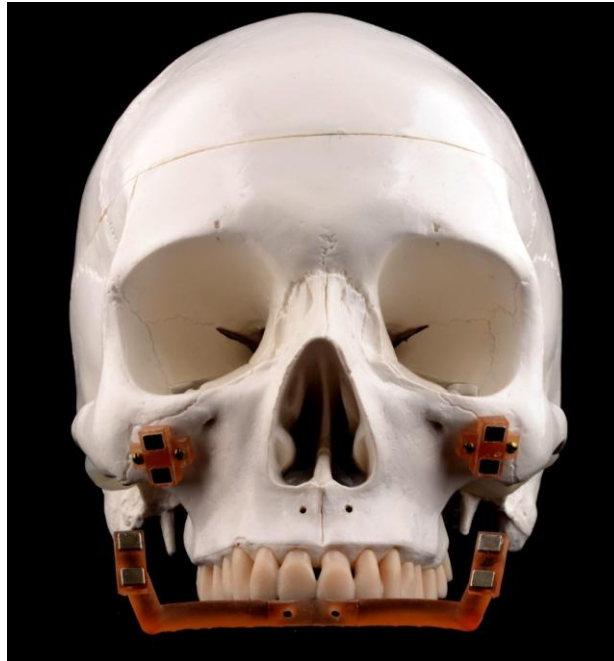

**Figure 3.5.13 0.5kg pull neodymium magnets secured within the recess of the guide using cyanoacrylate glue providing retention to the zygomatic plates**

It was determined from the findings of the initial design concepts that two magnets fixed in each locating plate and two magnets on either side of the adjacent framework prevented the framework from being dislodged from the locating plates on the zygomaxillary buttress, when subjected to down and backward forces. The design of the framework limited the size of magnets that could be used. Therefore magnets were selected with a size to power ratio that would be sufficient in supporting the framework to the locating plates. (Fig 3.5.14).

It was essential to ensure the polarities of the corresponding magnets were correctly facing north to south towards each other to achieve magnetic retention. A result of incorrect positioning of the magnet, for example two magnets opposing

each other with a south to south polarity will result in the magnets repelling each other and retention cannot be achieved.

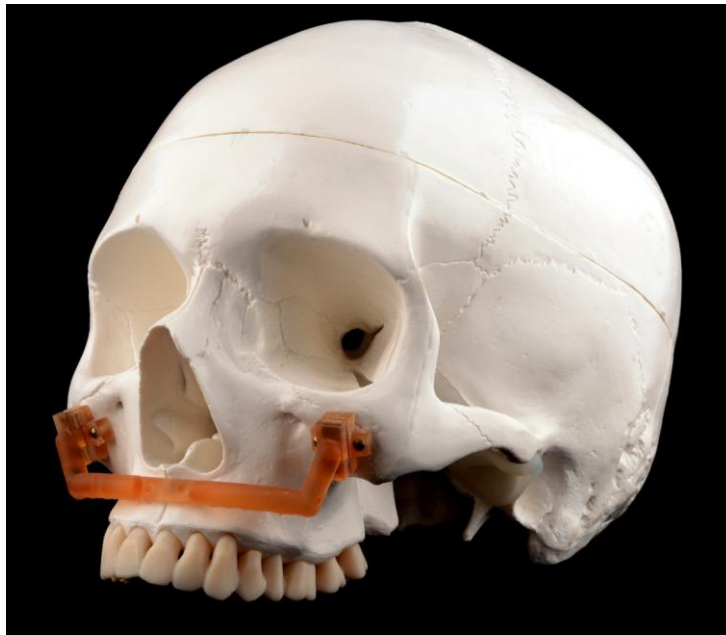

**Figure 3.5.14 Magnetic retention secured in position on the zygomatic plates and on the opposing framework**

Once each magnet was correctly positioned and securely fixed in place, the zygomatic locating plates and the preoperative framework were magnetically attached together and offered up to the skull where it engaged the inferior aspect of the anterior nasal spine and the zygomatic buttresses. The anatomical fit was visually assessed to ensure the full assembly sat passively to the surface of the host bone.

Prior to performing the surgical bone cuts, the anatomical locating plates and the presurgical frame was utilised to pre drill the fixation pilot holes with the use of a 2mm drill bit and secured in position utilising the retention holes designed within

assembly with the use of six 2.0x10mm Stryker, cross pin self tapping titanium bone screws. Two screws secured each of the locating plates onto the zygomatic buttress and two screws secured the presurgical framework, which was anatomically positioned under the anterior nasal spine. This initial preoperative frame served as the drill guide for the second and final frame that guided the maxilla into the desired position (Fig 3.5.15).



**Figure 3.5.15 Zygomatic locating plates and preoperative framework secured in position using six titanium self-tapping bone screws**

The advantage of a removable framework was that the final positioning frame could be removed and replaced accurately several times from the fixed locating plates during surgery. This allowed for bone trimming, enabling the correct maxillary position without causing bone damage as a result of the repeated removal and reinsertion of the screws.

### **3.6 Digital Simulation of the Orthognathic Surgical Movements of the Maxilla**

Forty-three Le Fort I orthognathic surgery movements were planned to incorporate various combinations of maxillary advancement, vertical height change and pitch, roll and yaw of the maxilla. These movements replicated scenarios commonly observed in the surgical environment. The skull was repositioned to replicate the NHP and then the maxillary surgical movements were carried out virtually using the Mimics manipulation software programme.

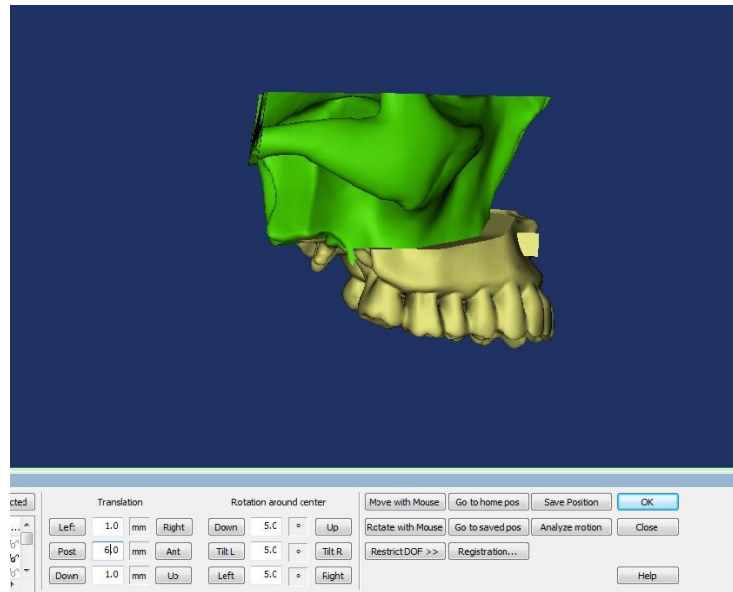
#### **3.6.1 Maxillary Advancement**

Three maxillary advancements (antero-posterior) were performed in a linear movement encompassing a small advancement of 3mm, a moderate advancement of 6mm and the upper limit of antero-posterior movement of 10mm as would be observed in patient treatment (Table 3.6.1.1).

Antero-Posterior Advancement
3mm
6mm
10mm

**Table 3.6.1.1 The Measurements of maxillary advancement in mm**





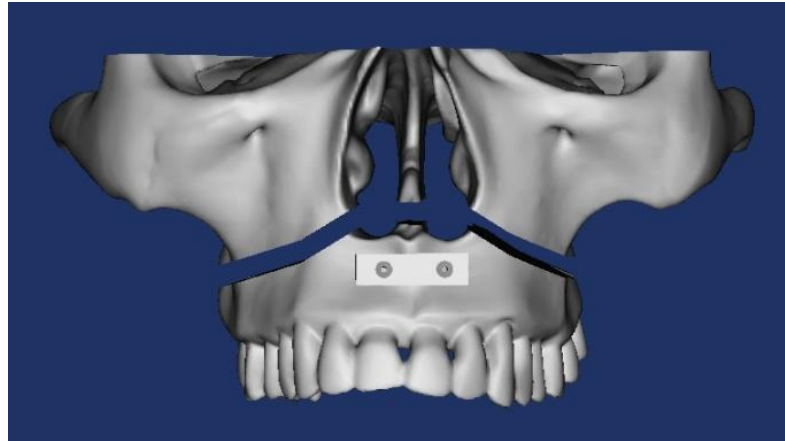
**Figure 3.6.1.1 Maxilla advanced 6mm using the "Repositioning" function within the Mimics manipulation programme**

### 3.6.2 Maxillary Vertical Height Change

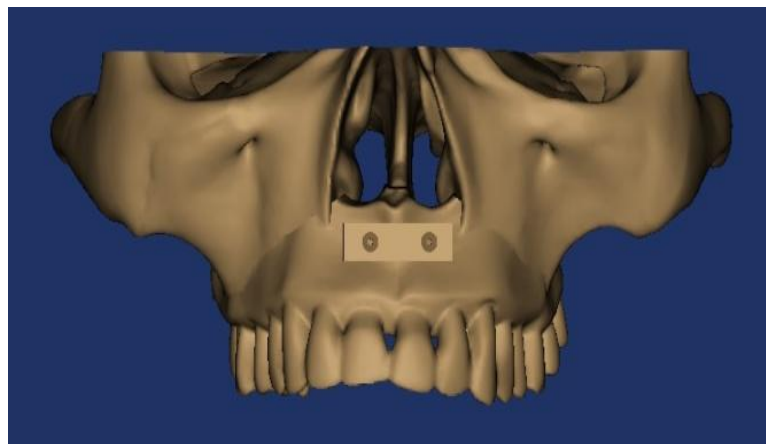
Maxillary vertical height changes were performed using linear movements (Table 3.6.2.1). The maxilla was moved in a downward direction (downgraft). This movement is performed to increase the facial vertical height by 2mm, 4mm and 6mm (Fig 3.6.2.1) and by moving the maxilla in an upward direction (impaction) decreased the vertical height of the maxilla by 2mm, 4mm and 6mm (Fig 3.6.2.2). Altering the height of the maxilla is required to reduce or increase the amount of tooth is visible when the patient is at rest and on full smile. At rest the average tooth show is 2-3mm and on full smile the entire crown of the tooth should be visible minus gingival show.

Downgraft	2mm	4mm	6mm
Impaction	2mm	4mm	6mm

**Table 3.6.2.1** Linear height change in the vertical dimension defined as downgraft and impaction



**Figure 3.6.2.1** Downward movement of the maxilla increasing the vertical facial height



**Figure 3.6.2.2** Upward movement of the maxilla decreased the vertical facial height, reducing the amount of tooth show

### 3.6.3 Combination of Maxillary Advancement and Vertical Height Change

The maxilla was advanced once again by 3mm, 6mm and 10mm in an antero-posterior direction, incorporating an impaction and downgraft of 2mm, 4mm and 6mm vertical height change (Fig 3.6.3.1 & 3.6.3.2) (Table 3.6.3.1).

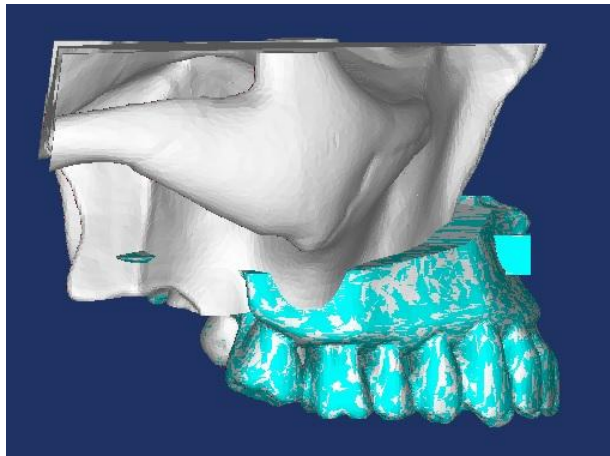


Figure 3.6.3.1 Virtual maxillary advancement and impaction

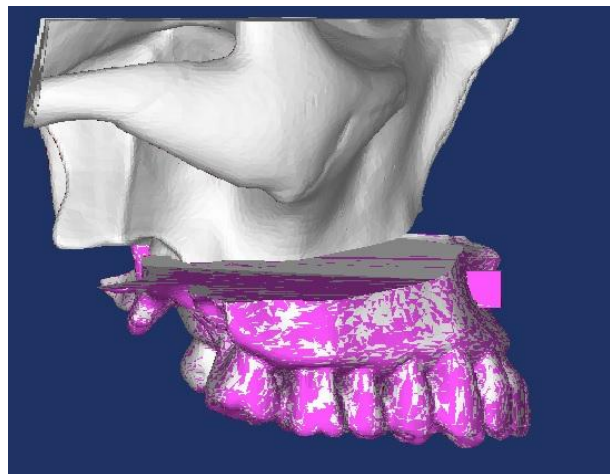


Figure 3.6.3.2 Virtual maxillary advancement and downgraft

Advance	Impact			Down		
3mm	2mm	4mm	6mm	2mm	4mm	6mm
6mm	2mm	4mm	6mm	2mm	4mm	6mm
10mm	2mm	4mm	6mm	2mm	4mm	6mm

**Table 3.6.3.1 Magnitude of maxillary advancement with combined impaction and downgraft**

### 3.6.4 Maxillary Rotational Movements (Pitch, Roll and Yaw)

Planning software programmes measure the rotational movements in degrees rather than millimetres as observed in linear advancements and vertical height change of the maxilla. Rotational movements of the maxilla included a centre line rotation (yaw) for the correction of the dental and skeletal midline at 1° and 3° to the left (Table 3.6.4.1). This was achieved by positioning the virtual skull in “worm’s eye” view to expose the full palate of the maxilla. It was agreed that the point of rotation was at the posterior nasal spine to replicate the yaw of the maxilla.

Rotation of the maxilla to the left	1°	3°
-------------------------------------	----	----

**Table 3.6.4.1 Measurement in degrees of maxillary rotation to the left for centre line correction**

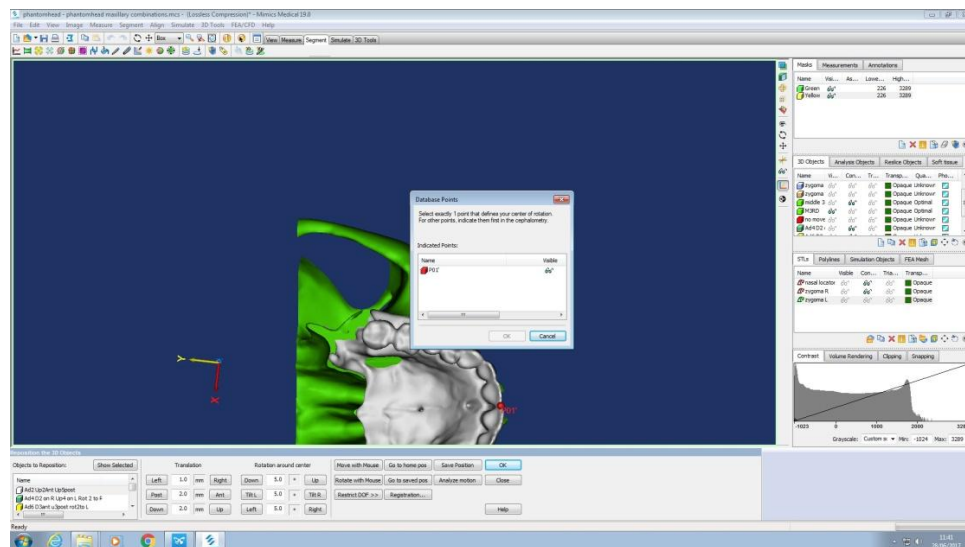
It was essential to rotate the maxilla around a fixed point designated by the operator. The point of rotation was determined in the “repositioning” tool within Mimics by selecting the “Restricting DOF” (restricting the degrees of freedom) function allowing a rotational point to be manually placed (Fig 3.6.4.1). The amount



Measurement of posterior impaction (Pitch)	3°	6°
--	----	----

**Table 3.6.5.1 Measurement alteration to the pitch of the maxilla (posterior impaction)**

The point of rotation was manually selected as described previously for the centreline rotation. However the point of rotation for posterior impaction was positioned in the mid-line of the incisal edge of the upper central incisor teeth and the maxilla was rotated around the X axis (Fig 3.6.5.1). By fixing the point of rotation around the upper central incisors, the posterior section of the maxilla was moved up or down as required with no change of the anterior vertical height at the upper incisors.



**Figure 3.6.5.1 Rotational point positioned and fixed on the dental mid-line of upper central incisors**

### **3.6.6 Differential Impactions (Roll)**

Maxillary occlusal canting is a feature observed in skeletal asymmetry cases in which there is a vertical discrepancy of the facial skeleton. These types of asymmetries are diagnosed clinically by a commonly practiced method of placing a wooden tongue depressor across the dental arch of the maxilla at the premolar region and comparing it to the true horizontal or inter-pupillary line of the patient. Surgical treatment of a maxillary occlusal cant involves impacting or down grafting the maxilla on the side of the height discrepancy.

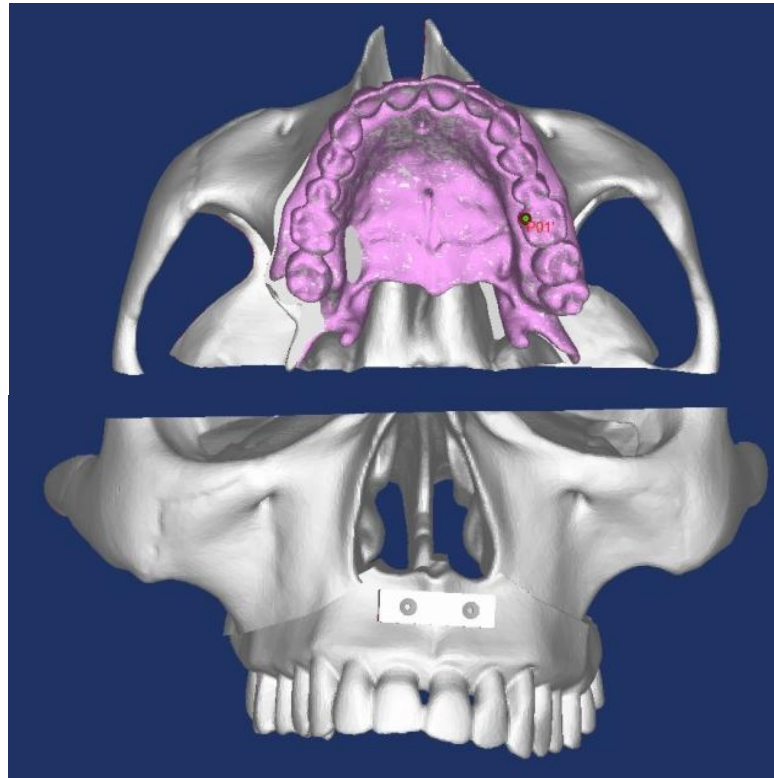
Differential impactions were performed to replicate the correction of maxillary occlusal canting. Nine variations of differential maxillary impaction was replicated in an upwards direction by 2°, 4° and 6° on the right side of the maxilla and in a downwards direction by 2°, 4° and 6° on the right hand side of the maxilla. A combination of the upwards and downwards movements were defined and the maxilla was moved downwards on the right by 2° with a 2°, 4° and 6° impaction on the left hand side consecutively (Table 3.6.6.1).

Direction of vertical height change of maxilla on the right side only	Impaction	Downgraft
	2°	2°
	4°	4°
	6°	6°
Combination of impaction and downgraft (Differential height change)	Downgraft on the right side of the maxilla	Impaction on the left side of the maxilla
	2°	2°
	2°	4°
	2°	6°

**Table 3.6.6.1 Variation in differential impactions performed to level maxillary occlusal canting**

Planning the surgical correction of a maxillary occlusal cant using Mimics required the point of rotation to be manually selected and the degree of freedom was restricted using “Restrict DOF” tool. The point of rotation for the maxillary impaction on the right hand side was placed on the lingual cusp of the first left molar. The required degree of movement was applied to rotate the maxilla around the Y axis using the “repositioning” tool within the software programme (Fig 3.6.6.1).





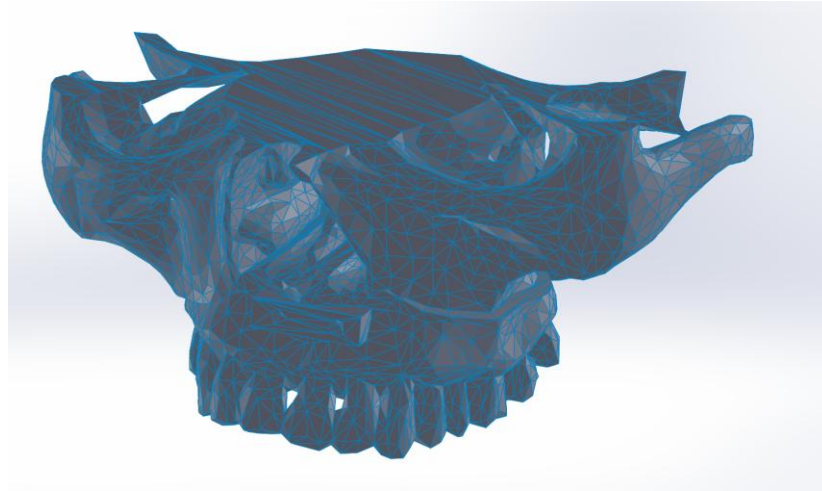
**Figure 3.6.6.1 Rotational point placed on the lingual cusp of upper left first molar and maxilla rotated around the Y axis**

Differential impactions were completed by selecting the point of rotation on the lingual cusp of the upper left first molar. The maxilla was rotated around the Y- axis to lower the right side by  $2^{\circ}$ . The point of rotation was relocated to the upper lingual right first molar. This allowed the maxilla to be rotated around the Y+ axis by  $2^{\circ}$ ,  $4^{\circ}$  and  $6^{\circ}$ .

On completion of all the required movements, each plan was saved as an STL file and exported into Solidworks as previously described for the production of the postoperative frameworks.


### 3.7 Postoperative Frame Design

The STL file of the postoperative skull with the integrated nasal locator was imported into Solidworks CAD software programme (Fig 3.7.1).



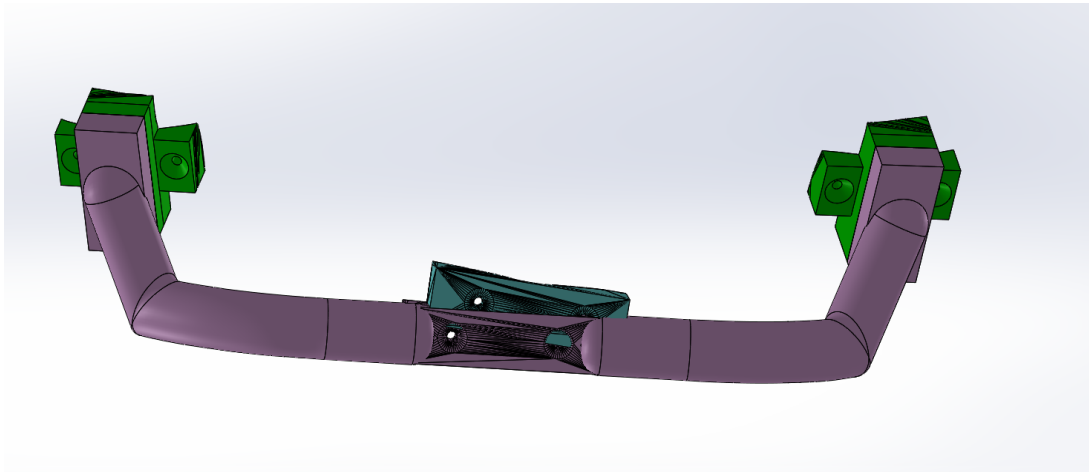
**Figure 3.7.1 Postoperative skull STL file with integrated nasal locator imported into Solidworks**

The duplicate nasal locator was co-located with the post-surgical skull STL file using CAD 'mate' tools (Fig 3.7.2).

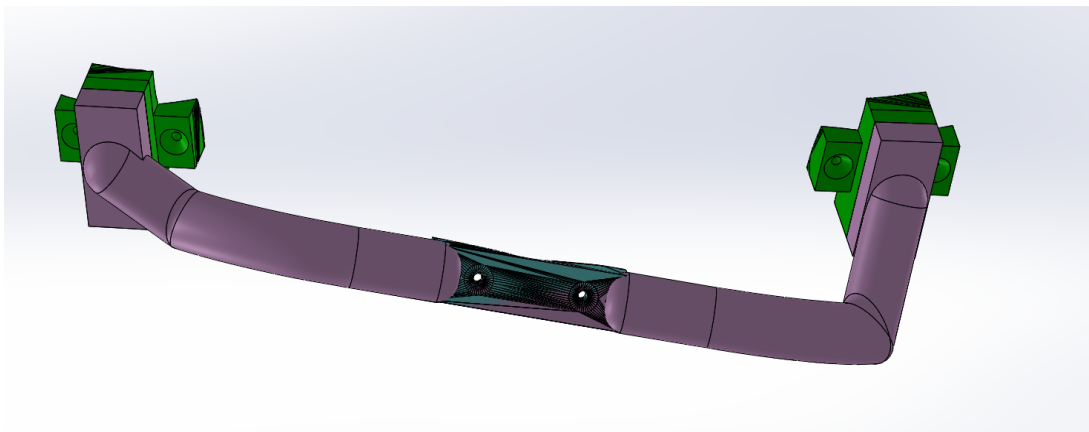


**Figure 3.7.2 Duplicate nasal Locator co-located onto the fused nasal locator using the CAD 'Mate' tool**

Once the nasal locator was moved and rotated ensuring it was co-located with copy nasal locator, the frame automatically adjusted to fit the new geometry (Fig 3.7.3 & 3.7.4).

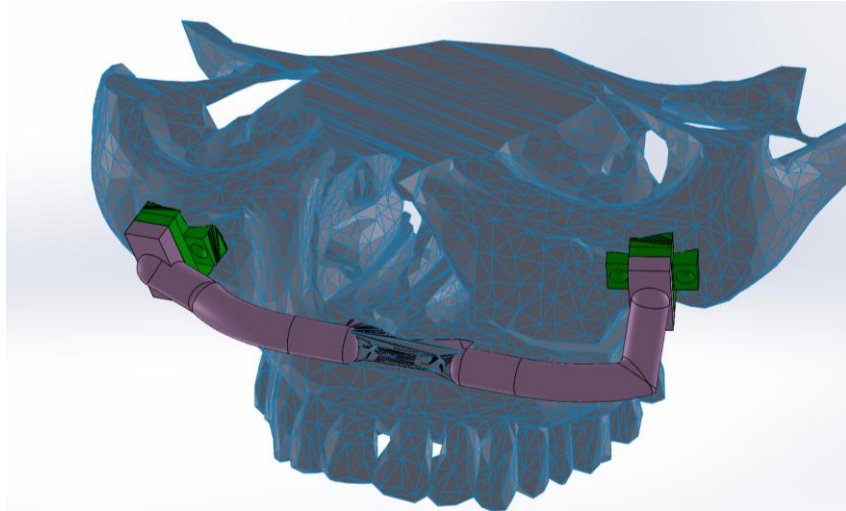


**Figure 3.7.3 Nasal locator on the assembly ready to be co-located with the nasal locator of the maxilla in the final position**

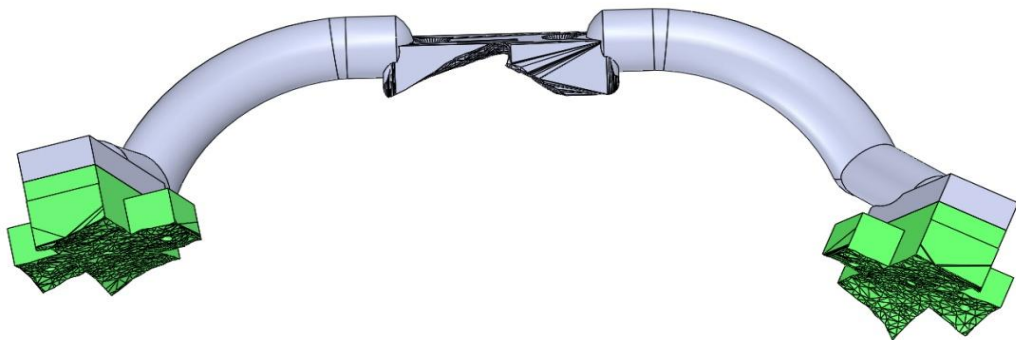


**Figure 3.7.4 Nasal locator co-located with the final position nasal locator automatically creating the CAD assembly of the postoperative framework**

The postoperative framework was visualised on the CAD image of the skull prior to exporting as an STL file (Fig 3.7.5 & 3.7.6).



**Figure 3.7.5 Postoperative framework fully visualised on the CAD skull prior to exporting as an STL file**



**Figure 3.7.6 Postoperative positioning framework designed Using Solidworks CAD/CAM software**


On completion of each guide being CAD/CAM designed, they were each saved as an STL file enabling all the guides to be printed in the exact same manner as the preoperative guide described previously in the chapter.

### **3.8 Physical Simulation of the Orthognathic Surgical Movements of the Maxilla**

The maxilla was then separated from the plastic physical skull with the use of a KaVo K4 handpiece (Kavo Dental Warthausen, Germany), a fine cutting disc and a standard laboratory tungsten acrylic bur. The cut performed on the maxilla replicated a typical Le Fort I osteotomy and the base of the skull was trimmed to allow the maxilla to be impacted without obstruction.

### **3.9 Assessment of the Accuracy of Repositioning the Maxilla with the use of the Custom Made Anatomical Repositioning Guide**


In order to determine the accuracy of the repositioned maxilla when using the custom made anatomical repositioning guide, the skull was surface scanned with each guide in situ. This was achieved by fixing the maxilla in the new final position determined by each of the forty three custom made guides using titanium bone screws. A surface scan was captured for all the planned movements and for this a GOM ATOS triple scan optical blue light surface scanner (GOM Braunschweig, Germany) was used (Fig 3.9.1). This scanner has been aerospace certified for accuracy and repeatability at 10 microns according to the manufacturer. The triple scan operates with three sensors that work independently from each other in one system scanning from left to right, capturing a high resolution 3D scan.




**Figure 3.9.1 GOM ATOS triple blue light surface scanner**

The maxilla was moved into each new desired position and fixed in place using the corresponding guide with titanium bone screws. The skull with the top section of the cranium removed was positioned upside down on a revolving platform to prevent the maxillary position from being accidentally altered (Fig 3.9.2). The revolving platform is in conjunction with the GOM ATOS scanner and it rotates as the data is being captured to allow the full surface of the skull and dentition to be imaged (Fig 3.9.3).





**Figure 3.9.2 Physical skull with postoperative guide secured in position and placed on the rotating table prior to capturing the scan image**



**Figure 3.9.3 GOM ATOS scanner capturing the surface image of the physical skull with the postoperative guide in situ**

Collecting the image of the entire skull and dentition was fundamental for assessing the positional accuracy of the guide. Superimposition of the 3D image of the planned digital movement and that of the scanned image of the physical movement was then assessed in three dimensions.

### **3.10 Superimposition of the CAD Skull and Physical GOM ATOS Scan Data**

GOM Inspect (GOM Braunschweig, Germany) evaluation software was used for the analysis. This software package is designed for analysis and evaluation of 3D measuring data derived from GOM systems, 3D scanners, laser scanners, CT scanners, Coordinate Measuring Machines and other sources. The GOM Inspect software packages have been tested and certified by the National Metrology Institute of Germany (PTB) and the National Institute of Standards and Technology (NIST). The GOM software has been placed in category 1, the category with the smallest measurement deviations.

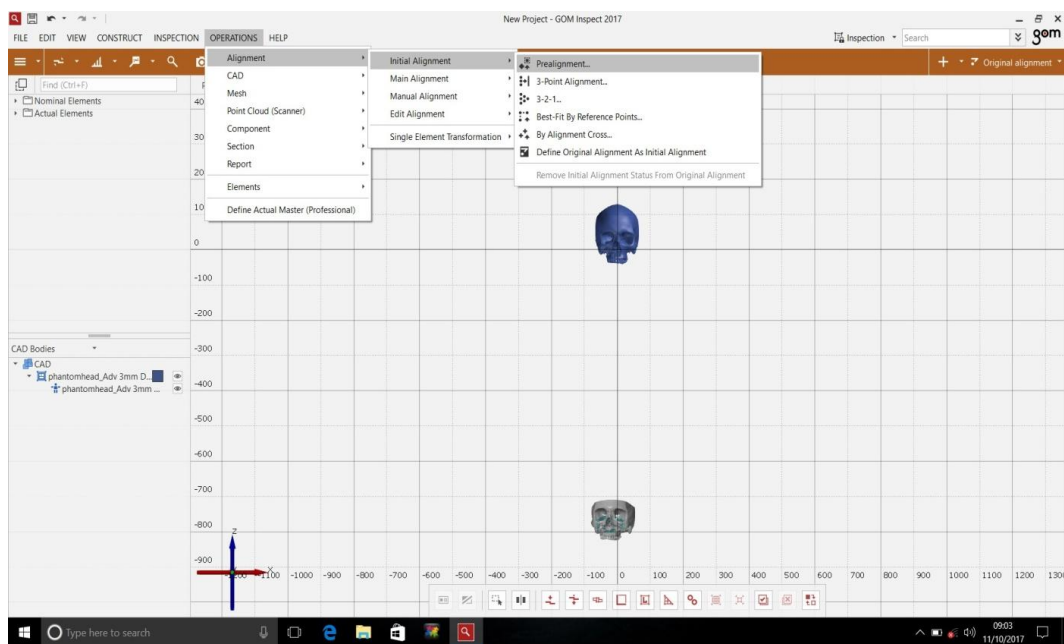
The data for all forty-three cases consisted of two sets of STL files; the first file provided the CAD skull with the maxilla in the planned surgical position (planned skull) and the second file was the GOM ATOS scan of the skull with the maxilla repositioned using the custom made anatomical guide (physical skull). Each of these two files was imported into the GOM Inspect software.

Superimposition of the two skulls was firstly performed by using the initial pre alignment tool (Fig 3.10.1) and then further refined using main alignment tool

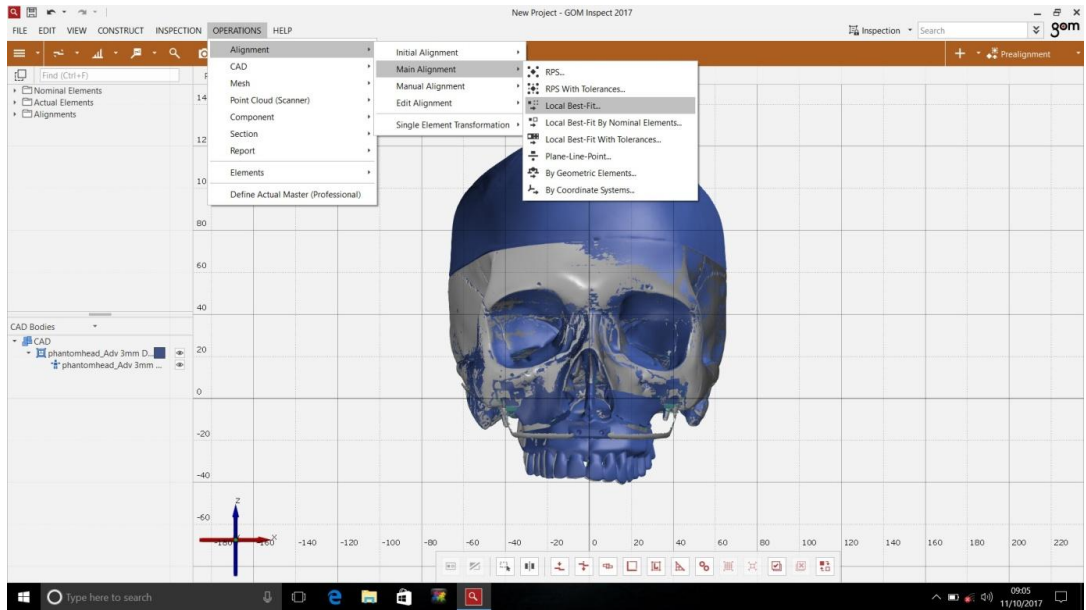


(Fig 3.10.2). The main alignment used Iterative Closest Point (ICP) also described as “local best fit”.

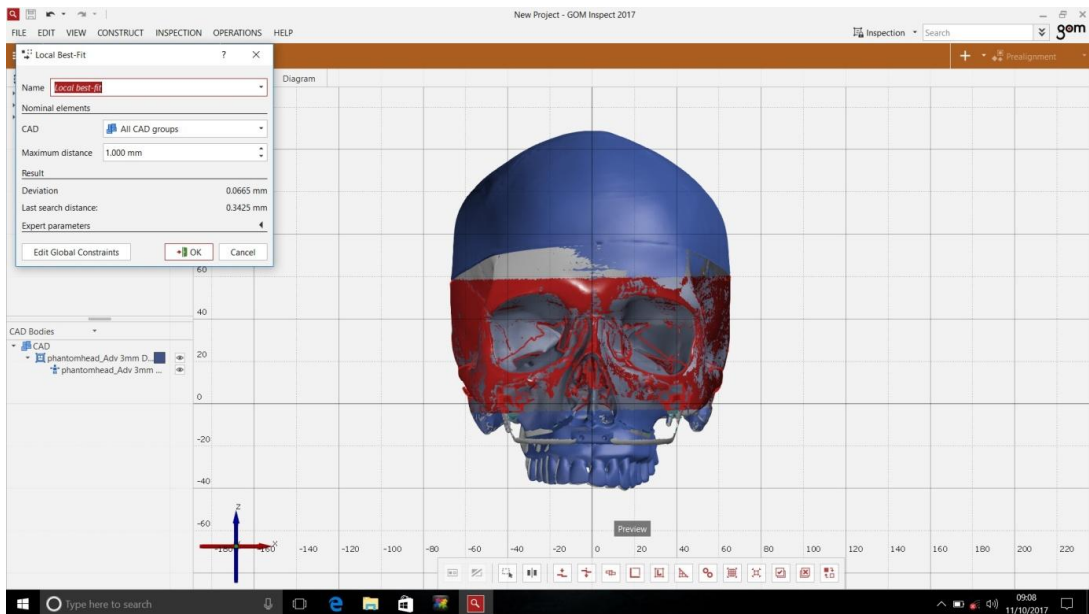
The skull vault, excluding the maxilla, was highlighted and selected for local best fit as this prevented the software from trying to align the dentition of both the skulls and producing erroneous results (Fig 3.10.3).



**Figure 3.10.1 CAD skull model and physical scanned skull model imported into GOM Inspect software and initially aligned**



**Figure 3.10.2 Main alignment performed showing the CAD skull and the physical skull superimposed**



**Figure 3.10.3 "Local Best Fit" was performed by selecting only the skull vault excluding the dentition for further alignment**

### 3.11 Digitisation of the Anatomical Landmarks

A reproducible set of anatomical points were digitized on the planned skull vault and replicated on the corresponding physical skull. There were twelve points positioned for each skull: six points on the skull vault (Fig 3.11.1) and six positioned on the occlusal surface of maxilla (Fig 3.11.2) as described on (Table 3.11.1). All twelve points were individually digitized for each set of the forty-three osteotomy movements. Each of the points provided X, Y and Z that was used to validate the accuracy of the position of the maxilla using the custom made anatomical guide.

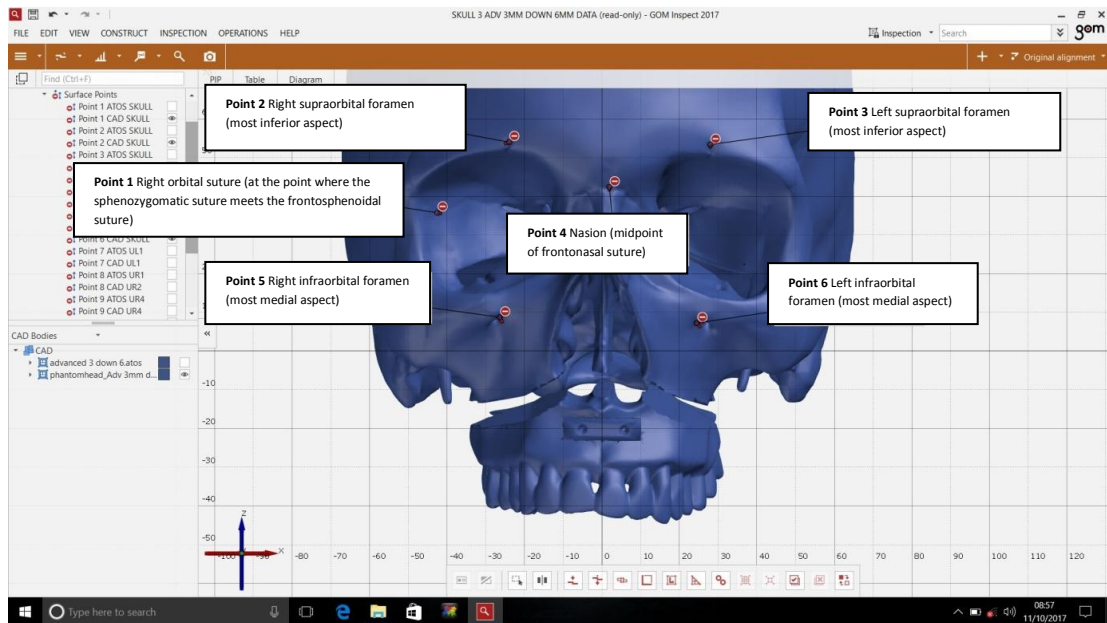
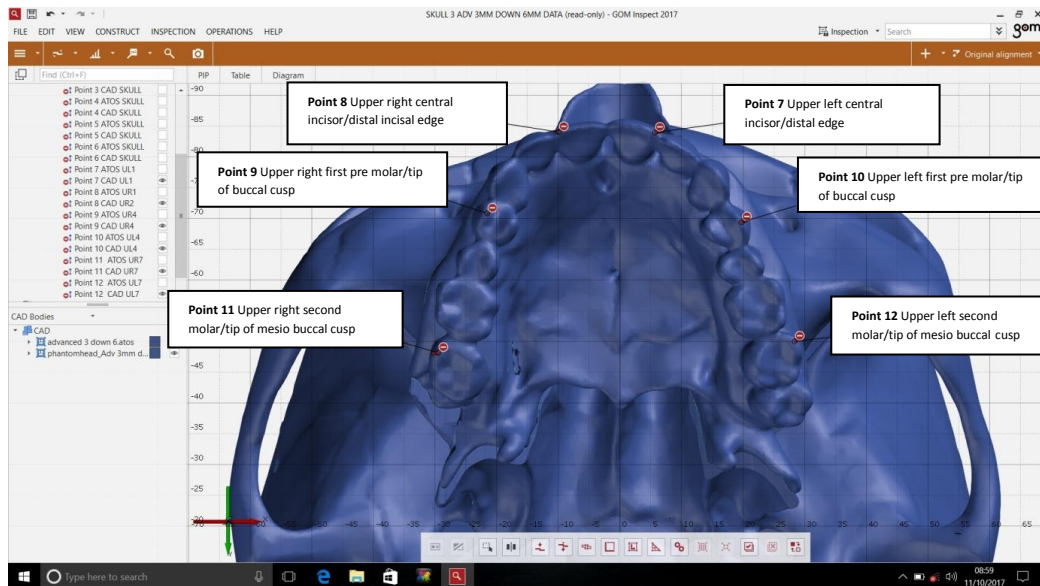


Figure 3.11.1 Six points digitised on anatomical landmarks of the skull vault



**Figure 3.11.2 Six point digitised on the maxillary occlusal surface of the selected teeth**

## Skull Vault landmarks

Skull Vault landmarking	
Point	Land marking definition
1	Right orbital suture (at the point where the sphenozygomatic suture meets the frontosphenoidal suture)
2	Right supraorbital foramen (most inferior aspect)
3	Left supraorbital foramen (most inferior aspect)
4	Nasion (midpoint of frontonasal suture)
5	Right infraorbital foramen (most medial aspect)
6	Left infraorbital foramen (most medial aspect)
Maxillary dentition landmarking	
7	Upper left central incisor/distal incisal edge
8	Upper right central incisor/distal incisal edge
9	Upper right first pre molar/tip of buccal cusp
10	Upper left first pre molar/tip of buccal cusp
11	Upper right second molar/tip of mesio buccal cusp
12	Upper left second molar/tip of mesio buccal cusp

**Table 3.11.1 Descriptions of the Twelve Landmarking Points on the Skull Vault and Maxillary Occlusal Surface of the Dentition**

### **3.12 Data Analysis**

In order to determine the accuracy of the superimposition and the landmarking of the laser scanned plastic skulls (physical skull) and those developed from digital planning in STL format (CAD skull), six anatomical landmarks on the skull vault were digitised on each set of images using the GOMinspect measurement analysis software programme. These were the points which were not affected by the surgical movements.

## 4.0 Results

### 4.1 Superimposition Accuracy of the Physical Skull and the CAD Skull

Six anatomical landmarks were digitised on the CAD skull vault and the same points were also marked on the physical skull vault using the GOMinspect measurement analysis software programme for all forty-three maxillary movements. The X, Y and Z coordinates were recorded for each anatomical landmark on the skull vault for both 3D skulls. The absolute distance between each corresponding landmark for all six anatomical points of the skull vault provided a measure of accuracy in the superimposition of the CAD skull and the physical skull.

The data was tested for normality using the Kolmogorov–Smirnov test and the results showed that the data was not normally distributed. Therefore a non parametric test was performed. Wilcoxon signed rank test was used to statistically evaluate the systematic error of the superimposition process. Table 4.1.1 shows the accuracy of the superimposition of the skull vault (the median absolute distance ranged from 0.09 to 0.58 mm). It should be noted that the superimposition error also included the landmarking error. However, the landmarking error was 0.30mm therefore the combined error of the landmarking and superimposition error was 1.0mm. The reported overall superimposition accuracy was 1.0mm. Table 4.1.2 shows the superimposition error and digitisation error in the X, Y and Z direction. Wilcoxon signed rank test was used to statistically evaluate the data for an accuracy of 0.5mm and also 1mm, the results reported that the superimposition error was

accurate to 0.5mm in the X, Y and Z direction for landmark points 1-5 however, the accuracy of the superimposition at point 6 was more than 0.5mm in the Y axis. The accuracy of the superimposition was within 1mm for all the points.

## Superimposition of the physical skull and the CAD skull

Distance differences between the combined x,y,z coordinates digitised on the skull vault of the CAD skull and the Physical skull	Point 1	Point 2	Point 3	Point 4	Point 5	Point 6
Mean	-0.03	-0.07	0.02	-0.02	0.22	-0.16
Std	0.21	0.12	0.18	0.15	0.32	0.70
Mean Absolute	0.22	0.12	0.18	0.15	0.92	0.95
Median	-0.05	-0.06	0.02	-0.06	0.12	0.09
Median Absolute	0.16	0.09	0.14	0.12	0.17	0.58
Wilcoxon signed rank test p-values	0.414	0.010	0.692	0.161	0.000	0.327
Statistical Significant	TRUE	FALSE	TRUE	TRUE	FALSE	TRUE
Wilcoxon signed rank (Left-tailed hypothesis test, where the alternative hypothesis states that the median of distance is less than the median of 1mm)						
P value	0.000	0.000	0.000	0.000	0.000	0.000
<1.0mm	TRUE	TRUE	TRUE	TRUE	TRUE	TRUE
P value	0.000	0.000	0.000	0.000	0.000	0.993
<0.5mm	TRUE	TRUE	TRUE	TRUE	TRUE	FALSE

**Table 4.1.1** The iteration error of the CAD skull and the physical skull when superimposed using GOMinspect software had an error of <1.0mm



## Superimposition Error in the X, Y and Z Coordinates

Point	1			2			3			4			5			6		
Axis	X	Y	Z	X	Y	Z	X	Y	Z	X	Y	Z	X	Y	Z	X	Y	Z
Mean	-0.22	0.03	-0.27	-0.14	0.22	0.14	-0.20	0.05	0.22	-0.19	0.15	0.25	0.12	-0.27	0.09	-0.05	0.16	0.11
Std	0.19	0.18	0.17	0.09	0.08	0.16	0.14	0.19	0.18	0.12	0.17	0.14	0.11	0.77	0.08	0.13	0.85	0.09
Mean absolute	0.24	0.15	0.27	0.15	0.23	0.17	0.20	0.16	0.23	0.19	0.20	0.25	0.13	0.35	0.10	0.11	0.74	0.11
Median	-0.21	0.03	-0.27	-0.15	0.22	0.16	-0.17	0.07	0.22	-0.21	0.19	0.23	0.12	-0.15	0.09	-0.07	-0.04	0.09
Median absolute	0.21	0.12	0.27	0.15	0.22	0.16	0.17	0.16	0.22	0.21	0.21	0.23	0.12	0.17	0.09	0.09	0.66	0.09
P value	0.000	0.211	0.000	0.000	0.000	0.000	0.000	0.070	0.000	0.000	0.000	0.000	0.000	0.000	0.000	0.003	0.273	0.000
Statistical significance	FALSE	TRUE	FALSE	FALSE	FALSE	FALSE	FALSE	TRUE	FALSE	FALSE	FALSE	FALSE	FALSE	FALSE	FALSE	FALSE	TRUE	FALSE
Wilcoxon signed rank (Left-tailed hypothesis test, where the alternative hypothesis states that the median of x y z is less than the median of 0.5mm or 1mm)																		
P value	0.000	0.000	0.000	0.000	0.000	0.000	0.000	0.000	0.000	0.000	0.000	0.000	0.000	0.000	0.000	0.000	0.000	0.000
<1 mm	TRUE	TRUE	TRUE	TRUE	TRUE	TRUE	TRUE	TRUE	TRUE	TRUE	TRUE	TRUE	TRUE	TRUE	TRUE	TRUE	TRUE	TRUE
P Value	0.000	0.000	0.000	0.000	0.000	0.000	0.000	0.000	0.000	0.000	0.000	0.000	0.000	0.000	0.000	0.0000	0.998	0.000
<0.5mm	TRUE	TRUE	TRUE	TRUE	TRUE	TRUE	TRUE	TRUE	TRUE	TRUE	TRUE	TRUE	TRUE	TRUE	TRUE	TRUE	FALSE	TRUE

**Table 4.1.2 Superimposition error in the X, Y and Z coordinates for the six points digitised on the skull vault of the CAD skull and the physical skull**

## **4.2 Landmarks Digitisation Errors**

Fifteen cases were selected at random and the twelve points were digitised at a one week interval. The data was analysed and confirmed to be normally distributed therefore a parametric test was performed. A one-sample t test determined the absolute distance between the corresponding landmarks of the first and second digitisation (Test 1 and Test 2) were measured and statistically evaluated. The average mean of the errors of the repeated digitisation of the set of landmarks was 0.30mm for the CAD skull and 0.22mm for the physical skull. Table 4.2.1 shows the mean, standard deviation, mean absolute value and the distance of the X, Y and Z coordinates for the CAD skull and the physical skull. The mean value in the Y axis was small but with a large standard deviation due to the data distribution being accurate but not precise.

## Reproducibility of Digitising the Anatomical Landmarks on the CAD Skull and the Physical Skull

	CAD Skull				Physical Skull			
Measurement	X Axis	Y Axis	Z Axis	Difference between Test 1 & Test 2	X Axis	Y Axis	Z Axis	Difference between Test 1 & Test 2
Mean	-0.02	-0.04	0.04	-0.05	-0.02	0.08	-0.00	-0.05
S.D	0.39	0.94	0.16	0.82	0.45	0.87	0.10	0.72
Absolute mean	0.17	0.31	0.10	0.30	0.17	0.24	0.06	0.22
One-sample t test on differences in the x,y,z and absolute mean distance	0.45	0.61	0.00	0.38	0.52	0.21	0.95	0.34
No statistical significance	TRUE	TRUE	FALSE	TRUE	TRUE	TRUE	TRUE	TRUE

**Table 4.2.1 Reproducibility of digitisation of anatomical landmarks on the CAD and physical skull**

TRUE means there is no statistical significance

FALSE means there is statistical significance

Human error in the reproducibility of digitising the anatomical landmarks on the CAD skull was accurate to 0.30 and on the scanned image of the physical skull is 0.22mm.

Although the Z axis failed the statistical test on the CAD skull, it must be noted that the mean absolute was small.

### **4.3 The Accuracy in Maxillary Repositioning using the Custom Made Anatomical Guide**

The accuracy of the anatomical guide in repositioning the maxilla in the planned position was evaluated. The difference between the six points on the maxillary dentition in the X, Y and Z coordinates of the physical skull and the CAD skull was measured. The data was tested for normal distribution and was found to be not normal, therefore a non-parametric test was performed. The mean absolute distance was tested using Wilcoxon signed rank test which showed that the overall error of positioning the maxilla guided by the custom-made guide was 2.25mm. This included the superimposition errors, the landmark digitisation errors and the positioning errors of the maxilla. The largest positioning error measured at point 12 in the z direction was 2.25mm however, the X, Y and Z coordinates from points 7 – 11 were accurate to 1.5mm. Table 4.3.1 shows the results of the positioning error of the maxilla when utilising the custom made anatomical repositioning guide.

## Occlusal Surface Mean and Median Values of the Physical Skull Compared with CAD Skull

Point	7			8			9			10			11			12			
Axis	X	Y	Z	X	Y	Z	X	Y	Z	X	Y	Z	X	Y	Z	X	Y	Z	
Mean	-0.81	1.04	-0.40	-0.83	1.25	-0.27	-0.70	1.20	0.91	-0.76	0.18	-0.13	-0.10	0.17	0.89	0.44	0.93	2.24	
Std	0.45	0.97	0.27	0.42	0.81	0.25	0.39	0.86	0.57	0.37	0.96	0.41	0.43	0.85	0.85	0.50	0.77	1.22	
mean Absolute values	0.85	1.16	0.43	0.84	1.28	0.32	0.72	1.27	0.96	0.76	0.80	0.36	0.36	0.70	0.99	0.52	1.00	2.25	
Median	-0.79	1.12	-0.42	-0.84	1.35	-0.27	-0.7	1.26	1.01	-0.72	0.21	-0.15	-0.08	0.19	0.86	0.33	0.95	2.36	
median Absolute values	0.81	1.21	0.42	0.84	1.35	0.29	0.70	1.26	1.01	0.72	0.74	0.40	0.31	0.67	0.90	0.45	0.95	2.36	
Wilcoxon signed rank (Left-tailed hypothesis test, where the alternative hypothesis states that the median of x,y and z is less than the median of 1.5mm)Left-tailed hypothesis test.																			
Statistically significant	FALSE	FALSE	FALSE	FALSE	FALSE	FALSE	FALSE	FALSE	FALSE	FALSE	TRUE	FALSE	TRUE	TRUE	FALSE	FALSE	FALSE	FALSE	
P value	0.000	0.006	0.000	0.000	0.032	0.000	0.000	0.028	0.000	0.000	0.000	0.000	0.000	0.000	0.000	0.000	0.000	0.999	
<1.5mm	TRUE	TRUE	TRUE	TRUE	TRUE	TRUE	TRUE	TRUE	TRUE	TRUE	TRUE	TRUE	TRUE	TRUE	TRUE	TRUE	TRUE	TRUE	FALSE

**Table 4.3.1 X, Y and Z mean and median values of each digitised point on the occlusal surface of the maxillary dentition of the physical skull compared with the CAD skull**

## 5.0 Discussion

The primary aim of this pilot study was to design, validate and determine the accuracy of using a custom made anatomical repositioning surgical guide for repositioning the maxilla independently of the mandible during a Le Fort I osteotomy.

Current methods of maxillary repositioning require conventional orthognathic surgery planning using a semi-adjustable articulator and face-bow system. There is an abundance of literature suggesting these planning methods have inherent anatomical inaccuracies that can be transferred to the surgical repositioning of the maxilla. These manifest as unwanted movements that are not visible during the planning stages (Walker et al., 2008).

On completion of the model surgery planning, surgical splints are commonly manufactured using polymethyl methacrylate (PMMA) cold cure acrylic resin. The PMMA is formed and placed between the upper and lower occlusion of the articulated dental casts in the intermediate and final planned positions. The two occluding dental surfaces create indentations in the PMMA that when allowed to set produce a surgical positioning splint, the splint is then trimmed ready for use in the surgical environment. Orthognathic surgery planning is executed with the patient sitting in an upright position, fully awake. The process follows this protocol from initial consultation within the dento-facial planning clinic through to face-bow recording and splint try-in prior to surgery. As previously mentioned, model surgery

planning has the potential to introduce surgical errors and recommendations have been offered to minimise these (Gonzalez and Kingery, 1968; Ellis III et al., 1992; O'Malley et al., 2000; Walker et al., 2008). However, until recent times there is one factor that has not been a major focus during the planning stage of orthognathic surgery. During Le Fort I orthognathic procedure the maxilla is surgically separated from the skull, the wafer is placed between the occlusal surfaces of the upper and lower dentition and fixed in position using loops made up of 0.5mm stainless steel wire. To ensure the correct occlusion and prescribed amount of maxillary advancement is achieved, the maxillo-mandibular complex is auto-rotated until the required maxillary vertical height is produced. The entire surgical procedure is undertaken with the patient anaesthetised while in the supine position which introduces errors in maxillary repositioning. Boucher et al., (1961) reported that the relaxed mandible of an anaesthetised patient in the supine position could be unintentionally retruded into the glenoid fossa by up to 2mm due to loss of muscle tone. This physiological response to general anaesthesia can have a profound influence on the correct amount of maxillary advancement required.

The expertise and visual judgement of the surgeon is relied upon to foresee and eliminate this potential source of error. However, this may not be possible to achieve in all cases, therefore there is a need for a device to guide the surgical position of the maxilla independent of the mandibular dentition.

This study was undertaken in the attempt to eliminate the requirement of using the mandible to guide the maxilla during surgery. 3D technology has expanded the

parameters on how orthognathic surgery planning is predicted and the freedom to design more advanced methods of guiding the maxilla during surgery.

A literature search of previous attempts to position the maxilla using a custom made guide highlighted that there is limited robust evidence on the accuracy of re positioning the maxilla independent of the mandible. The published articles mainly consisted of single case studies and therefore could not provide statistical evidence on the accuracy of the presented devices (Polley et al., 2013; Kang et al., 2014; Lee at al., 2015). Two studies investigated the accuracy of anatomically repositioning the maxilla using various methods. Zinser et al., (2012) reported an accuracy of 0.23mm. Shehab et al., (2013) repositioned the maxilla vertically with an accuracy of 1mm in five out of six cases, and horizontally to within 1mm in four out of six cases.

Several studies suggested methods of repositioning the maxilla with the use of patient specific custom made titanium bone plates. The plates are laser sintered and anatomically shaped in a manner that would place the maxilla in the final position during surgery (Gander et al., 2015; Brunso et al., 2016). The process of laser sintering is financially non viable for many institutions, and until such times the cost of this process is reduced other methods must be sought.

The advent of new technologies has provided the opportunity to improve and develop new techniques of orthognathic surgery planning and surgical wafer construction. 3D planning negates the need for articulator systems and eliminates their inherent inaccuracies. Although this is a quantum leap in the quest for



accurate surgical planning, virtual planning methods still display sources of potential error. It has been proven that the CBCT scan of the skull and teeth distort and magnify the dentition, therefore they must be replaced within the virtual environment using the laser or CBCT scanned images of the dentition of the upper and lower dental stone models. This process is completed using a best fit method within the software programmes. Specific iterative closest point algorithms are written into the software to surface match the dentition of the scanned patient to that of the scanned dental casts (O'Neil et al., 2012; Nairn et al., 2013). This surface matching process can be difficult to achieve due to streak artefact present as a result of amalgam restorations and orthodontic brackets. A more accurate replacement of the virtual dentition could be achieved with the use of a fiducial marker system, whereby markers are placed on the orthodontic brackets of the teeth at time of impression taking or scanning with an intraoral laser scanner. The CBCT would also capture the markers allowing the fiducial markers to be the point of image registration within the software package (Nairn et al., 2013; Yang et al., 2015; Almutairi et al., 2018). This would eliminate the need to rely on distorted dental anatomy.

On completion of the dentition replacement, orthognathic planning is performed using a 3D planning software programme which allows the upper and lower jaws to be moved to the desired positions to restore facial harmony. Surgical wafers are then designed around the new jaw positions and rapid prototyped using a 3D printer. Although this technology is ever-advancing, the surgery is still executed

using a surgical wafer to reposition the jaws. This crucial stage is still reliant on the relaxed mobile mandible of the anaesthetised patient to guide the maxilla into the planned surgical position.

## **5.1 Error of the Method**

### **5.1.1 Anatomical Resin Skull**

A single synthetic resin anatomical skull was selected for the study as it was considered physically robust and anatomically accurate to design and validate the concept of repositioning the maxilla with the use of a custom made anatomical surgical guide. A test CT scan with a slice width of 0.5mm proved the skull could produce a 3D virtual image that could be utilised for the study.

The advantage of a resin skull ensured there was no streak artefact produced during scanning therefore eliminating distortion that may have a negative impact on the accuracy of the method. On reflection, amalgam restorations and dental brackets could have been incorporated into the skull, producing a truer representation of an average patient seen within the clinical setting. However, this study was conducted mainly to test the hypothesis that the newly developed guide can reposition the maxilla, which is separated from the skull at Le Fort I level accurately to 0.5mm.

### **5.1.2 Image Capture of the Skull**

Image capture of the resin skull was completed using a helical CT scanner as it was readily available in the department and provided the volumetric data needed for the study. To project a more realistic overview of the study, a CBCT scan could be

obtained to capture the data. Once more, a CT scan was chosen to maximise the accuracy of the 3D planning of the skull and allow the researcher to focus on the errors related to the design of the guide and its reliability to reposition the maxillary segment.

### **5.1.3 DICOM Data Imported in 3D Software Package**

The DICOM data was imported into Mimics Innovation suite 19.0 (Materialise Medical Software, Leuven, Belgium) and converted to an STL file format which enabled the maxilla to be separated from the cranial base and moved in six degrees of freedom in the virtual environment. It has to be expressed that Mimics was not designed for orthognathic surgery planning. This particular software was the only medically licensed 3D programme within the department which enabled the maxilla to be repositioned using the “repositioning” tool within the software and allowed the images to be freely exported and imported as STL files. These attributes were crucial for the design of the custom made anatomical surgical guide.

Further research should utilise a dedicated 3D orthognathic planning software programme such as Dolphin 3D Surgery Software (Dolphin Imaging and Management Solutions, Chatsworth, USA), ProPlan CMF (Materialise Medical Software, Leuven, Belgium) and IPS CaseDesigner (KLS Martin, Freiburg, Germany). An advantage of using a dedicated 3D planning software programme is that it would allow the magnified dentition to be accurately replaced within the software programme. The 3D manipulation software programme used in this study did not

allow for the replacement of the dentition, however, this was not deemed necessary as the anatomical repositioning guide did not rely on the dentition for moving the maxilla. Future research would benefit from replacing the dentition during the surgical planning stage. The design of the guide could incorporate the teeth to provide posterior support of the maxilla and to allow the mandible to be repositioned in the case of a bi-maxillary procedure.

#### **5.1.4 Maxillary Surgical Movements**

Forty-three Le Fort I orthognathic movements were specified to replicate a broad spectrum of surgical movements commonly performed in corrective jaw surgery as shown in table 4.2.1. These ranged from simple maxillary advancements to complex combined movements that incorporated advancements with altered pitch, roll and yaw. This tested the accuracy of the guide in positioning the maxilla to the planned position in a range of small movements to the upper limits of the possible surgical movements. The developed guide had a mean absolute positioning error of 2.25mm. This included both the landmark digitisation errors and the inaccuracies associated with the superimposition of 3D images. Although the overall mean absolute positioning error was reported at 2.25mm, it has to be noted that the guide was accurate to within 1.5mm in the X, Y and Z direction in points seven to eleven and also at point twelve in the X and Y direction. An accuracy of 2.25mm was noted at point twelve in the Z direction as shown in table 4.3.1. Further research would be required to ascertain the reasons for the inaccuracies of the guide.

The prerequisite of the custom made surgical guide was that it did not rely on the mandible to guide the maxilla into the final position. The guide must allow for ease of removal multiple times during surgery to allow for bone remodelling and to achieve correct vertical height changes.

## **5.2 Initial Design of the Custom Made Anatomical Repositioning Guide**

Within this body of research, the initial design concept of the custom made anatomical repositioning guide evolved. The first design was a unified design consisting of two guides: the preoperative drill and positioning guide and the postoperative repositioning guide. The unified guide displayed a marginally greater degree of stability due to the absence of joints within the component structure. However, the disadvantage of not having a removable framework would necessitate the need to repeatedly remove the entire guide preoperatively. Repetitive removal of titanium bone screws may result in widening of the screw holes on the area of the zygomaxillary bone and at the area inferior to the anterior nasal spine where each of the locating plates was fixed, thus providing a potential area of positioning error.

In this study separate locating plates were introduced and the framework was attached with the use of a single 0.5kg pull neodymium magnet on each of the zygoma plates and on the corresponding pre and postoperative framework. The magnets allowed the zygoma plates to be fixed onto the defined area of the zygomaxillary bone and remain in situ, while providing retention and ease of

removal of the framework. Surgery would be kept to a minimum as the surgeon would not have to remove the entire guide from the patient as the locating plates remained in-situ until the surgical procedure was complete.

It was evident that by incorporating a joint within the design it introduced flexibility that was seen when moderate forces were applied. The maxilla could be displaced vertically and posteriorly when fixed in position using the guide. This was responsible for the errors that were detected on the maxillary posterior segment in the vertical direction.

The design of the pre and postoperative framework evolved with the addition of two magnets on each of the zygoma plates and on the opposing framework. The extra magnetic retention reduced the amount of displacement when forces were applied to the guide. Cyanoacrylate glue (Loctite Precision) was selected due to its low viscosity and therefore reduces inaccurate placement of the magnets. The magnet manufacturer recommended this particular brand of glue for optimal adhesion of the magnets to the opposing surface. However, for the guide to be utilised in a clinical setting, a CE marked bonding agent for the retention of the magnets would have to be sourced. Magnets were the preferred method of retention as they could be easily incorporated into the limited space of the CAD/CAM designed framework. They provided adequate retention between the removable components of the guide without posing difficulty in intentional separation by the operator.

### 5.3 Study Results

The results reported in this study that the errors in repositioning the maxilla in the planned position using the anatomical repositioning guide had a mean absolute error of 2.25mm. The largest positioning error was observed at point twelve in the Z direction at 2.25mm however, the X, Y and Z coordinates from points seven to eleven were accurate to within 1.5 mm. The guide had a tendency to under-advance the maxilla, placing it in a more retruded antero-posterior plane. It was also observed that the maxilla moved upwards posteriorly to a greater magnitude than that of the planned position.

On evaluation, there are several factors that had an adverse effect on the correct placement of the maxilla using the guide. This includes the superimposition error and landmarking error. Superimposition of the CAD skull and the physical skull image was performed using surface iteration, whereby the software programmes have a specific algorithm to best match the two surfaces, the iteration error was 1mm. There was an obvious difference between the CT and the GOM scanned image, the CT scanned imaged appeared magnified when compared to the GOM scan. This would have had an effect on the accuracy of the iteration process due to the inaccuracy of aligning the two skull surfaces. The scanning of the skull should have been standardised and executed using only one type of scanner to eliminate inherent discrepancies between the scans. Image thresholding may have contributed to the magnification of the CT scanned skull during the conversion from DICOM data to STL format to produce the 3D image of the skull. The threshold value

was set to capture bone at a range of 226-3071. The physical skull was made from plastic resin therefore consideration was taken to select a threshold value that did not produce noise artefact nor reduce the surface detail of the 3D image. A visual inspection was the method used to observe the quality of the image through varying threshold values.

Reproducibility of landmarking was carried out on fifteen randomly selected movements. The human error in digitising the twelve landmarks, six on the skull vault and six on the occlusal surface of the teeth was reported to be accurate to 0.22mm on the physical skull and to 0.30mm on the CAD skull with a mean absolute accuracy of 0.30mm. Accurately digitising the twelve landmarks was difficult due to the differences in anatomical detail observed between the two skulls. This was evident throughout the study on points 5 and 6 on the infra-orbital foramen; the perception of depth was difficult to interpret resulting in the inability to accurately replicate the correct Y dimension due to the lack of surface texture on the 3D images. The landmarking error may have been reduced by adding surface texture to the images allowing the exact anatomical point to be identified more accurately each time.

The errors in evaluation could be partially due to the method of scanning the guide when attached to the skull and maxillary process. When placed in the GOM scanner the skull had the crown of the cranium removed. This was then placed on the scanner table with the maxilla in a superior position (Fig 3.9.2). As a result of the maxilla having been separated from the skull at Le Fort I level this could have had an



adverse effect on the accurate placement of the maxilla using the prototype guide due to gravitational pull on the unsupported posterior aspect of the maxilla. As the maxilla was only fixed to the guide at the anterior nasal spine, there may have been a possibility for the maxilla to drop posteriorly during scanning. If this was the case it would account for the anterior teeth retroclining and the posterior height being reduced when the skull is returned to the NHP. In retrospect, a framework that held the skull in an upright position could have been used during the GOM scanning process. A design modification of the guide could be explored with the addition of two extra struts. These would support the maxilla buccally on either side to reduce unwanted posterior movement as the guide would not solely be fixed in position at one anterior point. Further research would need to be carried out to assess the accuracy error in positioning the maxilla.

Deformation of the 3D printed guides could have had an effect of the correct positioning of the maxilla due to dimensional changes within the structure over a period of time post printing. This however is theoretical and non justified and further research would need to be carried out on the dimensional stability of the post cured resin to validate this theory.

The accuracy of the developed repositioning guide is dissimilar to the previous published data. Zinser et al., (2012) reported on eight cases in which the maxilla was positioned with an accuracy of 0.23mm. Shehab et al., (2013) showed the maxilla could be accurately positioned vertically (five of six cases) equal to or less than 1mm and horizontally (four of six cases) within 1mm.

The results of Zinser et al., (2012) and Shehab et al., (2013) report greater accuracies in repositioning the maxilla however, the sample sizes in both studies were small n=8 and n=6 respectively compare to n=42 in our study. The larger sample size in this study provided more data over a greater number of cases which produce a wider spectrum of potential sources of error in using the guide to reposition the maxilla.

## 6.0 Conclusion

This study highlighted the possible improvement in the accuracy of positioning the maxilla peroperatively without the guidance of the mandibular occlusion. At present this can be achieved with an overall positioning accuracy of 2.25mm when using the developed maxillary repositioning guide. This level of accuracy is clinically significant and therefore cannot be utilised to reposition the maxilla. The aim was to achieve an accuracy of 0.5mm and therefore a review of the design of the guide will be considered. In addition, the methodology of this study could be improved to further reduce the errors of the custom made anatomical repositioning guide. Modifications of the guide are required to provide the separated maxilla with greater posterior support to achieve a repositioning accuracy of 0.5mm. This will then be tested clinically on a selected group of patients before conducting a multi-centre randomised clinical trial.

## 7.0 REFERENCES

- Aboul-Hosn Centenero, S. & Hernández-Alfaro, F. 2012, "3D planning in orthognathic surgery: CAD/CAM surgical splints and prediction of the soft and hard tissues results – Our experience in 16 cases", *Journal of Cranio-Maxillofacial Surgery*, vol. 40, no. 2, pp. 162-168.
- Almutairi, T., Naudi, K., Nairn, N., Ju, X., Whitters, J. & Ayoub, A. 2018, Replacement of the Distorted Dentition of the Cone-Beam Computed Tomography Scans for Orthognathic Surgery Planning. *Journal of Cranio-Maxillofacial Surgery*, 2012, 40, 2, 162-168.
- Bai, S., Bo, B., Bi, Y., Wang, B., Zhao, J., Liu, Y., Feng, Z., Shang, H. & Zhao, Y. 2010, "CAD/CAM surface templates as an alternative to the intermediate wafer in orthognathic surgery", *Oral Surgery, Oral Medicine, Oral Pathology, Oral Radiology, and Endodontology*, vol. 110, no. 5, pp. e1-e7.
- Bai, S., Shang, H., Liu, Y., Zhao, J. & Zhao, Y. 2012, "Computer-Aided Design and Computer-Aided Manufacturing Locating Guides Accompanied With Prebent Titanium Plates in Orthognathic Surgery", *Journal of Oral and Maxillofacial Surgery*, vol. 70, no. 10, pp. 2419-2426.
- Bamber, M.A., Firouzai, R., Harris, M. & Linney, A. 1996, A comparative study of two arbitrary face-bow transfer systems for orthognathic surgery planning. *International Journal of Oral and Maxillofacial Surgery*, 1996, 25, 5, 339-343.
- Boucher, L. & Jacoby, J. 1961, Posterior border movements of the human mandible. *The Journal of Prosthetic Dentistry*, 1961, 11, 5, 836-841.
- Brunso, J., Franco, M., Constantinescu, T., Barbier, L., Santamaría, J.A. & Alvarez, J. 2016, "Custom-Machined Miniplates and Bone-Supported Guides for Orthognathic Surgery: A New Surgical Procedure", *Journal of Oral and Maxillofacial Surgery*, vol. 74, no. 5, pp. 1061.e1-1061.e12.
- C.F.A. Moorrees, R.K. 1958, "Natural head position: a basic consideration in the interpretation of cephalometric radiographs", *Am J Phys Anthropol*, vol. 16, pp. 213-234.
- Cassi, D., De Biase, C., Tonni, I., Gandolfini, M., Di Blasio, A. & Piancino, M.G. 2016, Natural position of the head: review of two-dimensional and three-dimensional methods of recording. *British Journal of Oral and Maxillofacial Surgery*, 2016, 54, 3, 233-240.
- Down William B. 1956, "Analysis of dentofacial profile. *Angle orthodontist*, vol. 26, no. 4, pp. 191-212.

- Ellis III, E., Tharanon, W. & Gambrell, K. 1992, "Accuracy of face-bow transfer: Effect on surgical prediction and postsurgical result", *Journal of Oral and Maxillofacial Surgery*, vol. 50, no. 6, pp. 562-567.
- Gander, T., Bredell, M., Eliades, T., Rücker, M. & Essig, H. 2015, "Splintless orthognathic surgery: A novel technique using patient-specific implants (PSI)", *Journal of Cranio-Maxillofacial Surgery*, vol. 43, no. 3, pp. 319-322.
- Gateno, J., Xia, J.J. & Teichgraeber, J.F. 2011, Effect of Facial Asymmetry on 2-Dimensional and 3-Dimensional Cephalometric Measurements. *Journal of Oral and Maxillofacial Surgery*, 2011, 69, 3, 655-662.
- Gonzalez JB, K.R. 1968, "Evaluation of planes of references for orienting maxillary casts on articulators.", *J Am Dent Assoc*, vol. 76, pp. 329-336.
- Hoffman, G.R. & Brennan, P.A. 2004, "The skeletal stability of one-piece Le Fort 1 osteotomy to advance the maxilla: Part 1. Stability resulting from non-bone grafted rigid fixation", *British Journal of Oral and Maxillofacial Surgery*, vol. 42, no. 3, pp. 221-225.
- Hsu, S.S., Gateno, J., Bell, R.B., Hirsch, D.L., Markiewicz, M.R., Teichgraeber, J.F., Zhou, X. & Xia, J.J. 2013, "Accuracy of a Computer-Aided Surgical Simulation Protocol for Orthognathic Surgery: A Prospective Multicenter Study", *Journal of Oral and Maxillofacial Surgery*, vol. 71, no. 1, pp. 128-142.
- Jones, R.M., Khambay, B.S., McHugh, S. & Ayoub, A.F. 2007, The validity of a computer-assisted simulation system for orthognathic surgery (CASSOS) for planning the surgical correction of class III skeletal deformities: single-jaw versus bimaxillary surgery. *International Journal of Oral and Maxillofacial Surgery*, 2007, 36, 10, 900-908.
- Kang, S., Kim, M., Kim, B.C. & Lee, S. 2014, "Orthognathic Y-splint: a CAD/CAM-engineered maxillary repositioning wafer assembly", *British Journal of Oral and Maxillofacial Surgery*, vol. 52, no. 7, pp. 667-669.
- Lee, U., Kwon, J. & Choi, Y. 2015, "Keyhole System: A Computer-Assisted Designed and Computer-Assisted Manufactured Maxillomandibular Complex Repositioner in Orthognathic Surgery", *Journal of Oral and Maxillofacial Surgery*, vol. 73, no. 10, pp. 2024-2029.
- McClure, S.R., Sadowsky, P.L., Ferreira, A. & Jacobson, A. 2005, Reliability of Digital Versus Conventional Cephalometric Radiology: A Comparative Evaluation of Landmark Identification Error. *Seminars in Orthodontics*, 2005, 11, 2, 98-110.
- Moorrees, C. F. A. & Kean, M. R. "Natural Head Position, a basic consideration in the interpretation of cephalometric radiographs. *American Journal of Physical Anrhropology*, 16, 213.

- Nairn, N.J., Ayoub, A.F., Barbenel, J., Moos, K., Naudi, K., Ju, X. & Khambay, B.S. 2013, "Digital replacement of the distorted dentition acquired by cone beam computed tomography (CBCT): a pilot study", *International journal of oral and maxillofacial surgery*, vol. 42, no. 11, pp. 1488-1493.
- O'Malley, A.M. & Milosevic, A. 2000, "Comparison of three facebow/semi-adjustable articulator systems for planning orthognathic surgery", *British Journal of Oral and Maxillofacial Surgery*, vol. 38, no. 3, pp. 185-190.
- O'Neil, M., Khambay, B., Moos, K.F., Barbenel, J., Walker, F. & Ayoub, A. 2012, "Validation of a new method for building a three-dimensional physical model of the skull and dentition", *British Journal of Oral and Maxillofacial Surgery*, vol. 50, no. 1, pp. 49-54.
- Pitchford, J.H. 1991, A reevaluation of the axis-orbital plane and the use of orbitale in a facebow transfer record. *The Journal of Prosthetic Dentistry*, 1991, 66, 3, 349-355.
- Polley, J.W. & Figueroa, A.A. 2013, "Orthognathic Positioning System: Intraoperative System to Transfer Virtual Surgical Plan to Operating Field During Orthognathic Surgery", *Journal of Oral and Maxillofacial Surgery*, vol. 71, no. 5, pp. 911-920.
- Sandham, A. 1988, "Repeatability of Head Posture Recordings from Lateral Cephalometric Radiographs", *British journal of orthodontics*, vol. 15, no. 3, pp. 157-162.
- Sharifi, A., Jones, R., Ayoub, A., Moos, K., Walker, F., Khambay, B. & McHugh, S. 2008, "How accurate is model planning for orthognathic surgery?", *International journal of oral and maxillofacial surgery*, vol. 37, no. 12, pp. 1089-1093.
- Shehab, M.F., Barakat, A.A., AbdElghany, K., Mostafa, Y. & Baur, D.A. 2013, "A novel design of a computer-generated splint for vertical repositioning of the maxilla after Le Fort I osteotomy", *Oral Surgery, Oral Medicine, Oral Pathology and Oral Radiology*, vol. 115, no. 2, pp. e16-e25.
- Shqaidef, A., Ayoub, A.F. & Khambay, B.S. 2014, "How accurate are rapid prototyped (RP) final orthognathic surgical wafers? A pilot study", *British Journal of Oral and Maxillofacial Surgery*, vol. 52, no. 7, pp. 609-614.
- Swennen, G.R.J., Barth, E.-., Eulzer, C. & Schutyser, F. 2007, The use of a new 3D splint and double CT scan procedure to obtain an accurate anatomic virtual augmented model of the skull. *International Journal of Oral and Maxillofacial Surgery*, 2007, 36, 2, 146-152.
- Tucker, S., Cevidane, L.H.S., Styner, M., Kim, H., Reyes, M., Proffit, W. & Turvey, T. 2010, "Comparison of Actual Surgical Outcomes and 3-Dimensional Surgical Simulations", *Journal of Oral and Maxillofacial Surgery*, vol. 68, no. 10, pp. 2412-2421.

- Walker, F., Ayoub, A.F., Moos, K.F. & Barbenel, J. 2008, "Face bow and articulator for planning orthognathic surgery: 1 face bow", *British Journal of Oral and Maxillofacial Surgery*, vol. 46, no. 7, pp. 567-572.
- Xia, J.J., Gateno, J., Teichgraeber, J.F., Christensen, A.M., Lasky, R.E., Lemoine, J.J. & Liebschner, M.A.K. 2007, "Accuracy of the Computer-Aided Surgical Simulation (CASS) System in the Treatment of Patients With Complex Craniomaxillofacial Deformity: A Pilot Study", *Journal of Oral and Maxillofacial Surgery*, vol. 65, no. 2, pp. 248-254.
- Yang, W., Ho, C. & Lo, L. 2015, Automatic Superimposition of Palatal Fiducial Markers for Accurate Integration of Digital Dental Model and Cone Beam Computed Tomography. *Journal of Oral and Maxillofacial Surgery*, 2015, 73, 8, 1616.e1-1616.e10
- Ying, B., Ye, N., Jiang, Y., Liu, Y., Hu, J. & Zhu, S. 2015, "Correction of facial asymmetry associated with vertical maxillary excess and mandibular prognathism by combined orthognathic surgery and guiding templates and splints fabricated by rapid prototyping technique", *International journal of oral and maxillofacial surgery*, vol. 44, no. 11, pp. 1330-1336.
- Zinser, M.J., Mischkowski, R.A., Dreiseidler, T., Thamm, O.C., Rothamel, D. & Zöller, J.E. 2013, "Computer-assisted orthognathic surgery: waferless maxillary positioning, versatility, and accuracy of an image-guided visualisation display", *British Journal of Oral and Maxillofacial Surgery*, vol. 51, no. 8, pp. 827-833.
- Zinser, M.J., Mischkowski, R.A., Sailer, H.F. & Zöller, J.E. 2012, "Computer-assisted orthognathic surgery: feasibility study using multiple CAD/CAM surgical splints", *Oral Surgery, Oral Medicine, Oral Pathology and Oral Radiology*, vol. 113, no. 5, pp. 673-687.

# 8.0 APPENDICES

## 8.1 Glossary

<b>3D</b>	Three dimensional
<b>Antero-Posterior</b>	Concerned with or extending along a direction or axis from front to back or from anterior to posterior.
<b>CAD Skull</b>	Computer-aided designed skull.
<b>CBCT</b>	Cone beam computed tomography.
<b>Curve of Spee</b>	Curve running from the condyle of the mandible along the superior surface of all mandibular teeth to the central incisors.
<b>Six Degrees of Freedom</b>	Six degrees of freedom (6DoF) refers to the freedom of movement of a rigid body in three-dimensional space.
<b>DICOM</b>	Digital Imaging and Communications in Medicine.

<b>Frankfort Horizontal Plane</b>	A plane passing through the left orbitale (most inferior point of the orbit) and the highest point of each external auditory meatus.
<b>Iterative Closest Point</b>	( <i>ICP</i> ) is an algorithm employed to minimize the difference between two clouds of points.
<b>Physical Skull</b>	Anatomically correct resin skull.
<b>PSIs</b>	Patient-specific implants.
<b>Semi-Adjustable Articulator</b>	A mechanical device to which plaster casts of the upper and lower dental arches are attached and which artificially reproduces recorded positions of the mandible in relation to the maxilla.
<b>Stereolithography</b>	Optical fabrication, photo-solidification, or resin printing is a form of 3-D printing technology used for creating models.
<b>STL</b>	Single tessellation language.
<b>Advancement</b>	To move forwards on a horizontal plane.
<b>Setback</b>	To move backwards in a horizontal plane.



**Impaction**

To move upwards in a vertical plane.

**Downgraft**

To move downwards in a vertical plane.

**X, Y and Z Axis**

3D coordinate system. X is left to right. Y is front to back and Z is up to down.