

**PAEDIATRIC HEART VALVE DISEASE  
AND TREATMENT:  
CURRENT STATUS AND FUTURE PERSPECTIVE  
ON THE NEED FOR BETTER VALVE  
REPLACEMENT TECHNOLOGIES**

---

Romilde Kotzé

MSc Bioengineering

September 2011-2012

## **DECLARATION**

This thesis is the result of the author's original research. It has been composed by the author and has not been previously submitted for examination which has led to the award of a degree

The copyright of this thesis belongs to the author under the terms of the United Kingdom Copyright Acts as qualified by University of Strathclyde Regulation 3.50. Due acknowledgement must always be made of the use of any material contained, in, or derived from, this thesis.

Signed:

Date:



## **ACKNOWLEDGEMENTS**

I would like to acknowledge my supervisor, Prof. Terence Gourlay without whom this thesis would not have been possible. Thank you for your patience and invaluable input in making this literature review possible.

## ABSTRACT

Valve repair is the treatment of choice for paediatric congenital heart valve disease, but valve replacement may still be necessary if repair strategies fail or if a valve is extensively damaged.(1) Paediatric-size heart valves available include biological, bioprosthetic and mechanical valves. These current valve replacement technologies still have significant limitations, including valve degeneration and dysfunction.(2) As a result, a patient may require numerous valve re-replacements. The need to 'redo' a valve replacement combined with the need for growth potential, over an individual's lifespan, are critical considerations in paediatric treatment strategies. Alternative approaches and solutions for valve substitutes need to be sought. The aim of this dissertation is therefore to compile a literature review of the currently available and newly emerging heart valve replacement technologies for paediatric use. The review identifies the paediatric population that may benefit from heart valve prostheses, the associated procedural complications, together with indications for valve replacement interventions. The limitations of such technologies are explored, focusing on reoperation rate, revision surgery, somatic growth and the potential to overcome the problems associated with intervention. Critical design outcomes are discussed, investigating questions relating to the selection of materials, device implantation or deployment and removal. The use of minimally invasive procedures, particularly catheter-based techniques, is looked at as an alternative to open heart surgery. This includes percutaneous valve replacement with the potential for valve-in-valve replacements. Finally, the future direction in which such technologies are likely to go are discussed, pointing out what areas further research should focus on in order to achieve progress in this field. This review attempts to find a paediatric cardiac surgeon's armamentarium for valve intervention, focusing on valve replacement of any of the four heart valves. The extensive literature review conducted uses online resource material from relevant medical and scientific databases, such as Medline and Science Direct.

## CONTENTS

DECLARATION	i
ACKNOWLEDGEMENTS	ii
ABSTRACT	iii
LIST OF FIGURES	vi
LIST OF TABLES	viii
LIST OF ABBREVIATIONS	ix
<b>INTRODUCTION TO THE CLINICAL PROBLEM</b>	<b>1</b>
<b>OUTLINE OF THE THESIS</b>	<b>2</b>
<b>CHAPTER ONE: ANATOMY AND PHYSIOLOGY</b>	<b>4</b>
<b>1.1 INTRODUCTION</b>	<b>4</b>
<b>1.2 FUNCTIONAL CARDIAC ANATOMY</b>	<b>4</b>
1.2.1 BLOOD CIRCULATION	6
1.2.2 CARDIAC CYCLE	10
<b>1.3 VALVULAR FUNCTIONAL ANATOMY</b>	<b>14</b>
1.3.1 ATRIOVENTRICULAR VALVES (AtV)	20
1.3.2 SEMILUNAR VALVE (SL)	22
<b>CHAPTER TWO: DISEASE AND DIAGNOSIS</b>	<b>25</b>
<b>2.1 INTRODUCTION</b>	<b>25</b>
<b>2.2 VALVE STRUCTURAL AND FUNCTIONAL ANOMALIES</b>	<b>26</b>
2.2.1 AORTIC VALVE	29
2.2.2 PULMONARY VALVE	32
2.2.3 MITRAL VALVE DISEASE	34
2.2.4 TRICUSPID VALVE	37
<b>2.3 SYNDROMES: COMPLEX ANOMALIES</b>	<b>39</b>
2.3.1 TETRALOGY OF FALLOT	40
2.3.2 HYPOPLASTIC LEFT HEART SYNDROME	43
2.3.3 EBSTEIN'S ANOMALY	44
2.3.4 SHONE'S COMPLEX	45
2.3.5 MARFAN'S SYNDROME	45
2.3.6 EHLER-DANLOS SYNDROME	46
2.3.7 WILLIAMS SYNDROME	47
2.3.8 NOONAN'S SYNDROME	47
2.3.9 TRISOMY 18 AND 21	47
<b>2.4 CARDIAC IMAGING TECHNOLOGY FOR DIAGNOSING DISEASE</b>	<b>48</b>
<b>CHAPTER THREE: TREATMENT STRATEGIES</b>	<b>52</b>
<b>3.1 INTRODUCTION</b>	<b>52</b>
<b>3.2 PHARMACOLOGICAL THERAPY</b>	<b>52</b>
<b>3.3 MECHANICAL CARDIAC INTERVENTION</b>	<b>55</b>
3.3.1 VALVOTOMY AND BALLOON DILATION	56
3.3.2 SURGICAL INTERVENTION	59

<b>CHAPTER FOUR: CURRENT STATUS OF PAEDIATRIC VALVE REPLACEMENT</b>	<b>63</b>
<b>4.1 INTRODUCTION</b>	<b>63</b>
<b>4.2 VALVE TYPES</b>	<b>63</b>
4.2.1 MECHANICAL HEART VALVES	64
4.2.2 BIOPROSTHETIC HEART VALVES	69
<b>4.3 THE DEBATE: MECHANICAL VERSUS BIOPROSTHETIC VALVES</b>	<b>75</b>
<b>4.4 SURGICAL VALVE REPLACEMENT: OPTIONS AND OUTCOMES</b>	<b>78</b>
4.4.1 AORTIC VALVES	80
4.4.2 PULMONARY VALVES	84
4.4.3 MITRAL VALVES	86
4.4.4 TRICUSPID VALVES	88
<b>4.5 GROWN UP CONGENITAL HEART (GUCH) PROBLEMS</b>	<b>89</b>
<b>4.6 TECHNOLOGICAL LIMITATIONS</b>	<b>90</b>
4.6.1 LIMITATIONS WITH PROSTHESES	91
4.6.2 LIMITATIONS WITH SURGERY	93
<b>CHAPTER FIVE: FUTURE PERSPECTIVES</b>	<b>97</b>
<b>5.1 INTRODUCTION</b>	<b>97</b>
<b>5.2 EMERGING TECHNOLOGIES</b>	<b>98</b>
5.2.1 TISSUE ENGINEERED HEART VALVES	99
5.2.2 REPAIR TECHNIQUES: ANNULOPLASTY DEVICES AND LEAFLET CLIPS	101
5.2.3 PERCUTANEOUS VALVE IMPLANTATION	106
5.2.4 NOVEL CARDIOVASCULAR MATERIALS: POLYMERIC VALVE AND ENITINOL	119
<b>5.3 PAEDIATRIC VALVE RATIONALE: THE CHALLENGE</b>	<b>122</b>
<b>5.4 MEETING THE CHALLENGE: WHERE TO FROM HERE?</b>	<b>129</b>
<b>REFERENCES:</b>	<b>133</b>

## LIST OF FIGURES

Figure 1-1a): Anatomical position of the heart (9); Figure 1-1b): Schematic diagram of cardiac structures and blood circulation (11)	5
Figure 1-2: Schematic of blood circulation to body (12)	6
Figure 1-3a): Coronary circulation; two main coronary arteries exiting above the aortic valve (13); Figure 1-3b): Aortic valve (13)	7
Figure 1-4a): Foetal circulation (12); Figure 1-4b): Blood flow in the foetal heart (12)	8
Figure 1-5a)-c): Cardiac chambers with walls showing contraction motion and changes in atrial and ventricular chambers (12)	11
Figure 1-6: Cardiac cycle phases (12)	12
Figure 1-7: Pressure and volume relations in the left side of the heart during a cardiac cycle with the corresponding cardiac electrical signal measured on an ECG shown above (12)	13
Figure 1-8: Diagram of heart showing heart valve anatomy (9)	15
Figure 1-9a): Microstructural composition of leaflets (19); Figure 1-9b): Role of leaflet microstructure in valve deformation during opening and closing (4)	17
Figure 1-10: Cardiac skeleton consisting of dense connective tissue anchoring the heart valves and electrically isolating the ventricles from the atria (9)	18
Figure 1-11a): Valve overlap during closure (21); Figure 1-11b): Zone of coaptation shown in atrioventricular valves of the heart (22)	19
Figure 1-12: Stress and strain in an aortic valve (4)	20
Figure 1-13: a) Mitral valve shape (9); Figure 1-13b) Mitral valve anatomy (25)	21
Figure 1-14: Anterior view of tricuspid valve (9)	22
Figure 1-15a): Aortic valve in aorta (27); Figure 1-15b) Schematic of aortic valve anatomy (26)	23
Figure 1-16: Anatomy of the aortic valve (28)	23
Figure 1-17a): Pulmonary valve structure and position in heart; Figure 1-17b): Pulmonary valve with co-apting cusps	24
Figure 2-1a): Representation of valvular regurgitation; Figure 2-1b): Representation of valvular stenosis	27
Figure 2-2: Schematic representation of normal and stenotic aortic valve, in the open and closed position (37)	30
Figure 2-3: Bicuspid aortic valve with two fused leaflets creating a two leaflet aortic valve(44)	32
Figure 2-4: Pulmonary atresia (48)	33
Figure 2-5: Absent pulmonary valve with ventricular septal defect (50)	34
Figure 2-6: Schematic representation of mitral stenosis with narrowed orifice area (51)	35
Figure 2-7: Schematic representation of mitral valve regurgitation due to leaflet prolapse(56)	36
Figure 2-8: Tricuspid atresia (59)	38
Figure 2-9: Schematic of congenital malformation in ToF (49)	41
Figure 2-10: Schematic of Hypoplastic Left Heart Syndrome (72)	43
Figure 2-11: Schematic of Ebstein's Anomaly (75)	44
Figure 2-12: Two dimensional echocardiography with Doppler (83)	48
Figure 2-13: Transeosophgeal Echocardiography (TEE) procedure with ultrasound image of the heart and its chambers(85)	49
Figure 2-14: Three dimensional TEE (86)	50
Figure 2-15: Cardiac Catheterisation via the femoral artery (88)	51
Figure 3-1: Open surgical aortic valvotomy (92)	57
Figure 3-2: Balloon valvuloplasty procedure opening a stenotic mitral valve (93)	57
Figure 3-3: Schematic of the Norwood procedure performed as the first stage in shunting for HLHS (97)	60
Figure 3-4: Aortic valvuloplasty to repair the regurgitant valve (100)	62
Figure 4-1a): Starr-Edwards ball-in-cage heart valve, Figure 4-1b): Bjork-Shiley valve prosthesis	65
Figure 4-2a): St Jude Medical Regent valve (100); Figure 4-2b): Medtronic Hall Easy-Fit valve (100)	65
Figure 4-3a): Carbomedics paediatric aortic valve (119); Figure 4-3b): Paediatric mitral valve (119)	66
Figure 4-4: Carbomedics Carbo-Seal Valve-in-Conduit (119)	67
Figure 4-5: A stentless bovine pericardial valve (124)	69

Figure 4-6a): Separate stent components (124); Figure 4-6b) Final stented bovine pericardial valve with suturing cloth (124)	70
Figure 4-7: Contegra valve-in-conduit sourced from a bovine jugular valve (122)	70
Figure 4-8: Medtronic valves (Medtronic Inc, Minneapolis, MN, USA) Medtronic Hancock porcine stented valve components (left) and assembled valve (middle) and (right) Medtronic Freestyle stentless porcine valve (124)	71
Figure 4-9: CryoValve (CryoLife Inc, Kennesaw, GA USA) pulmonary homograft (129)	72
Figure 4-10: Carpentier-Edwards Perimount stented bovine pericardium (left) and the Edwards Prima Plus stentless porcine bioprosthesis (right) (138) (Edwards Lifesciences, Irvine, CA, USA)	75
Figure 4-11: Medtronic Freestyle stentless porcine (left) and Medtronic Mosaic stented porcine (right) (103) (Medtronic Inc, Minneapolis, MN, USA)	75
Figure 4-12: Blood flow through a mechanical valve (left) and a bioprosthetic valve (right) (120)	77
Figure 4-13: Scarring after open-heart surgery (158)	96
Figure 5-1: Valve surgeries performed at the Boston Children's Hospital (168)	99
Figure 5-2: Tissue engineered heart valve concept using foetal stem cells to engineer a percutaneous heart valve mounted on a stent intended for paediatric use (172)	100
Figure 5-3a): Annuloplasty ring implanted in mitral valve position; Figure 5-3b): Representation of an annuloplasty ring used to fix a damaged mitral valve (100)	103
Figure 5-4: Coronary sinus annuloplasty devices: MONARC (Edwards Life Sciences, Irving, California) (177) (left) and CARILLON XE device (Cardiac Dimension, In., Kirkland, Washington) (175) (right)	104
Figure 5-5: MitraClip device with catheter (top left)(177), the device mechanism (top right)(174), a schematic of the implanted MitraClip clamping the bileaflet mitral valve (bottom left) (177) and the double orifice created reducing effective orifice area (bottom right)(174)	106
Figure 5-6a): Antegrade approach (182); Figure 5-6b) Retrograde approach (182)	107
Figure 5-7: Transapical approach to aortic valve implantation (180)	108
Figure 5-8: Medtronic Melody percutaneous pulmonary valve (Medtronic Inc., Minneapolis, MN, USA) (184)	109
Figure 5-9: Transcatheter aortic valves – Edwards SAPIEN XT (Edwards Life Sciences Corporation, Irvine, CA, USA)(a and b, top left and top right) and the CoreValve (Medtronic CV Luxembourg)(c and d, bottom left and bottom right)(180)	110
Figure 5-10a): Paniagua (Endoluminal Technology REsearch, Miami, FL, USA) (186); Figure 5-10b): Heart leaflet (Heart Leaflet Technologies, Maple Grove, MN, USA) (180)	111
Figure 5-11: Direct flow (Direct Flow Medical, Santa Rosa, CA, USA) (left) (180) and Sadra Lotus percutaneous heart valve (Boston Scientific SciMed Inc, Maple Grove, MN, USA) (right)(185)	112
Figure 5-12: ABPS PercValve (Advanced Bioprosthetic Surfaces, San Antonio Tx) a) Closed valve b) Top view and c) partially collapsed (187)	112
Figure 5-13: ValveXchange valve components (ValveXchange Inc., Aurora, CO, USA) (188)	113
Figure 5-14: Assembled ValveXchange valve (185)	113
Figure 5-15: Bjork Shiley prosthesis on left with sewing ring embedded with a circlip (left) and valve assembly with detachable annulus(right) (189)	114
Figure 5-16: Prototype of replaceable valve by Fukamachi <i>et al.</i> (190), Base magnetic ring (left) and magnetic annulus implanted in mitral valve position (middle) and assembly mechanism (right) (190)	114
Figure 5-17: Schematic of Ebner <i>et al.</i> 's (191) assembled three-part replaceable valve design (190)	114
Figure 5-18: Representation of a possible Polymeric heart valve design (left) and a manufactured PHV with Dacron suturing ring (right)(162)	119
Figure 5-19: Schematic description of the damage cause to blood cell components during valve closing and as a result of leakage during closure (133)	126
Figure 5-20: a) An occluder used to patch an atrial septal defect and b) The Amplatzer patent foramen ovale (PFO) occluder (205)	128

## LIST OF TABLES

Table 2-1: Prevalence of valve abnormalities occurring in CHD (15,18,33-35)	28
Table 2-2: List of common defects associated with AV regurgitation and stenosis (15,33,35)	29
Table 2-3: List of common defects associated with pulmonary valve stenosis or regurgitation (39,47)	33
Table 2-4: List of common defects associated with mitral valve stenosis and regurgitation (39,45)	35
Table 2-5: List of common causes of tricuspid valve stenosis or regurgitation as a result of disease (33,39)	37
Table 2-6: Syndrome affecting cardiac structures including valve(s) (4,33,41,45,60-64)	40
Table 3-1: Medical treatment options for valvular disease (90)	54
Table 3-2: Balloon valvuloplasty as a treatment strategy for various disease or disorders (87)	58
Table 3-3: A list of common palliative procedures performed when treating valvular disease (99)	62
Table 4-1: Materials used in mechanical valve prosthesis (102)	64
Table 4-2: Heart valves available in sizes small enough for the paediatric patient (101,120,121) OD: Outer diameter, ID: Inner diameter	66
Table 4-3: List of popular bioprosthetic valves used in children (120,128,129)	74
Table 4-4: Comparison of mechanical and bioprosthetic valve types (118,139)	76
Table 4-5: Indication of valve prosthesis selection for all heart valve positions (120,122,142)	80
Table 4-6: Common complications and limitations experienced with surgery (120,151)	94
Table 5-1: List of design features sought in an ideal paediatric heart valve (96,122,133,154,164)	123

## LIST OF ABBREVIATIONS

AR:	Aortic Regurgitation
AS:	Aortic stenosis
AtV:	Atrioventricular valve
AV:	Aortic Valve
BAV:	Bicuspid Aortic Valve
CE:	Conformité Européenne
CHD:	Congenital Heart Disease
CHVC:	Congenital Heart Valves Center
CHVD:	Congenital Heart Valve Disease
CSVD:	Congenital Semilunar Valve Disease
ECM:	ExtraCellular Matrix
EOA:	Effective Orifice Area
FDA:	Food and Drug Administration
GUCH:	Grown-Up Congenital Heart
HDE:	Humanitarian Device Exemption
HLHS:	Hypoplastic Left Heart Syndrome
ID:	Inner Diameter
IDE:	Investigational Device Exemption
LA:	Left Atrium
LV:	Left Ventricle
LVOT:	Left Ventricular Outflow Tract
MEMS:	MicroElectro Mechanical System
MI MVS:	Minimally Invasive Mitral Valve Surgery
MR:	Mitral valve Regurgitation
MRI:	Magnetic Resonance Imaging
MS:	Mitral valve Stenosis
MV:	Mitral Valve
MVP:	Mitral Valve Prolapse
OD:	Outer Diameter
POSS:	Polyhedral Oligomeric SilSequioxane
PFO:	Patent Foramen Ovale



PR: Pulmonary valve Regurgitation  
PS: Pulmonary valve Stenosis  
PTFE: PolyTetraFluoroEthylene  
PV: Pulmonic/Pulmonary Valve  
PVD: Pulmonary Valve Disease  
RA: Right Atrium  
RV: Right Ventricle  
RVOT: Right Ventricular Outflow Tract  
RV-PA: Right Ventricular Pulmonary Artery  
SL: SemiLunar valve  
TAVI: Transcatheter Aortic Valve Implantation  
TEE: TransoEsophageal Echocardiography  
ToF: Tetralogy of Fallot  
ToF-PA: Tetralogy of Fallot with Pulmonary Atresia  
ToF-APV: Tetralogy of Fallot with Absent Pulmonary Valve  
TR: Tricuspid valve Regurgitation  
TS: Tricuspid valve stenosis  
TTE: TransThoracic Echocardiography  
TV: Tricuspid Valve  
UCLA: University of California Los Angeles  
VIC: Valvular Interstitial Cells  
VHD: Valvular heart disease.

## INTRODUCTION TO THE CLINICAL PROBLEM

Valvular heart disease (VHD) is less prevalent than coronary artery disease or atherosclerosis, but it is an escalating and serious problem affecting numerous people at any stage of life.(3) It is estimated that, by 2050, more than a million valve disease surgeries will be performed worldwide every year. This is three times the current number of cardiovascular surgeries performed.(4) Since heart valve disease is the greatest expected cause of heart failure, it is clearly evident that valvular heart disease is rapidly becoming a public health issue.(3,5)

In the ageing part of the population, valvular degeneration is of the greatest concern, whereas in the younger, early life population, congenital malformations are largely responsible for defective heart valves. Congenital heart valve disease (CHVD) is therefore the greatest concern in the younger population, but valvular heart disease (VHD) may also be acquired due to acute episodes of rheumatic fever. However, rheumatic fever is less prevalent in developed countries and can be prevented with prophylactic medication. This implies that, in theory, since rheumatic fever can be pharmacologically treated, this source of valvular heart disease does not contribute significantly to the future youthful population needing valve prostheses.

The ages of this youthful or 'early life' population range from neonates, at 1 to 30 days, through infants from 31 to 365 days, to children from 1 to 16 years of age, and ending in mid-adolescence, at 16 years of age. At this point, the adolescent or 'young adult' can be suitably treated using medical devices suitable for adults. Adulthood generally starts around 18 years of age and marks the start of the life period in which growth ceases and the heart is fully matured.

The need to focus on valve technologies for the 'early life' population group is partly due to the increasing incidence of CHVD, currently ranging between 0.6% and 1% in all live-births.(6) Today, 80% to 85% of this population survive to adolescence and adulthood respectively, so the growing need for better

treatment technologies is clear. There is great potential to treat a young congenital patient and to achieve excellent clinical outcomes. By drastically improving a patient's quality of life, the person's life expectancy can be improved further, potentially reaching well into old age.(6) This improved survival is due to the increasing variety of surgical and invasive therapies available to treat such individuals palliatively.

The available technologies include valve replacement prostheses, the second most common major heart operation in the world today.(4) In the case of young patients, the use of such prostheses generally involves adapting adult-designed valve replacements to meet the size and functional requirements of the young patient. These requirements include significant skeletal and cardiac growth, requiring energy consumption that differs greatly from that of physically mature adults. It is thus clear that this patient group cannot be treated using the same surgical strategies as those used on adults.

It is this difference in treatment strategy, addressing patient-specific needs, that gives rise to the need for paediatric-specific valve prostheses. It is necessary to identify exactly what these specific needs are or might be, as well as the extent to which current valve technologies attempt to address these needs. It is from this clinical problem in the early life patient that the need for a detailed literature review arises. Such a review, as undertaken in this study, constitutes a starting point in the quest to understand how to go about designing a heart valve for paediatric congenital heart disease (CHD) patients.

### **Outline of the Thesis**

The literature review in this study, reports on background information on valvular heart disease and the need for heart valve replacement technologies. Chapter One introduces the anatomical and physiological characteristics of a young individual, discussing aspects unique to the foetus and how cardiac changes come about from the neonate stage, through infancy and childhood, and into adolescence.

Chapter Two discusses how disease, whether rheumatic or congenital in nature, affects valve structures. It discusses two features of valvular disease, namely regurgitation and stenosis, and identifies the nature and complexity of some of the most common syndromes that require valvular intervention.

Chapter Three discusses possible interventions, ranging from medical therapy to cardiac intervention. It highlights the techniques incorporated into managing valvular disease in paediatric patients. Such techniques focus mainly on repair strategies and palliative shunting approaches. The chapter ends by explaining the need for valve replacement technologies when other palliative interventions fail.

Chapter Four discusses heart valve replacement in the paediatric population in respect of the valve prostheses available, whether mechanical or bioprosthetic. It highlights the clinical outcomes experienced with both types for all valve positions. The chapter includes a discussion of the grown-up congenital heart (GUCH) valve disease population and how intervention at an early stage of life affects this population in adulthood. The chapter concludes with an overview of the limitations and challenges that clinicians experience when employing the valve prostheses currently used for the young.

Chapter Five, the last and concluding chapter, discusses the three main emerging technologies in the cardiac field: tissue heart valves, polymeric heart valves and mitral repair techniques used to avoid mitral valve replacement. It also touches briefly upon novel cardiac biomaterials that are showing some promise for valve replacement technologies. The chapter, and thus the literature review, concludes with the criteria for an ideal paediatric valve, discussing the rationale behind this set of criteria, and how to go about meeting the challenges of designing a paediatric heart valve.

# Chapter One: Anatomy and Physiology

## 1.1 Introduction

All living cells require energy (from metabolism) and oxygen to survive. In order to sustain this life, the resulting metabolic waste must also be removed. Energy sources and oxygen are continuously provided, while carbon dioxide and metabolic wastes are continuously removed, by means of mass exchange with a working fluid, blood. Blood is transported throughout the living organism, perfusing all the tissues and organs, thereby sustaining life. The blood transportation mechanism that achieves this is the cardiovascular system, which is a body-wide transport system, consisting of the blood, the blood vessels, the lymphatic system and the heart.(7)

## 1.2 Functional Cardiac Anatomy

The heart is central to the cardiovascular system. It provides the mechanical pulsatile pumping power to drive blood through the blood vessel network unidirectionally. Blood continuously circulates through this network, perfusing into the surrounding tissue and organs before returning to the heart.

The heart is centrally situated within the thoracic cavity (see Figure 1-1a). It rests on the diaphragm and is located near the lower portion of the lungs. It is the first organ to function in the developing foetus.(8) It eventually becomes a muscular, conically-shaped, hollow organ at 11 weeks in utero.(9)

It is partitioned into two halves by an inter-atrial ventricular septum, dividing it into a left and a right half (see Figure 1-1b). Each side contains two chambers, a receiving chamber or atrium, and a discharging chamber called a ventricle. There are four one-way valves in the heart. Two valves separate the atria from the ventricular chambers – these are known as the atrioventricular valves (AtV). Two more valves are located in the arterial (outflow) tracts. These two valves

are known as the semilunar valves (SL). They separate the ventricles from the great arteries.(10)

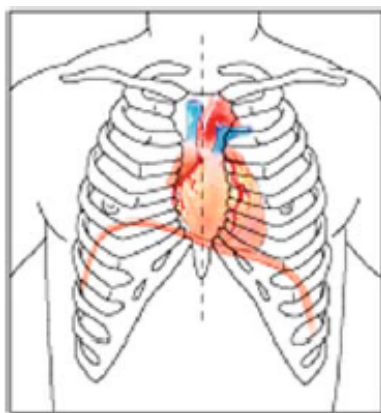


Figure 1-1a): Anatomical position of heart (9)

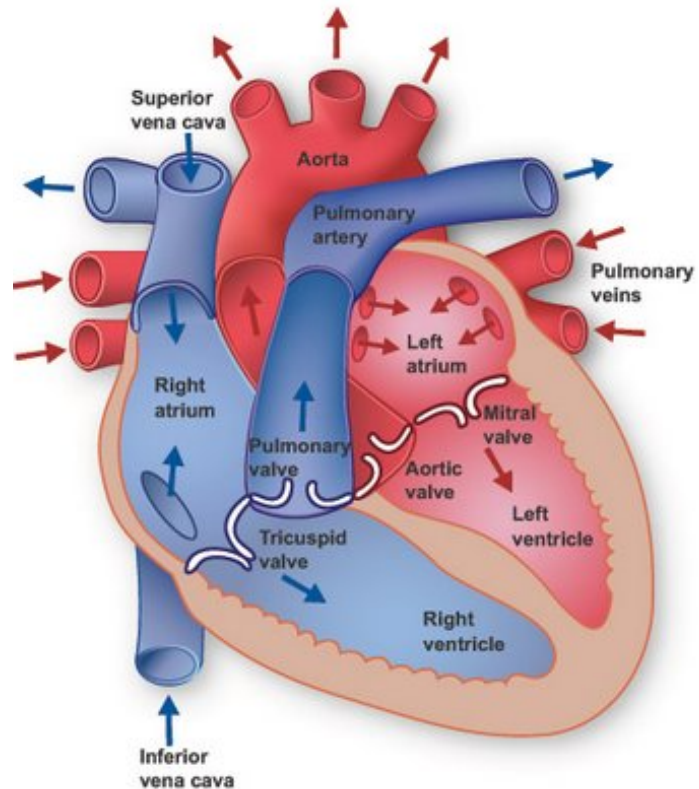


Figure 1-1b): Schematic diagram of cardiac structures and blood circulation (11)

Altogether, there are four chambers and four valves, with each side of the heart containing two chambers and two valves. The left half is responsible for pumping oxygenated blood to the body and the right half pumps deoxygenated blood to the lungs. This is marked in Figure 1-1b, with blue representing deoxygenated blood, while red represents oxygen-rich blood.

The heart provides the necessary muscular contractions to circulate blood through the body. The sequence of these muscular contractions and dynamic cardiac changes is considered part of the cardiac cycle, while the blood flow route forms the blood circulation.

### 1.2.1 Blood Circulation

The flow circuit by which deoxygenated blood, from the right ventricle (RV) of the heart, enters the lungs, and oxygenated blood exits, on its way back to the left atrium (LA) is referred to as the pulmonary circulation or the pulmonary circuit, because the system relates to the lungs (from Latin *pulmo*, lung). The flow circuit of oxygenated blood exiting the left ventricle (LV), perfusing throughout the body and returning as deoxygenated blood into the right atrium (RA), is called the systemic circulation or circuit, because it involves the whole body as a system, other than the lungs (see Figure 1-2).(10)

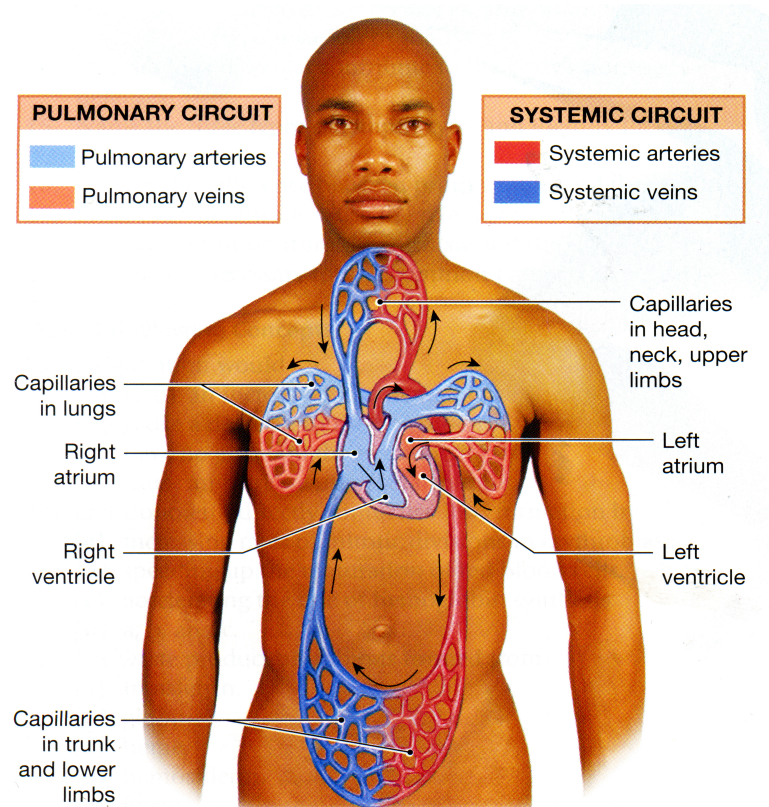


Figure 1-2: Schematic of blood circulation to body (12)

The heart is a functioning organ itself, consisting of cardiac muscle, so it requires its own blood supply. This coronary circulation forms part of the systemic circulation, with efferent blood vessels exiting the bulging sinuses of the aortic valve. These coronary arteries lead to the muscular cardiac walls, perfusing them with nutrient-rich blood (see Figures 1-3a and 1-3b)

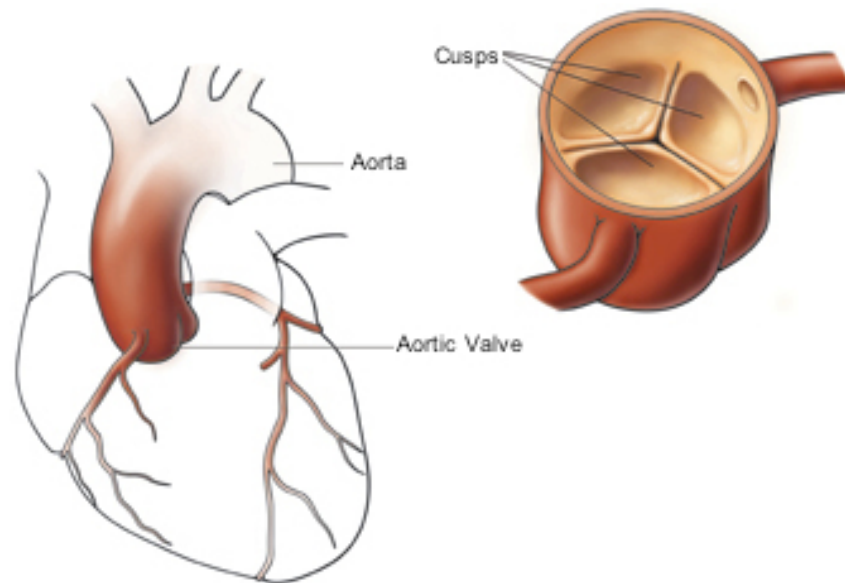


Figure 1-3a): Coronary circulation: two main coronary arteries exiting above the aortic valve (13)

Figure 1-3b): Aortic valve (13)

The pulmonary, systemic and coronary circulation are all interconnected with one another. This interconnection can be described, when considering the body's blood circulation, by starting from any point within the cycle. For example, one can start with the oxygenated blood leaving the pulmonary circulation – this circuit route is described here and shown in Figure 1-b and Figure 1-2. Oxygenated blood from the lungs enters the left atrium via the pulmonary vein. From the left atrium, it then passes through the bicuspid or mitral valve (MV) and into the left ventricle (LV). It then exits into the aorta, passing through the aortic valve (AV), situated within the aortic root. The aorta arches around and behind the heart, branching off to supply the upper and lower body with nutrient- and oxygen-rich blood.

As blood flows through the vessel network, oxygen is taken up by the surrounding tissue, leaving the blood deoxygenated. This deoxygenated blood then returns to the heart via the superior and inferior vena cava from the upper and lower body, respectively. The deoxygenated blood enters the right atrium and then continues into the right ventricle (RV), passing through the tricuspid valve (TV) between the two chambers. It then exits the RV passing through the pulmonary semilunar or pulmonic valve (PV) and into the pulmonary artery.



This artery leads to the lungs, where the blood rich in carbon dioxide is exchanged for oxygen, thus becoming re-oxygenated before returning to the left side of the heart, from where it is once again pumped throughout the body. These oxygenated and deoxygenated pathways combine to form the complete circulatory system, involving the pulmonary, systemic and coronary circuits.

In a developing foetus, the lungs do not yet function, and thus the pulmonary circuit is not yet needed. Instead, a foetus receives its oxygen and nutrient requirements from its mother, via the umbilical cord. This oxygen and nutrient mass transfer, which is necessary for the growth and survival of the unborn child, occurs via the placenta from one circuit into the other and vice versa. The foetal and maternal blood circuits are completely separate, so that the mother and the foetus's blood do not mix. Since the foetus's oxygen and nutrients are obtained from the mother, the functional requirement on the foetal heart is relaxed, eliminating the need for prenatal pulmonary circulation (see Figure 1-4a)

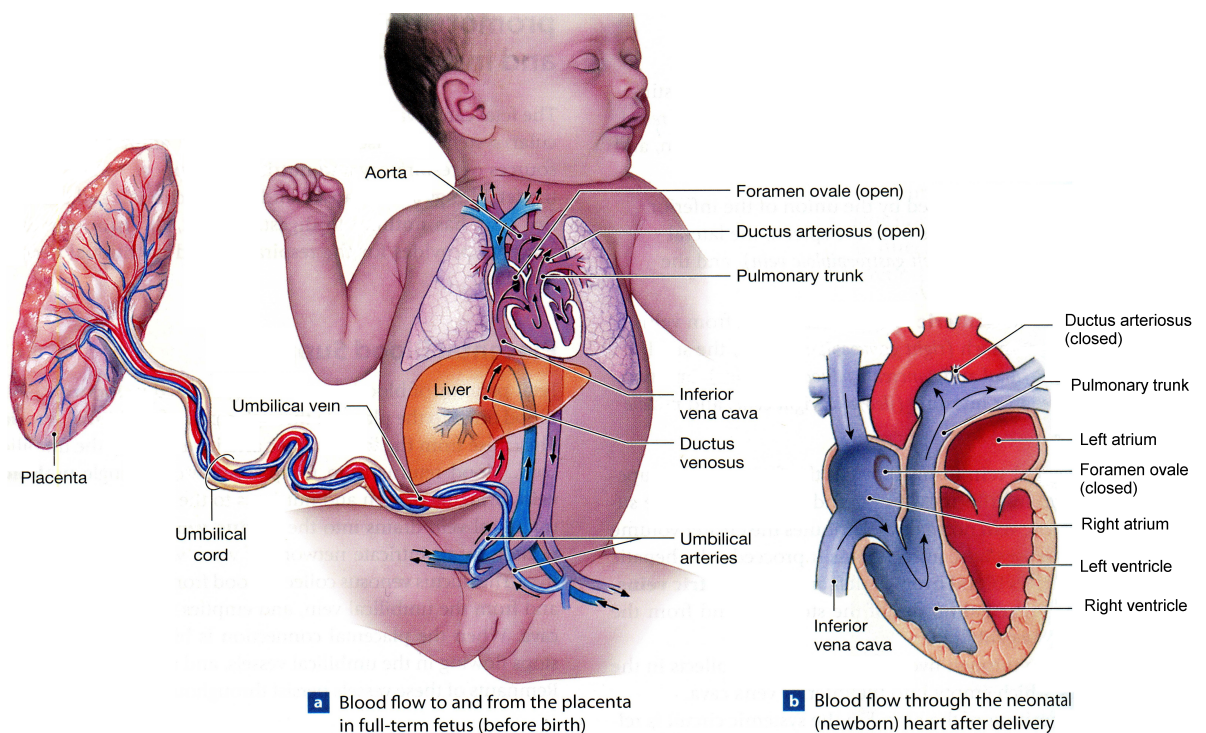


Figure 1-4a): Foetal circulation (12)

Figure 1-4b): Blood flow in the foetal heart (12)

In order to eliminate the need for foetal pulmonary circulation, blood bypasses the lungs, thus requiring additional cardiac features that are not present in postnatal individuals. It is best described by investigating the foetal blood circulation (see Figure 1-4b). Nutrient-rich blood from the placenta enters the foetus's somatic blood supply via the umbilical veins in the umbilical cord. Part of the blood first passes through the foetal liver, while the rest bypasses it via a duct called the ductus venosus. It then continues to the right atrium of the developing heart. Here, unlike in a post-birth individual, the blood splits, entering both the right ventricle and the left atrium.

This passage into the left atrium is possible because there is a valved-interatrial opening called a foramen ovale. The foramen ovale functions like a valve, allowing blood to flow only from the right to the left atrium and not vice versa. In addition to this opening, another passageway called the ductus arteriosus (located after the pulmonary valve) is open, linking the right ventricle with the aortic arch. This allows blood to flow from the pulmonary artery directly into the aorta, passing into the somatic blood circuit.

Together, the foramen ovale and the ductus arteriosus allow most of the foetal blood to bypass the pulmonary circuit. Then 25% of the foetal blood from the umbilical cord exits the right atrium via the foramen ovale and passes into the left atrium. A further 90% of the remaining 75% blood exiting the right ventricle flows through the ductus arteriosus and into the systemic circulation. That means that only 5% to 10% of the blood from the umbilical cord actually exits the right ventricle, entering the lungs. This provides adequate nutrients to the lungs, allowing them to grow.(12,14)

Part of the deoxygenated blood in the foetus's systemic circulation leaves the foetus via the umbilical arteries. These arteries lead to the placenta, where the blood is re-oxygenated before returning to the foetus's heart via the inferior vena cava. The rest of the blood, which is not re-oxygenated, returns to the right atrium via the superior and inferior vena cava. These two blood paths join

together in the inferior vena cava, mixing the (re-)oxygenated and deoxygenated blood before entering the right atrium.

The unique prenatal blood circulation is possible because of the high blood flow resistance in the collapsed lung, together with the ductus arteriosus and foramen ovale. It is often when there are malformations of these openings, or when they fail to close postnatally, that congenital cardiovascular problems arise.

### **1.2.2 Cardiac Cycle**

In the context of blood circulation, the cardiac cycle is also important. It describes blood flow, as well as the interaction of the structures of the heart in terms of cardiac dynamics. It describes the time sequence of events involving successive diastolic (chamber filling) and systolic (chamber emptying) phases of the heart, for any given heartbeat. This provides an understanding of the haemodynamic conditions in which the valves operate, in other words, the pressure and blood flow requirements for any particular individual.

The cardiac walls are essentially striated cardiac muscle that electrically conduct the pace-making impulses necessary for muscular contraction (see Figure 1-5). The cardiac cycle follows this electrical sequence of events, describing the resulting actions from the start to the end of a given heartbeat, which defines a single cardiac cycle. The cycle is repeated over and over again, with the cycle timing defined by the heart rate.

For the purposes of the current study, it is not necessary to explain the complex electrical excitation involving depolarization and repolarization conducting action potentials through the cardiac muscle. However, it is important to understand that any disease that affects the muscular wall will have a corresponding effect on the heart chambers. This can lead to altered valve anatomy and functioning. In an average lifetime (75years), the heart beats approximately 3 billion times, with 100 000 beats per day handling roughly 5 litres per minute, so it is not surprising that even the slightest variation from

normal function can have a severe impact on an individual. Over time, variations can often lead to heart failure.(8)

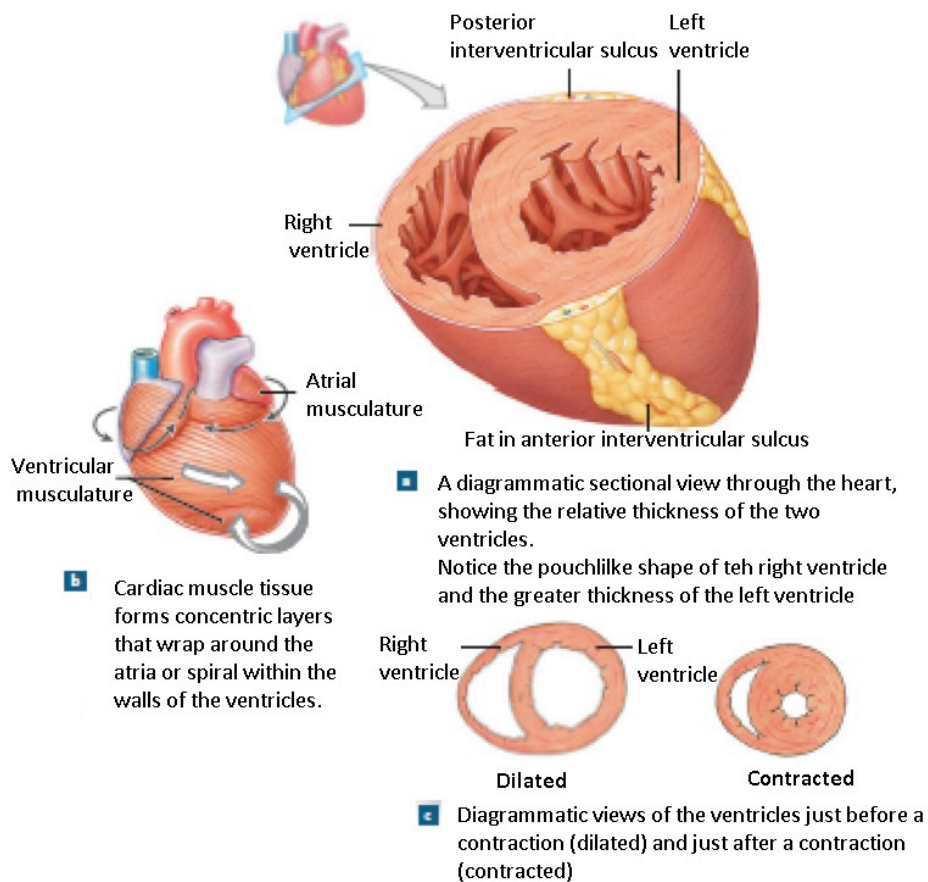


Figure 1-5a)-c): Cardiac chambers with walls showing contraction motion and changes in atrial and ventricular chambers (12)

Carefully timed electrical impulses cause successive heart contractions and periods of relaxation. These timed periods in any given cardiac cycle are represented by four phases. These phases, given in sequential order, are

- atrial systole
- atrial diastole
- ventricular systole
- ventricular diastole.

Starting with complete cardiac relaxation with open atrioventricular (AtV) valves, the cardiac cycle shown in Figure 1-6 is described here.



The AtV valves are open during atrial and ventricular diastole. The blood then flows from the systemic blood network (higher in pressure) into the heart. Blood passively fills the atria, flowing through the open AtV valves and into the ventricles. Once the ventricles are approximately three quarters full, an electrical signal spreads from the pace-making node – called the sino-atrial node – throughout the atria. This allows the atria to contract simultaneously, expelling the remaining atrial blood through the AtV valves into the ventricles. This is termed atrial systole.

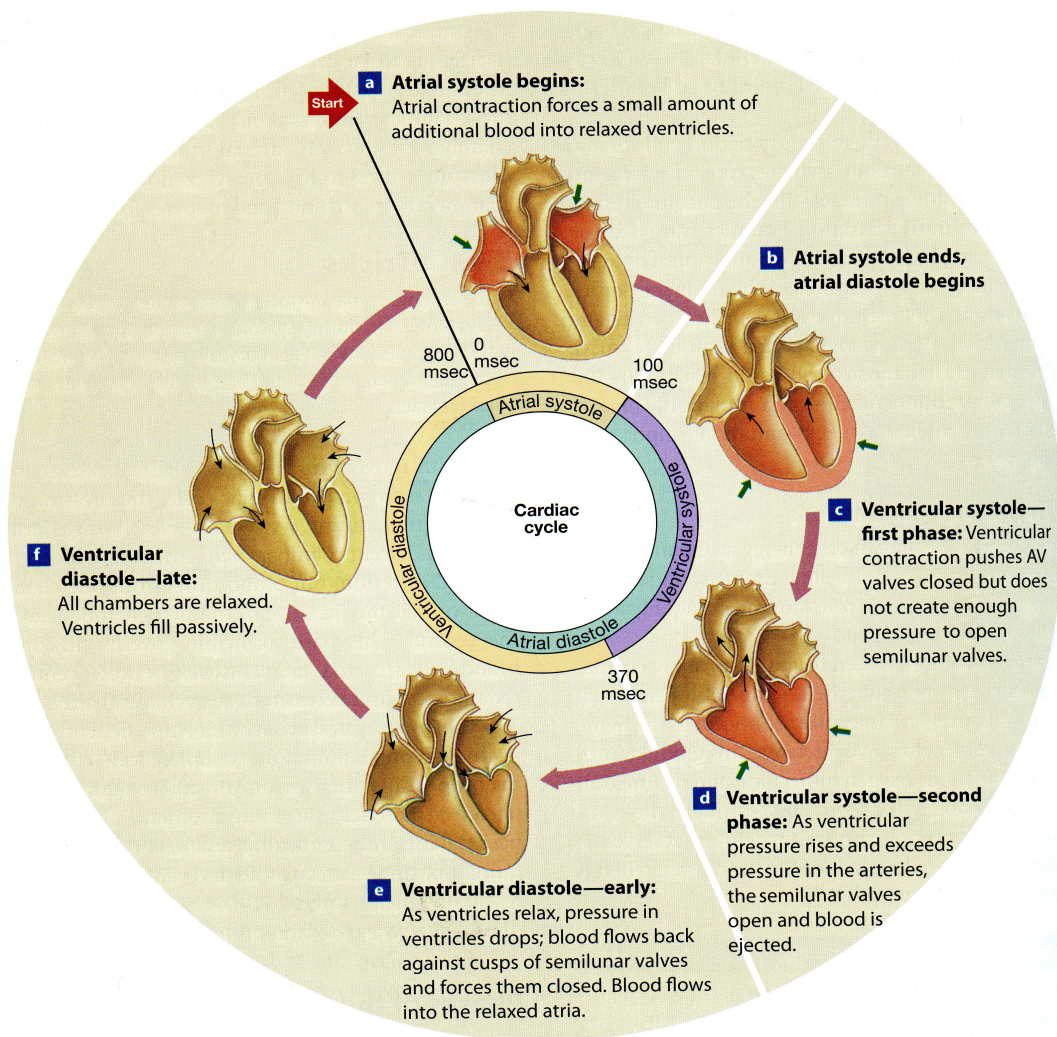


Figure 1-6: Cardiac cycle phases (12)

While the atria are in systole, the electrical signal travels toward the atrioventricular node, from where, after a delay, it spreads to the ventricles. This allows the ventricles to contract only once atrial systole has been

completed. Once the ventricles are in systole, the atria relax and enter the diastolic phase, remaining relaxed until the next cardiac cycle. It is important to note that the atria and ventricles are electrically isolated from one another. The fibrous rings around the atrioventricular valves provide this isolation, so that the receiving and emptying chambers do not contract simultaneously. Simultaneous contraction by the atria and the ventricles would be counteractive in pumping blood out of the heart. Instead, to efficiently pump blood, the atria contract simultaneously, and then the ventricles do likewise.

During ventricular systole, the pressure in the ventricles increases until it exceeds that of the atria (see Figure 1.7).

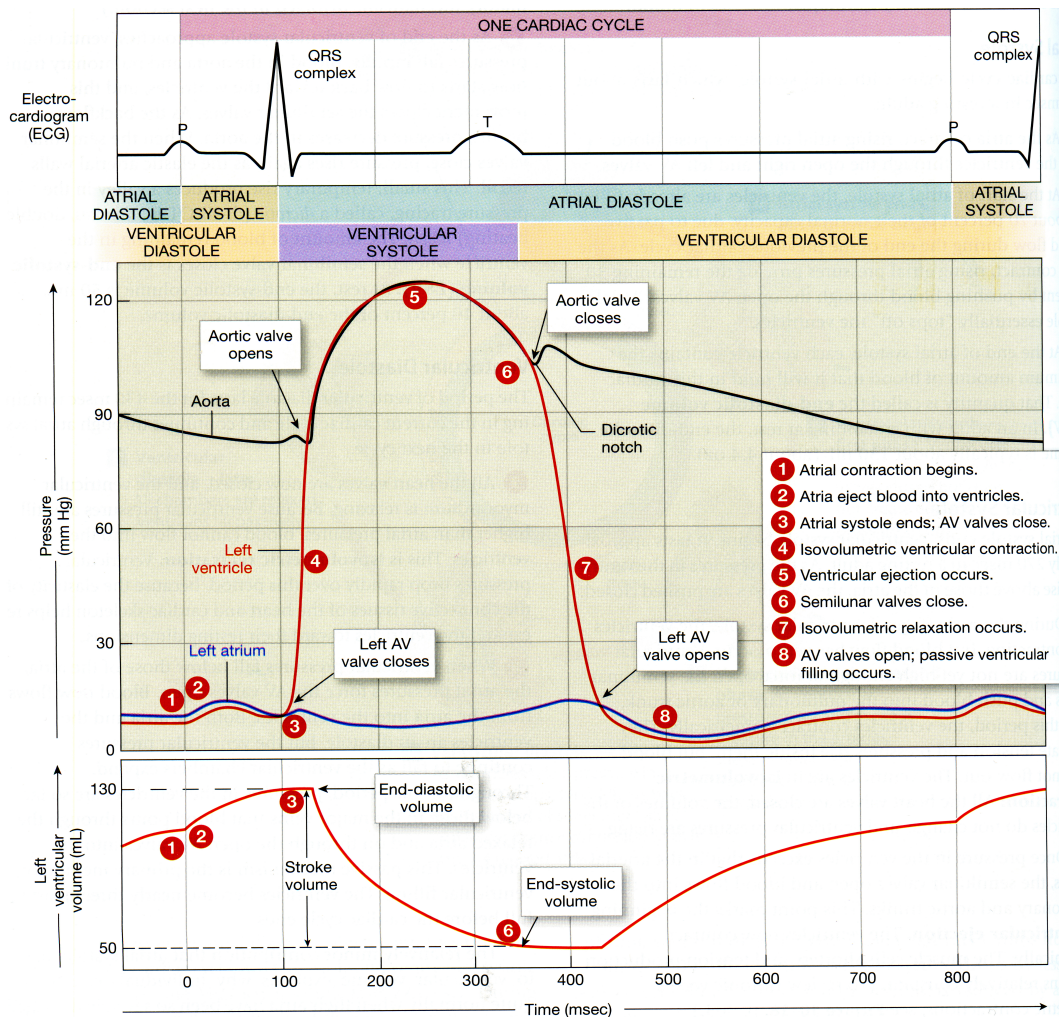


Figure 1-7: Pressure and volume relations in the left side of the heart during a cardiac cycle with the corresponding cardiac electrical signal measured on an ECG shown above (12)

This causes the AtV valves to close. As the pressure continues to increase in the left and right ventricles, it starts to exceed the pressure in the aorta and the pulmonary artery, respectively. This forces the SL valves open, expelling blood from the ventricles into the great arteries.

After ventricular contraction is completed, the phase of ventricular relaxation, called ventricular diastole, begins. When the pressure in the arteries decreases until it exceeds that in the ventricles, the SL valves close before the blood can flow back into the ventricles. Since the blood cannot re-enter the left and right ventricles, it is forced into the systemic blood vessel network leading to the body and the pulmonary blood vessel network leading to the lungs. At this point, both the atria and ventricles are relaxed and in diastole, with the AtV valves open. From here, the heart is again passively filled and the cardiac cycle is repeated.(12)

To gain an understanding of the physiological and haemodynamic effects that the cardiac cycle has on the valves, it is necessary to understand the valves' functional anatomy and dynamics.

### **1.3 Valvular functional anatomy**

Soon after heart formation (termed cardiogenesis), the valves are initially formed as endocardial cushions, as a result of extensive extracellular matrix remodeling.(8) The AtV valves consist of the mitral (MV) and tricuspid valve (TV), while the SL valves consist of the aortic (AV) and pulmonary valve (PV) (see Figure 1-8).

Each of the four cardiac valves has its own physiological requirements necessitating different anatomical features. Despite the structural deviation from one another, they all still perform the same function: to act as one-way check valves, allowing uni-directional blood flow through the heart and thus the body. It may seem that their apparently simple function, having to open and close at particular times in the cardiac cycle, is trivial. In fact, this function is vital.



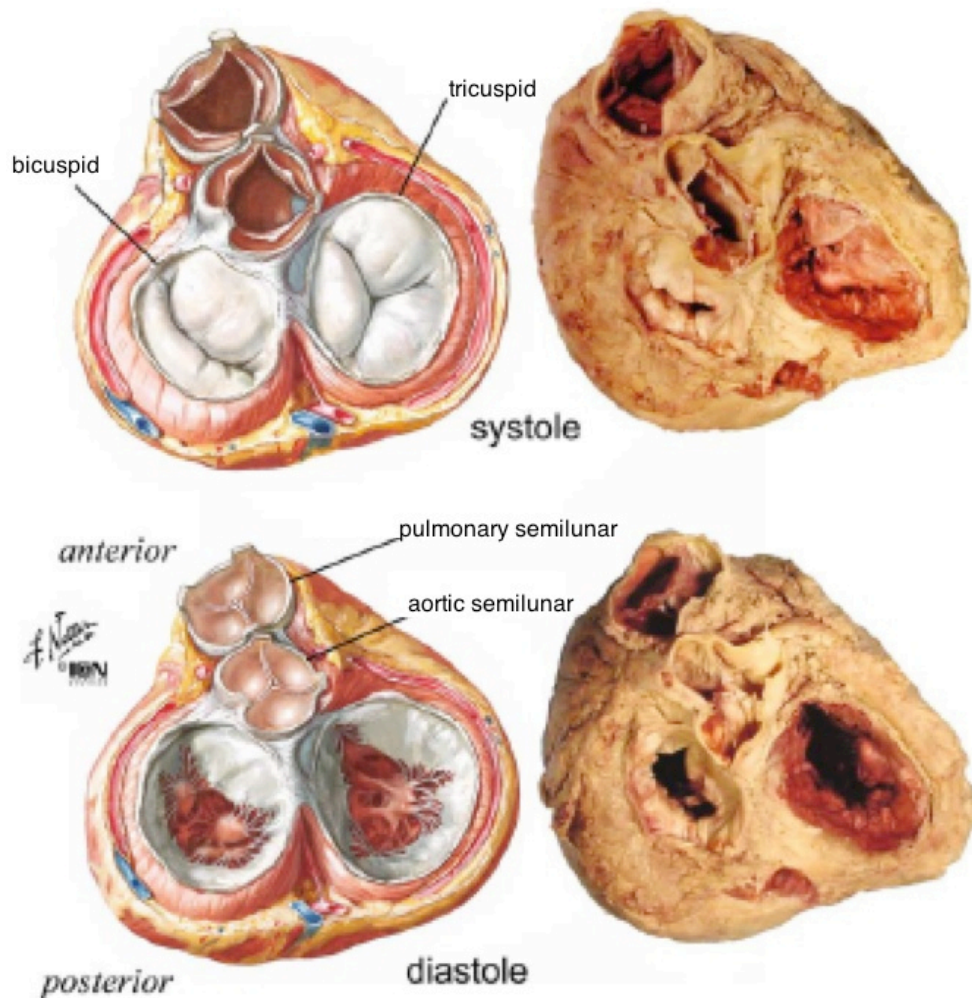


Figure 1-8: Diagram of heart showing heart valve anatomy (9)

Depending on the type and position of the valve, be it atrioventricular or semilunar, it must adapt to various haemodynamic conditions, ranging from a state of rest, with lowered heart rates, to higher rates occurring during physical activities such as exercising.

This complicates the matter of the timing of valve opening and closing and alters the loading conditions under which each valve operates. To complicate matters further, the heart is not a stationary organ. In order to force the blood out of the ventricles and into the arterial trunks, the myocardial muscle must generate the pumping power through muscular contraction. This contraction, which is also torsional in nature, changes the shape of the chambers and



therefore physically translates the valve position as the chambers distort (see Figures 1-5b and c).

In addition, the valve orifice area varies, depending on the degree of leaflet motion. Greater motion is achieved at a higher cardiac output rate (for example, during exercise), which increases the effective orifice area.(15) Conversely, when the cardiac output demand is reduced, the valve leaflets relax more, into a distorted shape. This lowers the haemodynamic demand on the valve.

To function effectively, the valves must interact with the surrounding structures in a very specific way in order to seal appropriately when the valves are closed or provide an unobstructed passageway for blood flow when they are open.

This shows the complexity of valvular function, hinting at the macrostructural and microstructural complexity required to allow a valve to function under such diverse conditions. It is therefore necessary to have a good understanding of the anatomical and physiological characteristics of the valve complex. How the components of the valvular complex interact with one another defines its function. This structure-function relationship is a critical consideration in prosthetic valve designs, particularly when designing valves with growth potential, which must adapt biomechanically to the structural changes that are inherent to growth and cardiac maturation.

The heart valves consist of metabolically active tissue that remodels and adapts to its haemodynamic environment. Their structural complexity depends on where they are situated. In all four cardiac valves, each valve consists of an annulus or ring to which varying number of cusps or leaflets are attached. In the AtV valves additional structures are present that assist with valve stabilization and function,(8), as discussed in Section 1.3 of the study.

The microstructure of the leaflets common to all the cardiac valves plays a pivotal role in the adequate functioning of the valves. These leaflets or cusps consist of valvular interstitial cells (VIC) in an extracellular matrix (ECM),

covered by a layer of endothelium. It is these VICs that are responsible for synthesizing collagen, elastin, proteoglycans and contractile proteins, all of which help with valve functioning.

These molecules are arranged in three layers sandwiched between endothelial monolayers. These stratified molecules form the fibrosa, spongiosa and ventricularis or atrialis layers (see Figure 1-9a). The outer fibrosa layer is in contact with the outflow blood surface. It contains circumferentially oriented fibrillar collagen, which gives the valve its primary strength and tensile stiffness. The spongiosa (the middle layer or central core) consists of loose connective tissue containing proteoglycans and collagen fibres. This allows the valve to be compressible, as these fibres provide shock-absorbing properties while maintaining structural integrity. The third layer, the ventricularis in the semilunar valves, or articularis in the atrioventricular valves, is in contact with the blood inlet side. This layer is responsible for assisting tissue motion during valve opening and closing (see Figure 1-9b). The elastic fibers in this layer allow the valve to extend and recoil, because they are elastic and are radially oriented. (8,14,16,17)

It is the VICs that control the composition of these molecules in the extracellular matrix that influences the valves' function. Valvular maintenance through appropriate synthesis, degradation and remodelling of the ECM gives rise to valve integrity and pliability.(18)

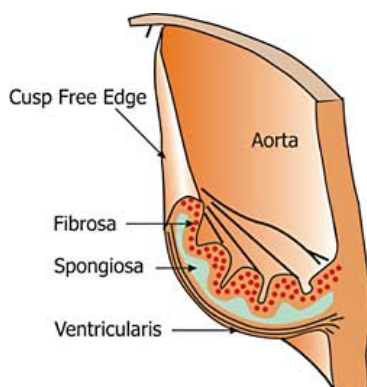


Figure 1-9a): Microstructural composition of leaflets (19)

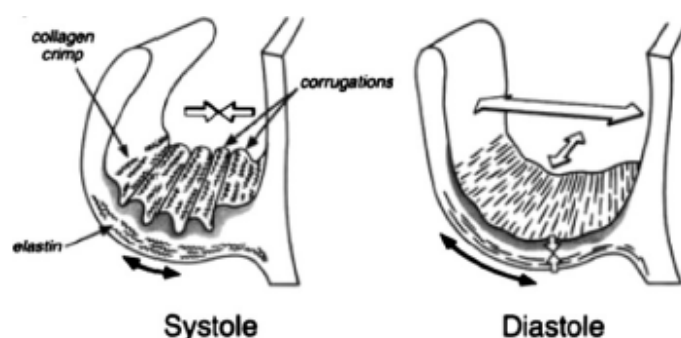


Figure 1-9b): Role of leaflet microstructure in valve deformation during opening and closing (4)

The amount of constituents in each layer make up the leaflet thickness. This amount depends on the valve position and may vary, not only among leaflets, but also within a particular leaflet. The leaflets are usually less than 1 mm thick, and the valves on the left side are thicker than those on the right. Similarly, the AtV valves are thicker than the SL valves. In addition, thickness varies within each leaflet – the base tends to be thicker than the mobile free-edged tips.(8)

The cardiac skeleton consists of dense connective tissue that contains the valve annuli (see Figure 1-10). Each annulus is a ring-like fibrous tissue attached directly to the cardiac muscle, similar to the way in which tendon attaches to skeletal muscle.(8) The annulus is the supporting ring to which the valve leaflets are attached. It functions not only as a structural support for the leaflets or cusps, but also distributes the forces into the cardiac muscle during valve operation.

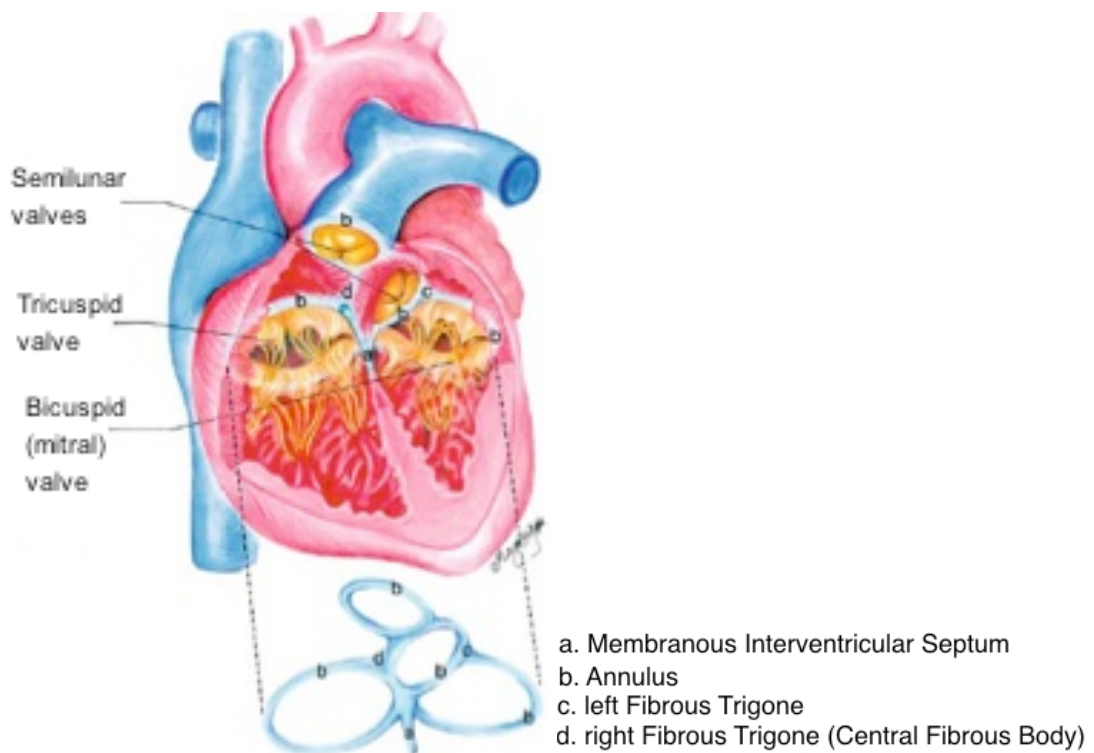


Figure 1-10: Cardiac skeleton consisting of dense connective tissue anchoring the heart valves and electrically isolating the ventricles from the atria (9)

Although the valves are active tissue, they passively open and close as a result of the forces applied to them by the blood. A pressure difference across the valves either opens or closes them. The valves have pleats called scallops that allow the

leaflets to overlap when closing, forming a zone of co-aptation called lannulae (see Figures 1-11a) and 1-11b)). This overlap causes frictional stresses between the leaflets, effectively sealing the orifice area.(18,20)

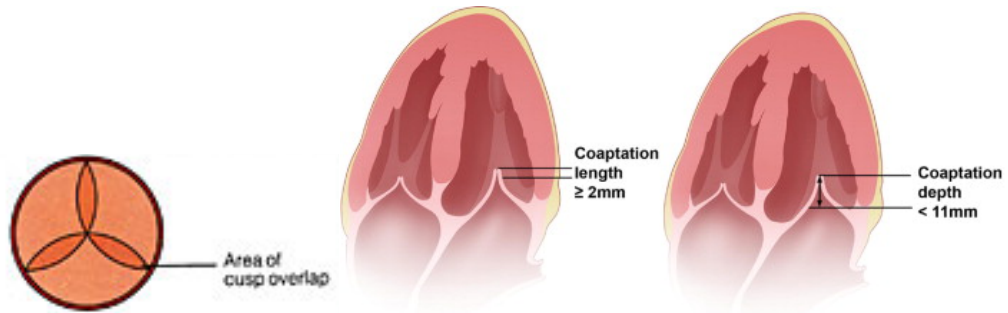


Figure 1-11a): Valve overlap during closure (21)

Figure 1-11b): Zone of co-aptation shown in atrioventricular valves of the heart (22)

The structural and compositional complexity of the valves and the continued maintenance thereof is necessary to provide this passive operating function. The valves can operate passively because their properties are suitable allowing them to move appropriately and distort throughout the cardiac cycle. Such properties have to include the leaflets' exhibiting anisotropic behaviour (their material properties vary in different directions – their radial and circumferential material properties vary). In addition, the leaflets are viscoelastic in nature, which implies that these material properties are also time-dependent. Such properties, together with the valve's inhomogeneous composition, make natural heart valves complex to mimic physiologically in a prosthetic replacement.(23,24)

Prosthetic valves, particularly for application in growth potential patients, must evaluate this passive valve function in the context of the effect it has on surrounding tissue, since the interplay between the valve and other cardiac structures is altered due to the presence of a non-native valve. The cyclic strain and stresses to which the valve is exposed throughout a lifetime allow a natural and healthy valve to remodel, adapting to the physiological requirements of the individual.(18,24) These stresses are complex, involving flexural, torsional, compression and tensional stresses, in combination with high strains (see

Figure 1-12, refer to Fig 1-7 for details on left ventricular pressure over the cardiac cycle), resulting in the elongation of the leaflets as a result of cyclic loading between unloaded and loaded states.(4,23)

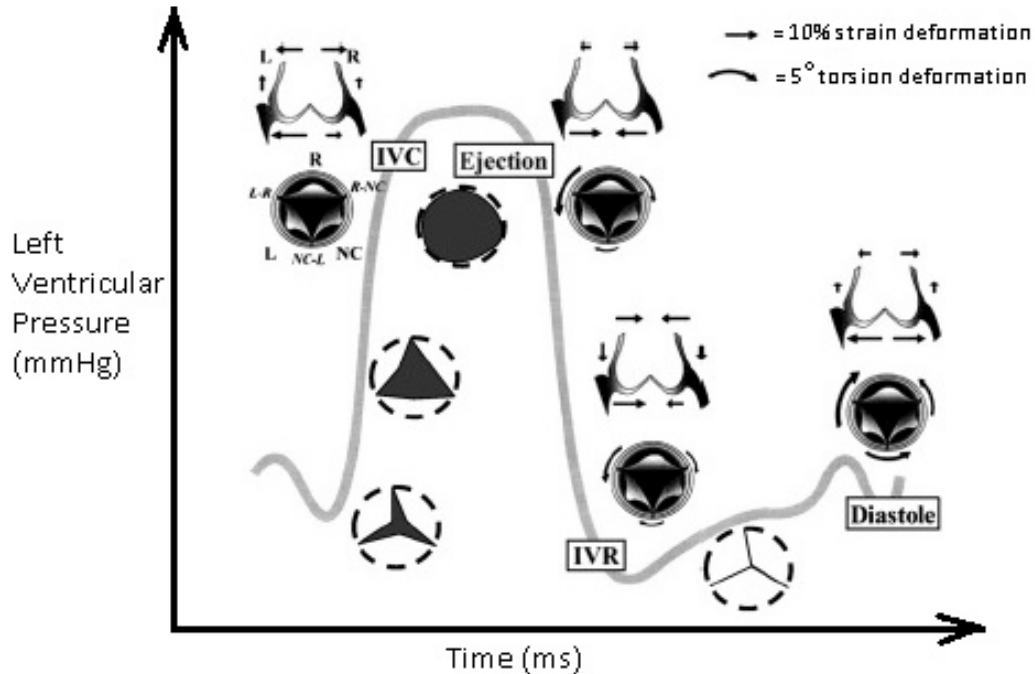


Figure 1-12: Stress and strain in an aortic valve (4)

A lack of adaptation in a prosthetic valve because it is not biologically living tissue must be considered when facing the challenge of designing a paediatric valve.

### 1.3.1 Atrioventricular Valves (AtV)

Each of the two atrioventricular valves situated between the atrium and the ventricle of both sides of the heart is considered a valvular complex or apparatus. Each complex contains leaflets, an annulus and chordae tendinae attached to papillary muscles.

The annulus is the basal area of the leaflets and provides the supporting ring to which the leaflets are attached. The annulus forms part of the cardiac skeleton, and is attached to the muscular walls of the atrium and ventricle. In turn, the ventricular muscular walls contain papillary muscles extending into the ventricles and containing connective tissue fibres (called chordae tendinae) that

attach to the leaflet's free edge. The chordae are loose when the ventricles are in diastole, allowing blood to enter them. Conversely, during ventricular systole, when blood is ejected out of the heart, the papillary muscles and chordae tendinae provide adequate tension, which helps to keep the valve closed without its prolapsing into the atrial chamber.

The leaflets are complex tissue containing some muscle and nerve cells within their collagen-based endothelial make-up. The entire leaflet obtains nutrients from the blood in its environment, as it is not adequately perfused in itself. The leaflets are thicker at the free edge where the chordae tendinae are attached and form the zone of co-aptation.

The mitral valve is a bicuspid valve with two leaflets and looks like a 'mitre' or cardinal's hat (see Figures 1-13a) and b)). The anterior leaflet is continuous with the aortic root and is semilunar in shape. The posterior leaflet is smaller in size and quadrangular in shape. Together, the leaflet surface area is twice that of that of the valve orifice area, to allow for proper co-aptation during closure.

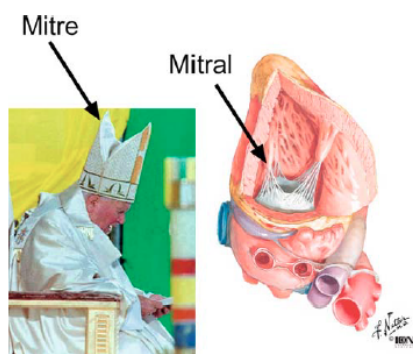


Figure 1-13: a) Mitral valve shape (9)

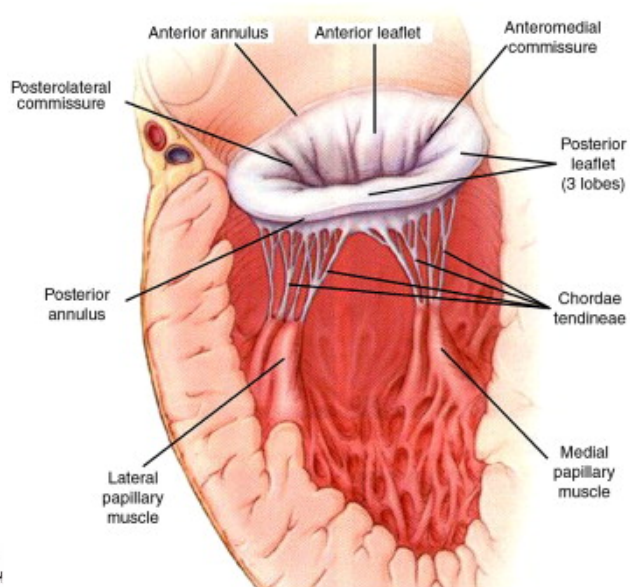


Figure 1-13b) Mitral valve anatomy (25)

The tricuspid valve has three leaflets, an anterior, posterior and septal leaflet. These are not as well defined structurally as those of the mitral valve and tend to be more structurally complex. The tricuspid valve is an anatomically larger valve, but functions in a similar manner to the mitral (bicuspid) valve, despite its exposure to lower pressures and blood flow velocities and its slightly delayed closure in comparison to that of the mitral valve (see Figure 1-14).

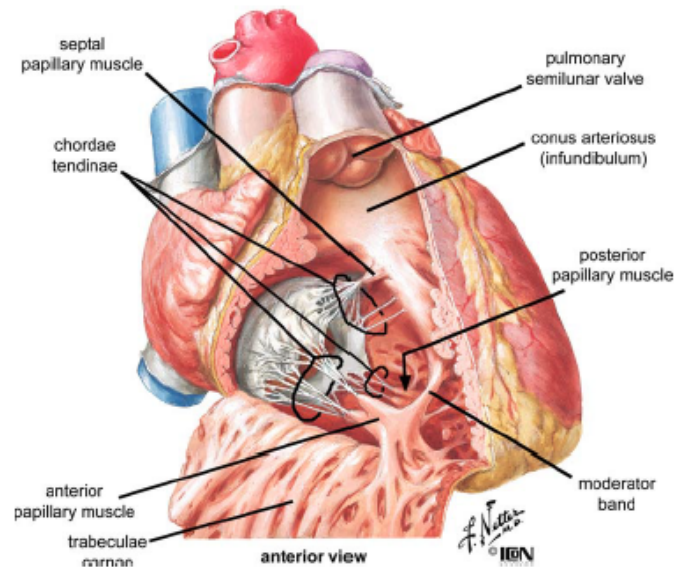


Figure 1-14: Anterior view of tricuspid valve (9)

Additional differences between the mitral and tricuspid valve are that the tricuspid valve contains three sets of subvalvular apparatus, as opposed to two in the mitral valve. The TV annulus is not in continuity with its respective semilunar valve, the pulmonary valve in the pulmonary root.(8,12,16,24,26)

### 1.3.2 Semilunar Valve (SL)

The semilunar valves are situated in the left and right outflow tracts exiting from the left and right ventricles, respectively. They are self-contained valves and consist only of the leaflets attached to the annulus. There are, however, some features that differ between the AtV and SL valves, as well as between the pulmonary and the aortic valves (see Figure 1-15, Figure 1-16 and Figure 1-17).



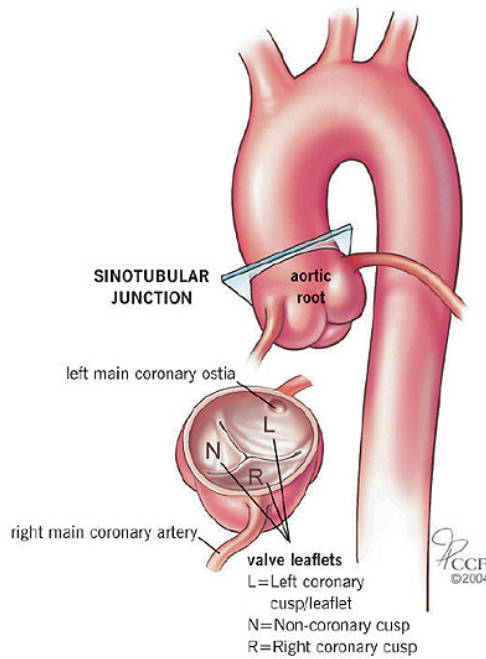


Figure 1-15a): Aortic valve in aorta (27)  
valve anatomy (26)

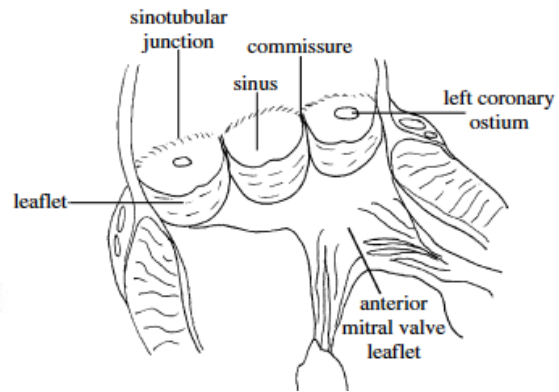


Figure 1-15b) Schematic of aortic valve anatomy (26)

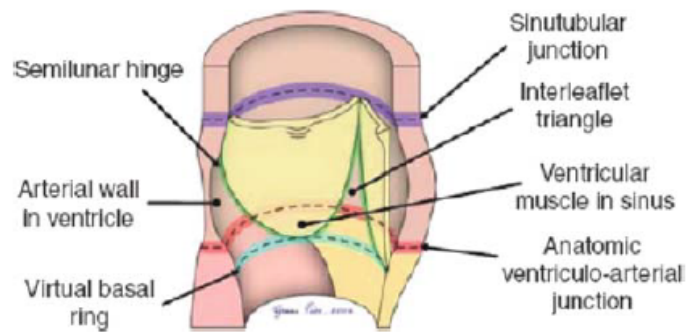


Figure 1-16: Anatomy of the aortic valve (28)

The aortic valve consists of three leaflets, each lying in bulging sinuses called the sinus of Valsalva. The sinuses together with the annulus form the aortic root (see Figure 1-16). Two sinuses each contain a coronary artery, left and right, while the remaining sinus is non-coronary. The sinuses are separated by the commissures, which also separate the individual leaflets and act as a hinge. When the leaflets are fully open, they extend into the sinus in such a way that they do not touch the aortic wall. The aortic valve is exposed to higher pressures, than the pulmonary valve, because blood passing through it must reach tissue located far away. These pressure thus cause the aortic root to expand during ventricular systole.



The pulmonary valve is subjected to lower pressures, because it is situated in the right outflow tract, where it is exposed to the pulmonary pressure above the valve and right ventricular pressure below to the valve. The valve also contains three cusps or leaflets located in three sinuses (see Figure 1-17) These sinuses are less pronounced than their aortic counterparts and contain no coronary arteries. The leaflets are constructed in the same fashion, but are slightly thinner and less stiff, and are situated in a slightly larger annulus. Other than these differences, the few other structural variations, making the pulmonary valve a popular choice as a biological valve replacement substitute for the aortic valve.(8,12,16,24,26)

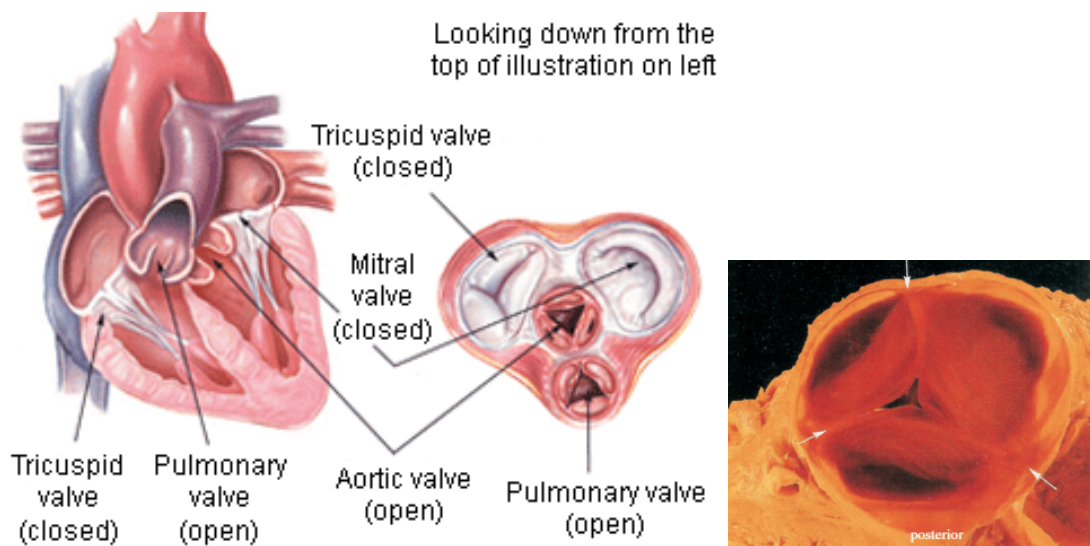


Figure 1-17a): Pulmonary valve structure and position in heart (29)

Figure 1-17b): Pulmonary valve with co-apting cusps (26)

All four valves are located in physiologically different environments despite their close proximity. Healthy valves are well adapted to deal with significant changes in haemodynamics, but poor function of one or more valve components is often seen in heart disease. Valvular disease directly affects the performance and longevity of the valves, indirectly affecting the heart's functioning as unit. The diseases that can affect the heart valves are discussed in the next chapter, Chapter Two.

## **Chapter Two: Disease and Diagnosis**

### **2.1 Introduction**

Heart disease, which includes valvular disease, affects many people of various ages. Although valvular disease is prevalent worldwide, its causes are not completely understood. Much has been written about valvular disease in adults, particularly adults over the age of 65 years. This interest is largely due to the increasing aging population in developed countries. Unfortunately, thus far, less attention has been paid to treating valve disease patients requiring valve replacement at a young age.

Although paediatric valvular disease has some underlying similarities with the forms of valvular disease found in adults, there are marked differences in disease etiology (although neither is fully understood). Understanding the effect of valve disease on a young individual not only affects surgical timing, but also the individual's clinical outcome and prognosis. It is important to link the type of disease to the appropriate treatment strategy for the condition being treated. In severe valve disease, such strategies frequently eventually lead to the need for a valve replacement.

This situation necessitates a better understanding of valvular disease pathology, in order to make it possible to treat diseased valves adequately.(24) This shows the need for a prosthetic valve designer to gain such an understanding in the context of disease progression and diagnosis, as it may alter the design approach, leading to better medical devices. Purely transferring knowledge of adult valve disease to paediatric patients will ultimately miss out on the unique disease characteristics that set children with valvular disease apart from their adult counterparts. This would be counterproductive in the search for an ideal paediatric heart valve.(15)

The aim in this chapter is to highlight the significant disease variations that may be present in young individuals and to show how these variations influence prosthetic designers in their pursuit of an ideal paediatric heart valve. The focus here is therefore not disease etiology, but rather how it affects valve function, altering the individual's life course. Nor is it necessary to focus on the large number of syndromes in which the valvular components are compromised. Instead, only syndromes that may benefit from a treatment strategy that includes valve prostheses are considered.

## **2.2 Valve structural and functional anomalies**

Valvular disease may be congenital or acquired. These two types of valvular disease are discussed below.

Acquired valvular disease suggests that the disease was attained at some point in time, for example, as a result of rheumatic valve disease, which causes valve leaflet inflammation, compromising function.(23) To date, the greatest population of patients requiring valve prostheses is found in developing countries, and they need such prostheses as a result of rheumatic disease. In developed countries, rheumatic disease has been nearly eradicated and poses a low problem, due to the ability to prevent the disease. In theory, other forms of acquired valvular disease may also be prevented where they occur as a result of surgical intervention for the treatment of other cardiac problems.(15)

Congenital heart defects are considered to contribute the most to lethal birth defects, leading to nearly 30% of preterm foetal deaths. The greatest contribution to such cardiac birth defects is valvular malformations.(4) There are various types of congenital valve anomalies that can compromise valvular function, which eventually compromises ventricular function as a result of the intricate functional interplay between cardiac structures.(8)

Valvular disease involves the dysfunction of one or more components of the valvular components: leaflets, annuli or even the tendinae chordae or papillary

muscles. The types of valve anomalies present in valve disease generally involve two types of dysfunctions, stenosis and/or regurgitation.

The first is stenosis, in which there is an obstruction to blood flowing through the valve. Stenosis, at the valvular level, usually involves fibrous thickening of the leaflets, these valves may or may not be fused to the artery walls.(30) Acquired stenotic valves are usually caused by acute rheumatic fever. Although the fever is prevalent in developing countries, it has decreased significantly in developed countries. In North America, it is estimated to be responsible for less than 10% of all acquired stenotic aortic valves.(18)

The second is valve insufficiency or regurgitation, which occurs when the valve is closed. It is associated with a lack of effective orifice sealing, resulting in retrograde or regurgitant flow (see Figure 2-1a) and Figure 2-1b)). Stenosis and regurgitation are often found to co-exist, but may also be isolated, although this is rare.

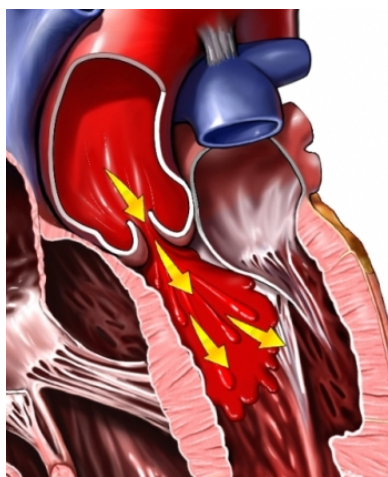


Figure 2-1a): Representation of valvular regurgitation (31)

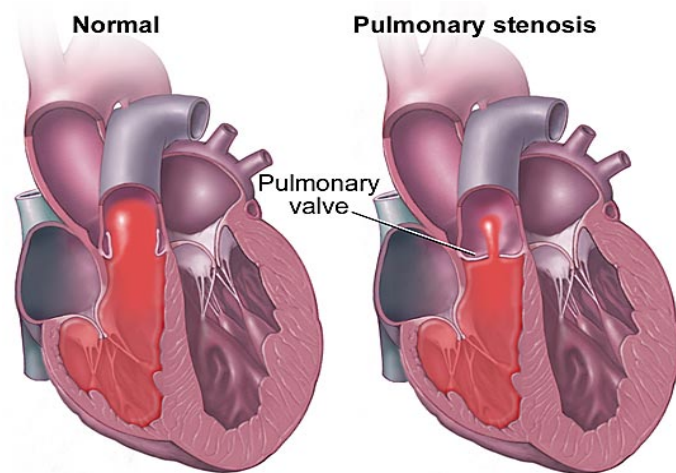


Figure 2-1b): Representation of valvular stenosis (32)

The percentages of CHD that contribute to CHVD, involving some form of valvular stenosis and regurgitation are given in Table 2-1.

<b>Percentage of Congenital Heart Disease (CHD) that involve valve abnormalities</b>		
	<b>Stenosis</b>	<b>Regurgitation</b>
<b>Mitral valve</b>	1-2.8%	< 1-2.5%
<b>Tricuspid valve</b>	Extremely rare – less prevalent than tricuspid regurgitation	Rare
<b>Pulmonary valve</b>	15-10% of cardiac malformations*	(tend to be acquired during surgical intervention)
<b>Aortic valve</b>	2-8% of infants with CHD	(mild to moderate regurgitation present in 80% of AS)

Table 2-1: Prevalence of valve abnormalities occurring in CHD (15,18,33-35)

\*Tend to be more acquired than congenital

Considering the prevalence of CHVD, valve structural abnormalities resulting in flow obstruction (stenosis) and/or regurgitation in the context of isolated defects or part of syndromes or complex malformations are discussed here. This provides crucial information relevant to designing better prosthetic valves, particularly for early life patients, as care is palliative and disease tends to progress, potentially affecting the long-term function of the prosthetic valve.

It is necessary to subcategorise paediatric valvular disease into the disease affecting neonates, infants and children. This is because disease pathology varies in relation to the age at which symptoms become evident. There may be critical considerations relevant to a neonate or infant that may not be necessary with regard to an older child. Because of the significant differences in the anatomical and physiological character of each of the four cardiac valves, it is also necessary to consider the repercussions of valvular disease for the individual valves rather than collectively. This makes valvular disease in the young very complex and difficult to understand fully. It is not necessary for a prosthetic designer or even a cardiac surgeon to understand all the possibilities fully. It is only necessary to understand the scale of the problem and be as prepared as possible for all eventualities, as surprises may occur during surgery, despite advanced diagnostic technologies.

Briefly considering the disease scale for each individual heart valve, disease is discussed here ranging from a completely stenotic valve through to an absent valve.

### 2.2.1 Aortic valve

The aortic valve is the most commonly diseased valve, in the general population, and hence is replaced the most.(18) Valvular disease in the aortic valve may be congenital or acquired and may present as either chronic or acute.(36) It may be a result of structural malformation or general valvular dysfunction. It includes aortic stenosis (AS) and aortic regurgitation (AR) or, more commonly, a combination of the two. As many as 2% of individuals born with a deformed aortic valve have noteworthy stenosis and/or regurgitation before they reach adulthood. Table 2-2 lists common causes of aortic stenosis or regurgitation.

<b>Defects associated with stenosis and regurgitation in the aortic valve</b>		
	<b>Regurgitation/insufficiency</b>	<b>Stenosis</b>
<b>Congenital</b>	<ul style="list-style-type: none"> <li>• BAV</li> <li>• Stenotic valve</li> <li>• Associated lesions:               <ul style="list-style-type: none"> <li>○ ventricular septal defect</li> <li>○ subaortic stenosis</li> <li>○ supra-aortic AS</li> </ul> </li> <li>• Syndromes:               <ul style="list-style-type: none"> <li>○ Marfan’s syndrome</li> <li>○ Ehler-danlos syndrome</li> <li>○ Tetralogy of Fallot (ToF)</li> <li>○ Reiter’s syndrome</li> </ul> </li> </ul>	<ul style="list-style-type: none"> <li>• Number of valve leaflets (cusp fusion)               <ul style="list-style-type: none"> <li>○ BAV</li> <li>○ Unicuspid</li> <li>○ Quadricuspid</li> </ul> </li> <li>• Mitral valve hypoplasia/stenosis</li> <li>• Syndromes               <ul style="list-style-type: none"> <li>○ Williams syndrome</li> </ul> </li> </ul>
<b>Acquired</b>	<ul style="list-style-type: none"> <li>• Infective endocarditis</li> <li>• Rheumatic heart disease (rare)</li> <li>• Postoperatively when native pulmonary valve is used as a neo-aortic valve</li> <li>• Myxomatous degeneration of leaflets</li> </ul>	<ul style="list-style-type: none"> <li>• Rheumatic valve disease</li> <li>• Calcification</li> </ul>

Table 2-2:List of common defects associated with AV regurgitation and stenosis (15,33,35)

Aortic valve stenosis (AS) is the most frequently found cause of left ventricular outflow tract (LVOT) obstructions, reportedly as high as 71%.(33) This is

followed by sub- and supra- valvular stenosis, obstruction below and above the aortic valve, respectively (see Figure 2-2).

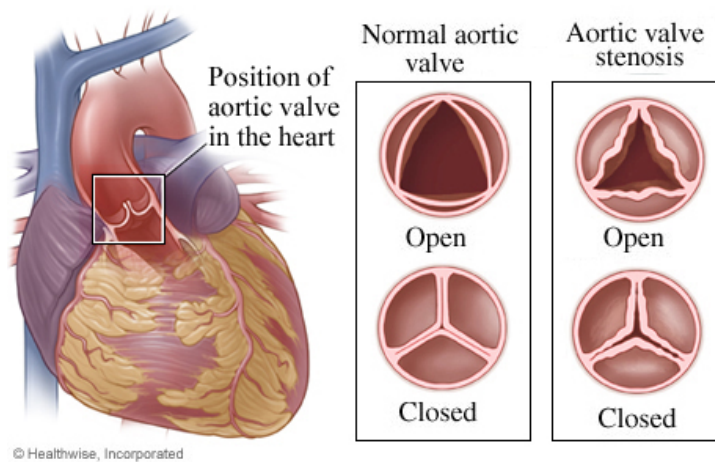


Figure 2-2: Schematic representation of normal and stenotic aortic valve, in the open and closed position (37)

LVOT obstruction contributes to as much as 10% of all CHDs.(33) This means that AS contributes up to 8% of CHD. It is more prevalent in male infants than in female infants. In 20% to 40% of cases, it is accompanied by other cardiac defects, often co-existing with mitral valve stenosis. Nearly three quarters of symptomatic patients die if the aortic valve is not replaced within three years after the initial symptoms appear.(38,39)

Stenosis in paediatric patients is often due to commissural fusion or thickened leaflets. When a valve is so severely obstructed that it is completely absent, it is termed atresia. Aortic valve atresia is rare because it is incompatible with life in the neonate. It is almost always associated with ventricular and mitral hypoplasia, as seen in hypoplastic left heart syndrome (HLHS), an underdeveloped heart. A normally developed left ventricle is found in no more than 7% of aortic atresia cases, when a ventricular septal defect is present allowing for adequate foetal growth. It is compatible with survival and is best treated surgically in the neonate.(40)

Aortic regurgitation is rarely found as an isolated lesion. It tends to co-exist with other cardiac defects including subaortic stenosis and a ventricular septal

defect. Regurgitation tends to be congenital in nature, but when it is acquired due to rheumatic disease, it is often found with mitral valve disease.(33) It tends to worsen progressively, with disease progression higher in those who present with symptoms at an early age. In addition, in chronic regurgitation, over time structural changes occur in the ventricle to compensate for the lost cardiac output during ventricular systole. Such changes include hypertrophy and dilation. Hence, patients tend to be asymptomatic until the disease has progressed considerably. However, in acute regurgitation, a patient is symptomatic and requires immediate surgical intervention, as the patient is at high risk of heart failure. Regurgitation may be a consequence of leaflet prolapse, aortic root dilation or simply compromised leaflets that do not seal adequately when closed. Individuals tend to be symptomatic only when severe regurgitation is present.(33,35,36)

A bicuspid aortic valve (BAV) is an aortic valve with two leaflets or cusps and two commissures (see Figure 2-3), instead of the normal three, and is found in up to 2% in the general population. Up to 50% of BAVs are accompanied by some cardiovascular complication.(41) BAV leads to premature valve failure, due to the early onset of stenosis and regurgitation and risk of aortic root dilation. Approximately 15% to 33% of individuals with BAV present with mild regurgitation, while a mere 4.5% experience moderate to severe regurgitation. Such patients tend to be slightly older, 9.2 years, and only require valve replacement in adolescence. Aortic stenosis is seen in 75% of BAV patients, while mixed AR and AS is present in 10%. Thus BAV contributes considerably to the need for surgical intervention at a young age. Some BAV morphology findings are more likely to require intervention than others.(28,36,42,43)



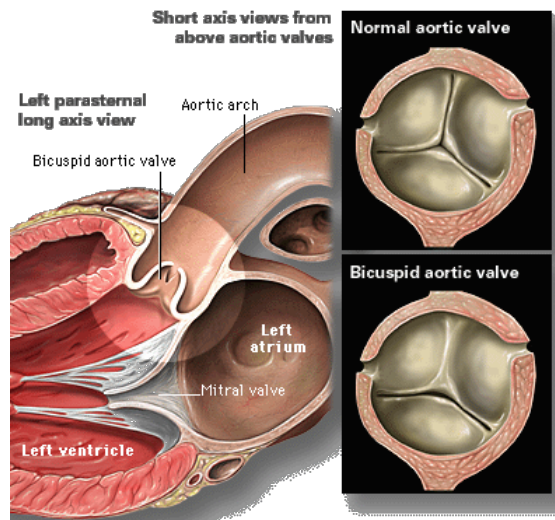


Figure 2-3: Bicuspid aortic valve with two fused leaflets creating a two leaflet aortic valve(44)

### 2.2.2 Pulmonary valve

Pulmonary valve disease (PVD) is more rare than BAV but contributes more to the incidence of CHD than mitral and tricuspid valve disease. It can occur as an isolated lesion or as part of syndromes such as Noonan's syndrome, Shone's syndrome and in the very rare Allagille syndrome. PVD includes stenosis, atresia, regurgitation and an absent valve. Often stenosis and regurgitation may co-exist.(45) See Table 2-3 for a list of common defects associated with pulmonary regurgitation and stenosis.

Pulmonary valve stenosis (PS) has a higher prevalence than AS and constitutes roughly between 5% and 10% of cardiovascular malformations as an isolated lesion. When PS is isolated, no ventricular septal defect is present. Like AS, PS may be subvalvular, supra-avalvular or valvular. In valvular stenosis, PS may be due to leaflet dysplasia with a thickened annulus, or more commonly commissural fusion.(15,46)

Defects associated with stenosis or regurgitation of the pulmonary valve		
	Regurgitation/insufficiency	Stenosis
<b>Congenital</b>	<ul style="list-style-type: none"> <li>• Absent pulmonary valve</li> <li>• Syndrome: <ul style="list-style-type: none"> <li>○ ToF</li> </ul> </li> <li>• Secondary to pulmonary hypertension</li> </ul>	<ul style="list-style-type: none"> <li>• Annulus and valvular hypoplasia</li> <li>• Ventricular septal defect</li> <li>• Transposition of the great arteries</li> <li>• Tricuspid atresia</li> <li>• Dysplastic valves</li> <li>• Syndromes <ul style="list-style-type: none"> <li>○ Noonan's syndrome</li> <li>○ ToF</li> <li>○ Alagille syndrome</li> </ul> </li> </ul>
<b>Acquired or Iatrogenic</b>	<p>(More often acquired than congenital)</p> <ul style="list-style-type: none"> <li>• Result of treatment for RVOT obstruction</li> </ul>	<ul style="list-style-type: none"> <li>• Acquired as a result of other cardiac surgical treatment</li> </ul>

Table 2-3: List of common defects associated with pulmonary valve stenosis or regurgitation (39,47)

Pulmonary valve atresia (see Figure 2-4), the severest form of stenosis, is often associated with syndromes. It is found in up to 20% of patients with Tetralogy of Fallot (ToF), but contributes less than 1% of all CHDs, and a slightly higher percentage, 2.5%, in critically ill infants. When it is found as an isolated lesion, which is with no ventricular septal defect, it contributes to 3.1% of CHD.(33)

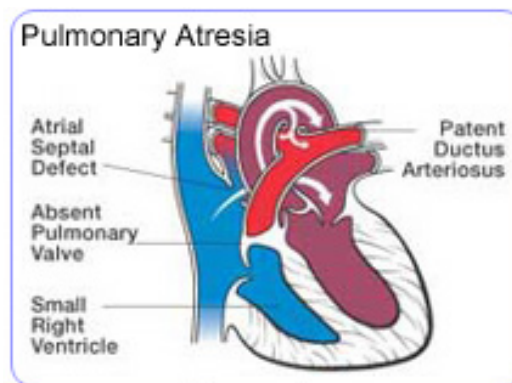


Figure 2-4: Pulmonary atresia (48)

Pulmonary valve regurgitation (PR) usually occurs as a result of previous surgical intervention when treating other cardiac structures. This is often a consequence of treating ToF, but regurgitation then progresses over the

individual's lifetime and only presents with symptoms at a much later stage. The progressive nature of regurgitation leads to changes in the right ventricle, leading to dilation and dysfunction due to ventricular overload.(49) An absent pulmonary valve (see Figure 2-5) is the severest form of regurgitation, as there is no resistance to blood flow. Hence, it is regurgitation in its purest form and is associated with ToF, despite an absent pulmonary valve only contributing to 2% of ToF cases.(33)

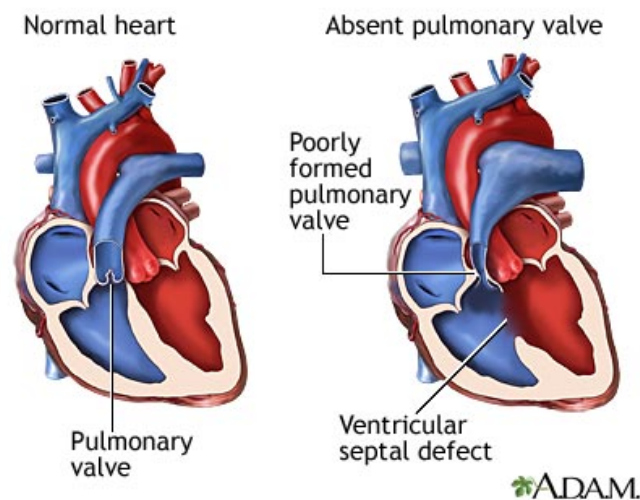


Figure 2-5: Absent pulmonary valve with ventricular septal defect (50)

### 2.2.3 Mitral valve disease

Mitral valve defects are rare and only present in 1% to 2.8% of CHD patients.(39) Abnormalities can result in regurgitation or stenosis, possibly atresia, although this is rare, because atresia is incompatible with life. All components of the valvular apparatus can be affected, leading to dysfunction. See Table 2-4 for a list of common defects associated with mitral stenosis and regurgitation.

Mitral stenosis (see Figure 2-6) (MS) is less prevalent than regurgitation in the paediatric population, although congenital mitral regurgitation occurs less than congenital MS. This is most likely to be due to rheumatic fever, commonly

involving the mitral valve in up to 95% of cases, usually causing regurgitation.(15,33)

Defects associated with stenosis or regurgitation of the mitral valve		
	Regurgitation/insufficiency	Stenosis
<b>Congenital</b>	<ul style="list-style-type: none"> <li>• Syndromes               <ul style="list-style-type: none"> <li>○ Ehler-Danlos – MVP</li> <li>○ Marfan’s syndrome – MVP</li> <li>○ Stickler syndrome - MVP</li> </ul> </li> </ul>	<ul style="list-style-type: none"> <li>• Septal defects               <ul style="list-style-type: none"> <li>○ ventricular</li> <li>○ atrial</li> <li>○ atrioventricular</li> </ul> </li> <li>• Co-arctation of the aorta</li> <li>• Double outlet right ventricle</li> <li>• Single ventricle</li> <li>• Subvalvular aortic stenosis</li> <li>• Aortic valve stenosis</li> <li>• Number of valve leaflets</li> <li>• Transposition of the great vessels</li> <li>• Syndromes               <ul style="list-style-type: none"> <li>○ ToF</li> <li>○ HLHS</li> <li>○ Down’s syndrome</li> </ul> </li> </ul>
<b>Acquired</b>	<ul style="list-style-type: none"> <li>• Rheumatic fever</li> </ul>	<ul style="list-style-type: none"> <li>• Rheumatic valve disease</li> <li>• Connective tissue disorders</li> <li>• Endocarditis</li> </ul>

Table 2-4: List of common defects associated with mitral valve stenosis and regurgitation (39,45)

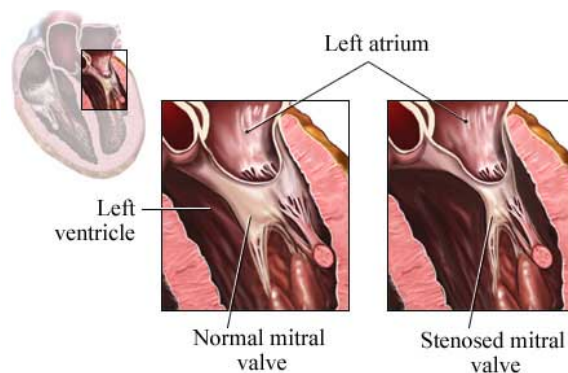


Figure 2-6: Schematic representation of mitral stenosis with narrowed orifice area (51)

MS as an isolated lesion is extremely rare, making up only a fraction, 0.5%, of congenital heart defects. Mostly, it is associated with HLHS or Shone’s syndrome

and atrioventricular septal defect, although it can also be a result of rheumatic heart disease or acquired calcification. Congenital stenosis occurs as a result of commissural fusion or chordae dysfunction. When the valve is occluded, little blood can flow into the left ventricle, which then affects cardiac output. To compensate for this, the heart enlarges hypertrophically to increase its pumping power. MS is progressive and tends to worsen dramatically in adulthood. If MS is rheumatic in nature, it may take 10 to 40 years before symptoms become apparent.(33,38,52,53)

Mitral regurgitation (MR) may be a result of dysfunctional valve leaflets, papillary muscles and/or chordae tendinae. The mitral valve is most commonly affected because of rheumatic heart disease, leading to regurgitation. MR in congenital disease tends to be associated with an atrioventricular canal defect. MR is generally due to the valve leaflets' prolapsing into the left atrium, referred to as a floppy mitral valve (see Figure 2-7). This is the most common atrioventricular defect. Although MR is prevalent in adults (7% of general population) it is much less prevalent in healthy children (0.7% of healthy teenagers). However, in the overall paediatric population, it is found in 2% to 5% of individuals. It is twice as prevalent in female individuals as in male individuals, and is increasingly common with age. It is often seen in individuals with Marfan's syndrome (40% to 91% of Marfan's syndrome cases). Overall MR is only severe in 50% of MR cases and almost always requires surgical intervention. When it is severe, it is associated with a mortality of 22% at 5 years.(18,45,53-55)

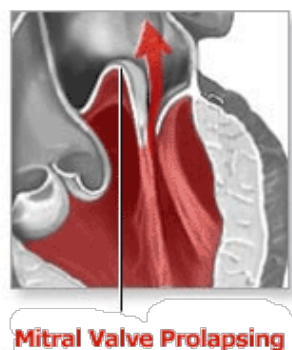


Figure 2-7: Schematic representation of mitral valve regurgitation due to leaflet prolapse(56)

### 2.2.4 Tricuspid valve

Tricuspid valve disease is seldom focused on in research, as it is more rare than other valve diseases. Disease findings in older children are similar to those for adults. However, the disease in the neonate, infant and young child does vary from that in adults. As with other valve diseases, tricuspid valve disease can result in stenosis or regurgitation or a combination of the two. Atresia of the tricuspid valve may also be seen and is prevalent in 1% to 3% of congenital heart defects, with few surviving beyond 6 months without surgical intervention. Tricuspid valve involvement in association with Ebstein's anomaly is found in less than 1% of all congenital heart defects. A list of common causes leading to tricuspid regurgitation and stenosis is given in Table 2-5. (33,39,47)

<b>Causes of stenosis or regurgitation in Tricuspid valve disease</b>		
	<b>Regurgitation/insufficiency</b>	<b>Stenosis</b>
<b>Congenital</b>	<ul style="list-style-type: none"> <li>• Critical pulmonary stenosis</li> <li>• Pulmonary atresia with intact ventricular septum</li> <li>• Dysplastic tricuspid valve</li> <li>• Syndrome               <ul style="list-style-type: none"> <li>○ Ebstein's anomaly</li> <li>○ ToF</li> </ul> </li> </ul>	<ul style="list-style-type: none"> <li>• Critical pulmonary stenosis</li> <li>• Pulmonary atresia with intact ventricular septum               <ul style="list-style-type: none"> <li>○ Down's syndrome</li> </ul> </li> </ul>
<b>Acquired</b>	<ul style="list-style-type: none"> <li>• RV disease</li> <li>• Acquired after surgical intervention for CHD</li> </ul>	<ul style="list-style-type: none"> <li>• RV disease</li> <li>• Acquired after surgical intervention for CHD</li> </ul>

Table 2-5: List of common causes of tricuspid valve stenosis or regurgitation as a result of disease (33,39)

Stenotic disease of the tricuspid valve, tricuspid stenosis (TS), is commonly rheumatic, found in over 90% of all cases. It tends to be associated with mitral valve disease, whether regurgitant or stenotic in nature, although they are associated with only 3% to 5% of mitral valve disease individuals who present with TS. As with MS, any one or more aspects of the valvular apparatus may be affected. This includes leaflet thickening and chordae shortening. Individuals with severe TS who require valve prosthesis contribute minimally to the valve replacement population.(57)

Tricuspid regurgitation (TR) is slightly more frequent, although still rare, and it almost never occurs as an isolated lesion. It is usually not due to structural defects and presents rather as a functional disorder. It is possible that an individual can live a healthy life even with severe regurgitation. It is often seen in individuals with Ebstein's anomaly, in 14% to 80% of individuals with pulmonary valve stenosis or atresia, or in 30% of patients with mitral valve prolapse. As is the case with MV disease, any aspect of the valvular apparatus may be affected. Acquired TR is often found in patients with ToF who have undergone surgical intervention. Hence TR is a resulting morbidity due to surgical intervention for other cardiac defects.(39,47,57)

Tricuspid atresia is a common tricuspid valve defect (see Figure 2-8). It is a cyanotic CHD, in other words a disease associated with poorly oxygenated blood circulation, and is thus associated with a ventricular septal defect. It is found in 0.3% to 3.7% of CHD patients, making it the third most common form of cyanotic CHD. Nearly a fifth of atresia valve individuals have a co-existing defect. As with all other atresia valves, tricuspid atresia is incompatible with life, because once the ductus arteriosus closes after birth, blood cannot enter the pulmonary circuit to be oxygenated. The condition always requires surgical intervention.(58)

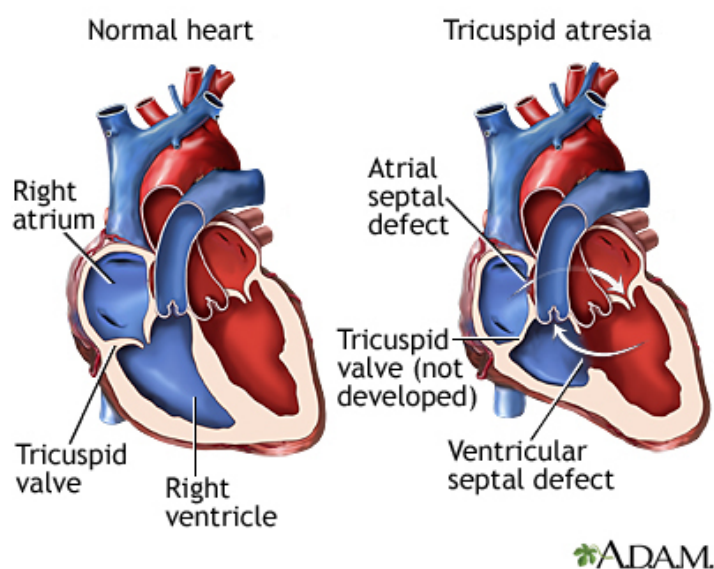


Figure 2-8: Tricuspid atresia (59)

Although valve calcification leads to stenotic valves, is it commonly found in diseased adult valves and is associated with valve degeneration and disease progression related to ageing.

### **2.3 Syndromes: complex anomalies**

It is important not only to have a basic understanding of isolated valvular defects but also to have an overview of the more complex syndromes that may require prosthetic heart valve replacement at some point, because the nature of some syndromes may place surgical limitations on valve replacement procedures, which then has a knock-on effect on the development of the associated technology.

Valvular defects or lesions may involve any one or more structures of the valvular complex. Typical defective structures may be the annulus, leaflets and/or tension apparatus. Malformed valves present in the young foetus often lead to other associated cardiac defects that may involve the ventricular and/or atrial chambers, as well as the surrounding muscle.

In addition, valvular defects may be present as part of complex multiple cardiac malformations that appear in syndromes such as Hypoplastic Left Heart Syndrome (HLHS), Ebstein's anomaly, Marfan's syndrome and many more.(23)

A list of syndromes affecting cardiovascular structures where the valve is structurally or functionally malformed or impaired is provided in Table 2-6. The individual syndromes are briefly discussed after the table.



<b>Disorder or syndrome</b>	<b>Disorder</b>	<b>Valve lesion</b>	<b>Prevalence</b>
<b>*Tetralogy of Fallot</b>	Congenital malformation	Pulmonary stenosis	1 in 3 600 live births
<b>*Hypoplastic Left Heart Syndrome</b>		Mitral and/or Aortic valve stenosis	1% to 2% of congenital heart defects
<b>*Ebstein's anomaly</b>		Tricuspid regurgitation	1% of congenital heart defects 1-5 in 20 000 live births
<b>Shone's Complex</b>		Dysplastic Aortic or pulmonary valve	<100 cases reported worldwide
<b>Marfan's</b>	Connective tissue disorder	MVP, BAV, CSVD	1 in 10 000 births
<b>Ehlers-Danlos</b>		AV and MV disease	1 in 250 000 live births
<b>Williams syndrome</b>	Genetic mutation or autosomal condition	AV stenosis, CSVD, MV defects	1 in 10 000 births
<b>Noonan's syndrome</b>		PV stenosis, MV abnormalities, polyvalvular dysplasia	1 in 1 000-2 500 live births
<b>Trisomy 21/Down's</b>		MV and TV anomalies	1 in 650-1 000 live births
<b>(Holt-Oram)</b>		MVP, PV stenosis	Rare
<b>(Turner)</b>		BAV, MVP	1 in 2 500-3 000 (Females only)
<b>(Stickler)</b>		MV dysfunction, MVP	1 in 7 500-900 live births

Table 2-6: Syndrome affecting cardiac structures including valve(s) (4,33,41,45,60-64)

\*Involves other cardiac malformations not exclusive to the valvular structures

### 2.3.1 Tetralogy of Fallot

Tetralogy of Fallot (ToF) is rare, as it occurs only once in every 3 600 live births. Despite this low incidence, it comprises 3.5% of children with congenital heart disease.(65,66) Some studies claim that the occurrence of ToF may be as high as 15% in individuals with CHD.(67) In addition, it comprises 10% of all cyanotic CHD.(49)

ToF, although a rare disorder, is reported to be found in 5% to 15% of the congenital heart disease population.(46,67) It is the greatest contributor to cyanotic congenital diseases. It is largely dependent on the functioning of the ductus arteriosus. Closure of this duct in patients with ToF results in the characteristic 'blue baby' symptoms, leading to poor development. Symptoms can be present in the first week of life, but may also become apparent later, usually anything up to the 12<sup>th</sup> week after birth.(68)

Four anatomical structures are affected by the disorder and it is the degree of one or more of these abnormalities that defines the severity of the disorder. The structures affected are

- the right ventricular outflow tract (obstruction);
- the ventricular septum (ventricular septal defect );
- the aorta (overriding/displaced aorta directly above the septal defect); and
- the right ventricle (right ventricular hypertrophy).

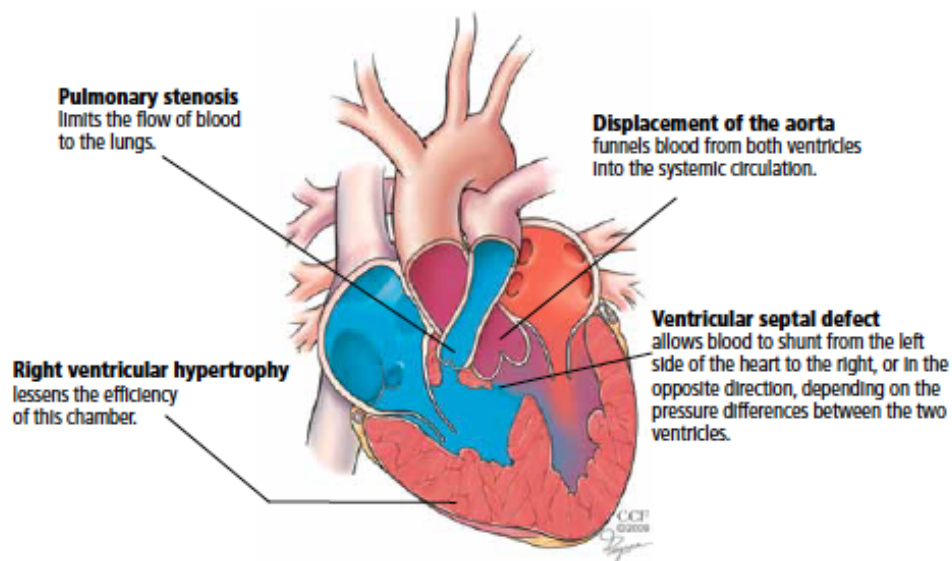


Figure 2-9: Schematic of congenital malformation in ToF (49)

These structural abnormalities occur during foetal development in the formation of the right ventricular infundibulum forming the right outflow tract. In the ToF, the infundibular septum forming the septal wall between the left and right outflow tract is misaligned, causing obstruction of the RVOT. In addition,

an interventricular septal defect is created: a hole in the wall connecting the left and right ventricles, exposing both ventricles to almost identical pressures. This defect allows deoxygenated blood from the right ventricle to be shunted to the left, entering the ventricle and the displaced aorta positioned directly above the ventricular septal defect. This mixing of oxygenated and deoxygenated blood can result in an overall oxygen saturation in the systemic circuit of less than 60%, resulting in the characteristic 'blue baby' symptoms.(67)

A feature of the disorder is not only poor systemic circulation but also poor pulmonary circulation, due to the obstructive nature of the RVOT.(65) The degree of obstruction in the pulmonary artery may vary, but often affects the pulmonary valve.(67) This obstruction causes a decrease in pulmonary blood flow that leads to right ventricular hypertrophy.

Although the pulmonary valve is mainly involved, the aortic root and annulus are often enlarged, resulting in aortic regurgitation, and mitral valve stenosis may also be found. There are variations of ToF, including ToF with pulmonary atresia (ToF-PA) or an absent pulmonary valve (ToF-APV). ToF with pulmonary atresia involves a severely or completely blocked pulmonary valve. This form contributes to 20% of all ToF individuals, but only makes up about 3.4% of all congenital heart diseases. It is therefore a rare condition with a low incidence of 0.07 in 1 000 live births. This severe form of ToF is very serious, because once the ductus arteriosus closes postnatally within the first 48 hours of life, severe cyanosis or even death may occur.(69,70)

The rarest form of ToF, the ToF-APV, involves an absent pulmonary valve including minimal RVOT obstruction where there is little to no blood flow restriction past what would be the pulmonary valve. This results in severe pulmonary regurgitation. It occurs in up to 6% of ToF cases but only constitutes a small percentage, 0.4%, of all CHD patients.(65,66,70)

Although there are variations in the reported incidence of ToF, ranging from 3.5% through 6% to 10% and even 15%, it is still a common congenital defect

with severe consequences, potentially leading to early death in the neonate. Today the survival rate well into adulthood is high, with 90% reaching 40 years of age, despite the 6% risk of 'sudden cardiac death' by 30 years of age.(49)

ToF is repaired within the first two years of life, after which the repaired ToF is considered a regurgitant lesion.(71)

### 2.3.2 Hypoplastic Left Heart Syndrome

Hypoplastic left heart syndrome (HPLHS) is found in 1% to- 2% of congenital heart defects. It involves left ventricular hyperplasia, aortic and/or mitral stenosis, and hyperplasia of the ascending aorta and aortic arch. Valvular stenosis may be so severe that it presents as atresia valves. HLHS is likely to be formed due to malformations in the valves that lead to an underdeveloped left heart, particularly the ventricle (see Figure 2-10).

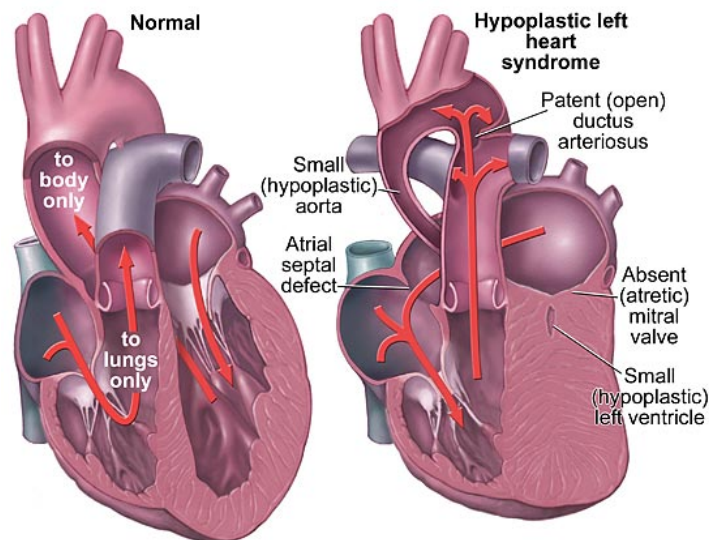


Figure 2-10: Schematic of Hypoplastic Left Heart Syndrome (72)

This syndrome is associated with high mortality, with 95% of neonates dying within the first month of life. This makes it the most common cause of death due to cardiac failure in the neonate. Death occurs because of the cyanotic nature of the disease, when the body has to rely solely on the patent ductus arteriosus for the systemic blood flow necessary for survival. Complex procedures can be

performed to treat the symptoms, but due to the severely underdeveloped heart, transplantation is often required. Today, thanks to complex procedures, nearly 70% of individuals born with HLHS can survive to adulthood. (33,62,73,74)

### 2.3.3 Ebstein's anomaly

Ebstein's anomaly occurs in 1 to 5 in every 20 000 live births, making up 1% of all congenital heart defects. It involves an enlarged right atrium with a shifted septum resulting in a right ventricle that is small and undefined. The tricuspid valve is malformed in such a way that it is displaced, so that it prolapses into the RVOT, because of the dysfunctional chordae tendinae. Due to the prolapse, the valve may partially obstruct the pulmonary artery (see Figure 2-11).

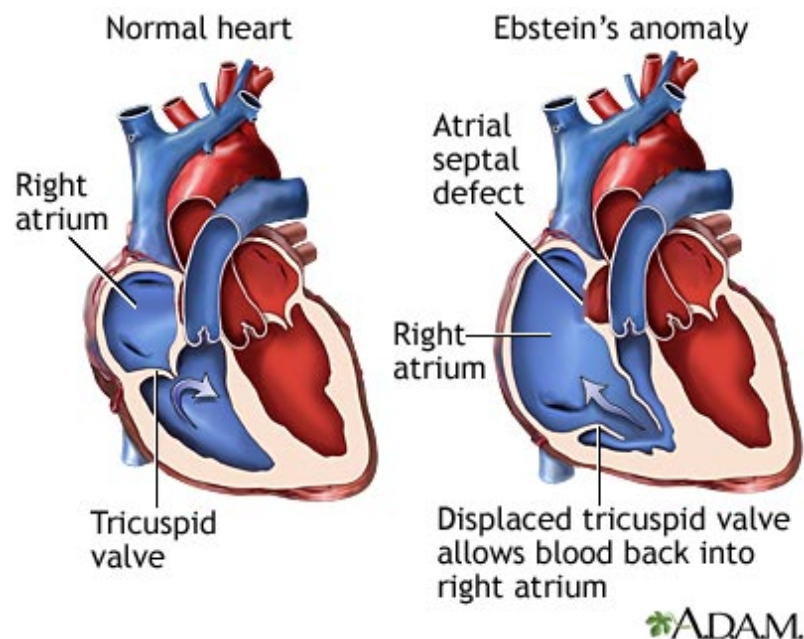


Figure 2-11: Schematic of Ebstein's Anomaly (75)

Ebstein's anomaly is a cyanotic disease, because of right to left shunting through an atrial septal defect. This causes a reduction in the blood volume output of the right side of the heart. This means that a neonate suffering from the disorder is dependent on the ductus arteriosus for adequate pulmonary flow to the lungs to counteract the reduction in right ventricular blood flow output. There is a

small but persistent risk of death in individuals who survive into childhood.(39,73)

#### **2.3.4 Shone's complex**

Shone's complex is an exceptionally rare syndrome, with only 100 cases reported worldwide. There are varying degrees of Shone's complex, in its complete form it involves four lesions, the supramitral ring, the parachute mitral valve, subaortic stenosis and co-arcuation of the aorta. Shone's complex may also present as an incomplete form, presenting with two or three lesions of the four lesions present in the complete form of the disorder. Mitral valve malformations include congenital mitral stenosis, fused chordae and a single papillary muscle. The aorta could also be bicuspid and could be stenotic at the valvular level, contributing to obstruction of the LVOT.

Patients tend to be diagnosed with Shone's complex before the age of 2 years (few if any have been diagnosed in adulthood). Early intervention is preferred before the onset of pulmonary hypertension results in heart failure. When the condition is treated, valve replacement is avoided if possible – surgical repair of the mitral valve is the procedure of choice.(76)

#### **2.3.5 Marfan's syndrome**

Marfan's syndrome is an inheritable connective tissue disorder present in 1 in every 10 000 individuals.(5) The disorder is degenerative and may take years to present any symptoms.(77) It is systemic in nature, affecting any anatomical structure with connective tissue, not only that of the heart, but also that of the skeleton and eyes.(15,78) It is thus clear that this disease is not isolated to one valve in particular, but tends to be polyvalvular, usually affecting the aortic and/or mitral valve, but also the pulmonary outflow tract. Regardless of the valve affected, the clinical findings show varying degrees of regurgitation; particularly mitral and/or aortic regurgitation. It is thus considered a regurgitant lesion.(71)

Aortic regurgitation occurs as a result of a lack of elastic fibres due to the nature of this hereditary connective disorder. This lack in elastic fibres causes the aortic wall to be thinner than usual, affecting its compliance. The aorta dilates at the sinus of Valsalva and at the aortic root located at the proximal tubular end, resulting in a “water balloon” appearance. This affects the sinotubular junction and causes the leaflets to stretch, creating a central gap, resulting in aortic regurgitation. Aortic regurgitation occurs as a result of valve dysfunction due to aortic root disease, a subvalvular disease, which is one aspect of Marfan’s syndrome.

Mitral regurgitation occurs as a result of mitral valve prolapsed, better known as floppy mitral valve or Barlow’s disease. It is present in up to 64% of Marfan’s syndrome individuals, occurring at an average age of 9.7 years. In the first year of life, it is valvular dysfunction that contributes most to the disorder’s high mortality and morbidity statistics.(15)

Complications associated with the disease once the heart is affected include “unpredictable dissection at an early size” and hence it is recommended that patients be treated at an early stage, before significant damage has occurred.(5)

### **2.3.6 Ehler-Danlos Syndrome**

Ehler-Danlos syndrome is a connective tissue disorder, of which there are many forms. Not all forms involve the cardiac structure: only Type IV said to affect the cardiac valve and present a serious risk of arterial rupture. This syndrome is rare, and the vascular form is not common (the vascular form is only found in 1 in every 250 000 people). The disorder has a similar affect on the cardiac structures as Marfan’s syndrome, causing valvular dysfunction affecting the aortic and mitral valves. Aortic root disease causes regurgitation, while the mitral valves are often prolapsed to varying degrees, in 1 in every 8 individuals with Ehler-Danlos syndrome. This collagen-vascular disease can cause premature death if the disorder is severe.(4,14,15,79)

### **2.3.7 Williams syndrome**

Williams syndrome is a genetic disorder involving an elastin gene mutation. It is found in 1 in every 10 000 births and individuals may have some or other form of cardiovascular abnormality. Generally, supravalvular AS is found in 70% of Williams syndrome individuals, of whom 30% will need cardiac intervention. Other cardiac defects include SL, AV and MV defects. The aortic valve may be bicuspid and/or stenosed. Mitral valve prolapse is seen in nearly a fifth of Williams Syndrome individuals. In addition, PS may be present but is not commonly found and if found tends to co-exist with RV hypertension. (4,39,45,73,80,81)

### **2.3.8 Noonan's syndrome**

Noonan's syndrome is a genetic disorder, which is difficult to diagnose throughout the individual's life. It occurs 1 in 1 000 to 2 500 live births. There is no distinct pattern in its presence; it tends to be sporadic in nature. Cardiac involvement includes pulmonary valve stenosis, with dysplastic leaflets in 50% to 62% of individuals with the syndrome. Valve dysplasia can cause regurgitation and/or stenosis and is characterised by thickened valve leaflets and annulus. Other defects include atrial septal defect, atrioventricular canal defects and MV anomalies. Individuals with Noonan's syndrome should be monitored throughout their lifetime for cardiac disease progression. If necessary, surgical intervention can be undertaken, but little has been said in the literature of the need for valve replacement.(30,82)

### **2.3.9 Trisomy 18 and 21**

Trisomy 18 or Edward's syndrome, a genetic disorder, is reported to have associated cardiac defects. In 93% of individuals with this syndrome, associated polyvalvular disease occurs, and in 75% of cases all four valves are affected.

Trisomy 21, more commonly known as Down's syndrome, is the most common genetic disorder causing heart defects. As many as 40% to 50% of individuals



with Down's syndrome have some form of cardiac defect. These defects usually involve the septum, but also include ToF and atrioventricular canal defects involving the MV and TV. In some rare cases, aortic stenosis may occur. Congenital heart defects cause 13% of deaths in the paediatric Down's syndrome population.(30,39,45,61,73,83)

## 2.4 Cardiac imaging technology for diagnosing disease

Valvular heart disease is often stumbled upon when treating symptoms for other diseases. When symptoms are evident, an in-depth physical examination is done and the patient history is noted. Symptoms that indicate that there may be cardiac problems include fatigue, angina and syncope in the case of valvular stenosis. In a neonate, growth retardation due to poor feeding is a sign of heart failure with associated valvular stenosis. With regurgitation, common symptoms include chest pain, dizziness, syncope and palpitations.(39)

After physical examination and upon symptom presentation, the presence of valvular defects resulting in regurgitation and/or stenosis is commonly confirmed with ultrasound, termed echocardiography (see Figure 2-12). It allows structural defects and haemodynamics (when using colour Doppler) to be assessed.

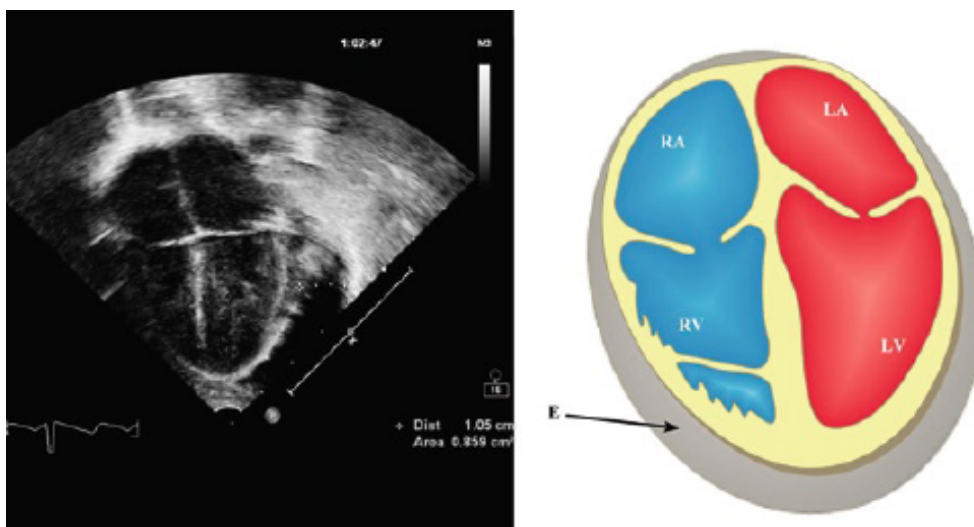


Figure 2-12: Two dimensional echocardiography with Doppler (83)

Echocardiography can be performed through the thorax and is a non-invasive technique, called transthoracic echocardiography (TTE). Despite this advantage, it does not always provide for highly detailed imaging of the heart due to the air in the lungs that reflects and distorts the signal. In addition, it may be difficult to view the anatomical features situated posteriorly.(36,39,84) To overcome this problem, transesophageal echocardiography (TEE) may be used. It provides for better image resolution, as it can view the cardiac structures directly without interference from the motion and air in the lung. The disadvantage of TEE is that it requires the ultrasound probe to be inserted into the oesophagus (see Figure 2-13) and hence becomes an invasive imaging modality. This invariably requires general anaesthesia.(83)

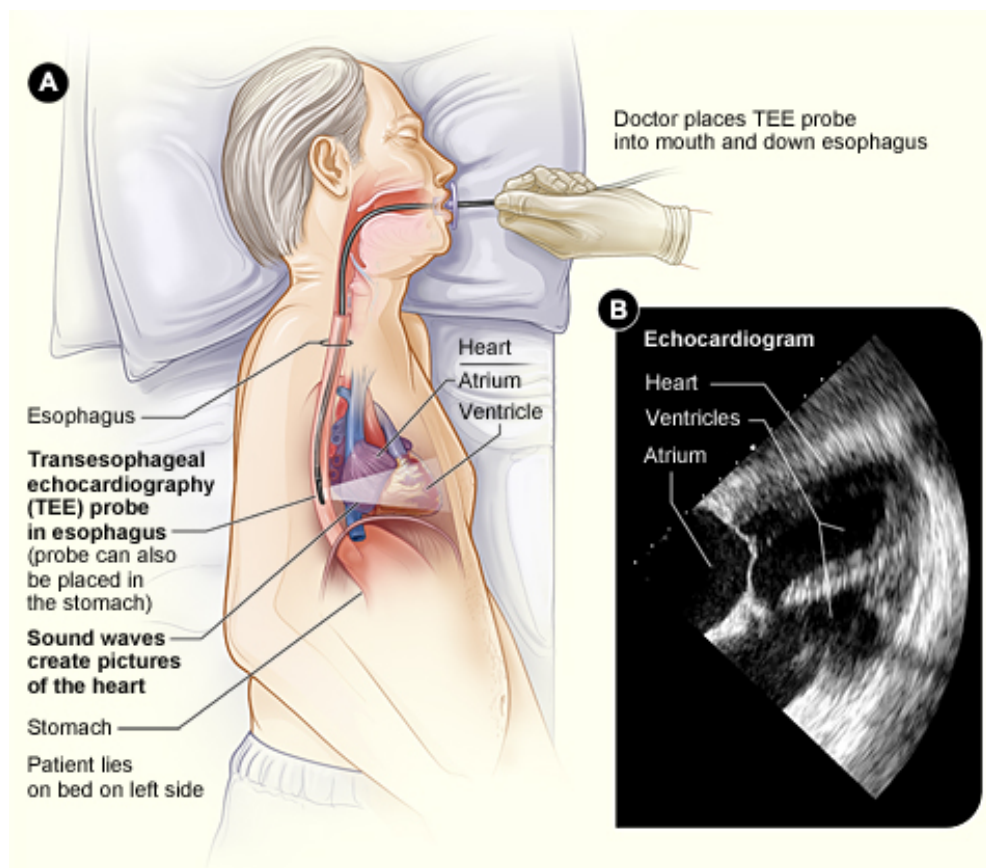


Figure 2-13: Transesophageal Echocardiography (TEE) procedure with ultrasound image of the heart and its chambers(85)

Three-dimensional TEE (see Figure 2-14) is increasingly used and provides even better imaging of the cardiac structures. It is particularly useful in

diagnosing defects with the atrioventricular valve due to their complex anatomy.

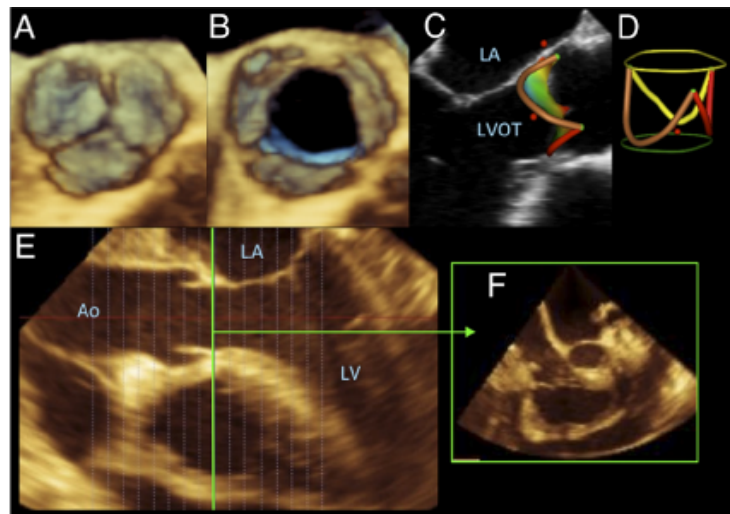


Figure 2-14: Three dimensional TEE (86)

Cardiac catheterization may be a last resort when TTE and TEE do not provide adequate information to make a diagnosis. It involves inserting a catheter into a major artery or vein and feeding it into the heart to view the anatomic structures from within (see Figure 2-15). This imaging modality comes with its own procedural complications. Such complications include the risk of vascular injury, cardiac perforation, cardiac valve injury, stroke and potential death (although such complications are rare). Direct pressure measurement cardiac catheterization has largely been replaced with three-dimensional TTE and cardiac magnetic resonance imaging (MRI). TEE is considered less invasive, although both, TEE and cardiac catheterization, require general anaesthesia.(86,87)

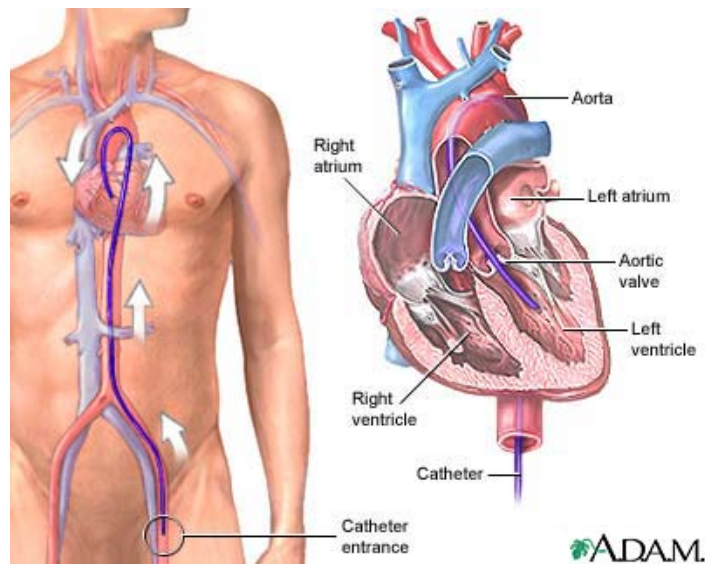


Figure 2-15: Cardiac Catheterisation via the femoral artery (88)

Diagnostic imaging is advancing at a rapid pace, with more accurate and minimally invasive imaging techniques becoming a reality in diagnosing CHD as early on as during foetal development. Such advanced imaging techniques can also be an invaluable asset in guiding and aiding surgeons intra-operatively, allowing for more complex surgical procedures to be performed. The success of cardiac surgery, including valve replacement procedures, depends on such advances and the accuracy of such imaging modalities.

## **Chapter Three: Treatment strategies**

### **3.1 Introduction**

There are a number of therapeutic strategies to treat patients. Only in the worst cases are valve replacements considered. Since no ideal paediatric valve prosthesis exists yet, and due to the continued complications associated with growth in paediatric patients, the option to intervene surgically by means of device implantation is usually deferred until a larger valve can be implanted. Whether valvular disease is acquired or congenital, the inability to treat its underlying cause has led to palliative treatment by means of medical therapy and/or surgical intervention.

When addressing the treatment strategies for valvular disease, the treatment is largely palliative – treating the symptoms by reducing them, rather than addressing disease etiology and prevention. However, in some cases, disease prevention has been successfully addressed, for example, in acquired rheumatic disease, by antibiotic prophylaxis with penicillin, or erythromycin where penicillin allergy is evident.(78) Unfortunately, in developing countries, rheumatic disease is rarely prevented and often leads to valvular disease.(39)

Since the first call in treatment is pharmacological means, this is discussed here first, followed by a discussion of surgical interventions other than prosthetic replacement.

### **3.2 Pharmacological therapy**

The primary therapeutic intervention with any disease is medical therapy. Success may be possible with some acquired valvular diseases, especially if they are caught early, before any significant damage has been done to the heart and its valvular structures. If a condition is addressed in a timely manner, it is possible to limit the damage and provide the necessary time for the body to heal

itself, reversing the damage to some degree. This allows the individual to lead a healthy life with the natively intact valve. However, when rheumatic heart disease has led to valvular disease, medical treatment is of little use in slowing disease progression.(39)

Overall, pharmacological or medical therapy for all forms of valvular disease is generally palliative. It includes the use of endocarditis prophylaxis and the more recent lipid-lowering and statin medication. Endocarditis prophylaxis prevents endocarditis (inflammation of the endocardium), which often occurs secondary to valve disease. However, it has little effect on the valve itself. Hence, today it is no longer recommended in patients with aortic stenosis, unless they have a prosthetic valve.(36) Lipid lowering therapy has yet to show significant benefit in reducing the progression of stenosis, despite its continued use.(84) Similarly, statin therapy is claimed to delay disease progression and decrease the need for aortic valve replacement, but it has yet to show clinical significance.(78)

There is no medical therapy for the treatment of aortic and mitral stenosis and/or regurgitation. Not only is medication ineffective, it can potentially have adverse effects with severe stenosis, by altering the preload and afterload necessary for adequate cardiac output and blood pressure, respectively.(84,89)

Pharmacological therapy for tricuspid stenosis and pulmonary regurgitation is of little use and the condition ultimately requires valve replacement. The degree of pulmonary regurgitation cannot be reduced, nor can the adverse effect it has on the right ventricle be avoided.(57)

By contrast, mild mitral stenosis may be palliatively treated with diuretics, reducing and controlling left atrial pressure, thereby improving symptoms. But, as it is a palliative treatment, it is only a temporary option, and ultimately surgical intervention is required when the symptoms worsen.(38)

Diuretics can also help control aortic regurgitation to some extent. The condition can be reduced with vasodilators such as nifedipine, but just enough

to delay surgery, by three years at most. This treatment is also only possible if the left ventricle functions normally and it has only a slight effect in the case of severe regurgitation.

In the case of cyanotic syndromes such as hypoplastic left heart syndrome, pulmonary or tricuspid atresia, or Ebstein’s anomaly, in which limited to no blood can flow to the lungs, medication may be critical to keep an infant alive. Such drug therapy includes Prostaglandin E, which keeps the ductus arteriosus open until a suitable time for surgical intervention, when the infant is stable enough to undergo surgery.(14) However, such medication cannot be given indefinitely and a time comes when surgery can no longer be postponed.

Recommendations as to the appropriate use of medical therapy are given in Table 3-1.

<b>Recommended medical treatments for valvular heart disease</b>					
	<b>VASODILATORS</b>	<b>BETA-BLOCKERS</b>	<b>DIURETICS</b>	<b>ANTIBIOTIC PROPHYLAXIS OF RHEUMATIC FEVER</b>	<b>ANTIBIOTIC PROPHYLAXIS OF BACTERIAL ENDOCARDITIS</b>
<b>Primary valvular heart disease</b>					
Mitral regurgitation	No	No	No	?*	Yes
Aortic regurgitation	Yes	No	No	?*	Yes
Mitral stenosis	No	Yes	Yes <sup>†</sup>	Yes	Yes
Aortic stenosis	No <sup>‡</sup>	No	No	?*	Yes
<b>Secondary valvular heart disease</b>					
Ischemic mitral regurgitation	Yes	Yes <sup>§</sup>	No	No	Yes
Functional mitral regurgitation	Yes	Yes	Yes	No	No
Functional tricuspid regurgitation	No	No	Yes <sup>  </sup>	No	No
Aortic insufficiency from aortic disease	No	Yes <sup>¶</sup>	No	No	Yes

\*Prophylaxis is indicated if echocardiography shows evidence of a rheumatic etiology of valve disease  
<sup>†</sup>To alleviate pulmonary congestion  
<sup>‡</sup>ACE inhibitors may be considered if surgery is contraindicated  
<sup>§</sup>May be used in the rare situation when mitral regurgitation is worsened by ischemia  
<sup>||</sup>To manage edema and hepatic congestion  
<sup>¶</sup>Should not be used in severe aortic regurgitation

Table 3-1: Medical treatment options for valvular disease (90)

Medical therapy is said to be only of benefit in the early stages of mild and asymptomatic valve dysfunction. Its role in the treatment strategy for valvular disease is minimal, as the condition almost invariably requires surgical intervention.(38)

Palliative medicine can only treat symptoms, while leaving the underlying problem causing the disease untreated.(8) It cannot reverse the effects of disease and may at best delay the need for surgery. However, even this benefit is marginal and it may be debated whether it is actually of any long-term benefit. Delaying surgery is often required, due to a lack in the technology available to treat patients. This lack includes the fact that small valve prostheses are not widely available for neonates and infants.(15,90)

In order to treat valvular disease by pharmacological means, valvular disease and its progression must first be better understood.(4) The lack of effective pharmacological treatment options increases the need for appropriate mechanical cardiac intervention.

### **3.3 Mechanical cardiac intervention**

Surgical management of a young patient with congenital heart disease affecting the valves is a multifaceted problem, which involves weighing up the risk of surgical intervention against the possibility of palliation success. Surgical intervention may or may not require the use of medical devices, of which paediatric-sized prosthetic valves are one option, among a few other emerging technologies. These emerging technologies are briefly touched upon in Chapter 5, as they may be of great value as a novel technology source in valve prosthesis development.

Ideally, the intention of surgery is to correct the patient's functional anatomy to be as close as possible to a normal defect-free heart so that it functions in a physiologically normal manner in terms of haemodynamics and its myocardial function. This is viewed as corrective surgery and is always the first goal in cardiac intervention.

There is much debate on the true "corrective" nature of surgical procedures for heart defects. According to one definition, it is when "life expectancy is normal, and no further medical or surgical treatment is necessary"(91), but in others it



refers to normal functioning.(91) Precisely what constitutes “normal functioning” is not clearly defined either. In treating a young congenital heart disease patient, only partial correction is usually achieved, due to the complex nature of the heart disease. It is thus important to stress that the true nature of surgical treatment for young congenital heart disease patients through partial correction is in fact palliative, rather than corrective. This is particularly true because the child’s continued development inevitably requires surgical re-intervention later on in life. That said, it should be noted that the terms “corrective” and “palliative” are often used interchangeably in discussions on treating congenital disease in paediatric patients. These terms are thus synonymous in this context, with neither referring to a curative treatment.(91)

Having this in mind, various first-call cardiac interventions prior to valve replacement are presented here. These range from surgical valvotomy through balloon dilation to surgical mechanical repair.

### **3.3.1 Valvotomy and Balloon dilation**

A stenotic valve can be opened by means of a surgical incision or with the use of a balloon-tipped catheter. In the first case, the valvular obstruction is relieved by cutting into the valve using a procedure known as a surgical valvotomy. It involves opening the chest to gain access to the heart and then gain access to the valve either by cutting through the cardiac muscle (an open valvotomy), or by entering via the great vessels (a closed valvotomy) (see Figure 3-1). Regardless of the technique used, cardiopulmonary bypass is required.

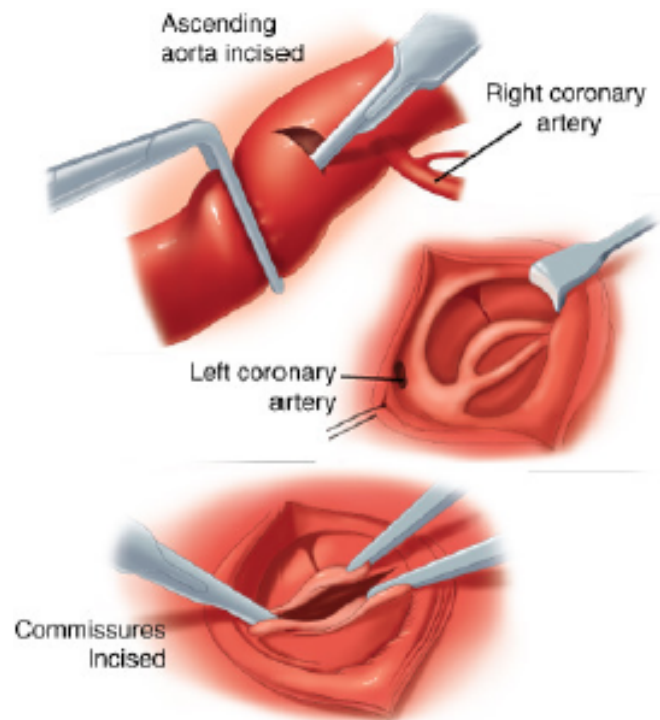


Figure 3-1: Open surgical aortic valvotomy (92)

Another option is a minimally invasive procedure referred to as balloon dilation or balloon valvuloplasty, which does not require cardiopulmonary bypass. Such a procedure involves an inflatable balloon expanded to opening up the stenotic valve. This is done by inserting a balloon-tipped catheter into a main artery or vein and feeding the catheter up to the heart, where access is gained to the diseased valve (see Figure 3-2). Although the procedure does not require cardiopulmonary bypass, it does require some form of anaesthesia.

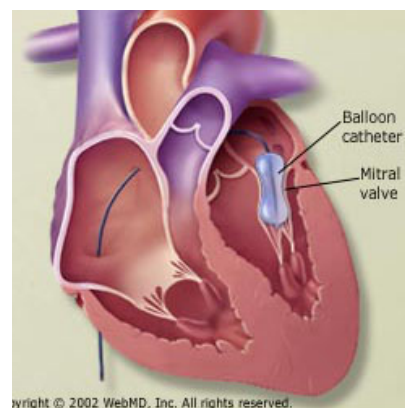


Figure 3-2: Balloon valvuloplasty procedure opening a stenotic mitral valve (93)

Surgical valvotomy has largely been superseded by balloon valvuloplasty, with balloon valvuloplasty as the preferred valvuloplasty technique. It has become the overall treatment of choice for defects such as pulmonary stenosis.(87) Since its inception in the early 1980s it has been performed on thousands of adolescents, children, infants and even newborns in the first week of life worldwide, and the procedure is widely reported in scientific literature. It has now become safe and effective for use in the overall paediatric population. It has even been reported for use in treating severe aortic stenosis in the foetus in an attempt to prevent the development of HLHS.(87,94,95)

Balloon valvuloplasty is a suitable treatment for severe aortic stenosis, congenital pulmonary stenosis or rheumatic mitral stenosis in which the valve anatomy is suitable for such a procedure. Balloon valvuloplasty for mitral valve stenosis is preferred over surgical repair because such invasive procedures are associated with high morbidity and mortality. The better clinical outcome, together with the potential to delay the need for mitral valve replacement has made the less invasive procedure preferable.(87) The use of balloon valvuloplasty as a treatment strategy for various disease and disorders is given in Table 3-2.

<b>Disease or disorder</b>	<b>Balloon valvuloplasty</b>
<b>Pulmonary stenosis</b>	Treatment of choice (balloon valvuloplasty)
<b>Pulmonary atresia</b>	Together with needles, lasers and perforation catheters – atresia PV can be opened
<b>Aortic stenosis</b>	Therapy of first choice
<b>Noonan's syndrome</b>	Lower success rate
<b>Mitral stenosis</b>	Promising reasonable alternative
<b>Tetralogy of Fallot</b>	Balloon valvuloplasty: successfully used for pulmonary valve

Table 3-2: Balloon valvuloplasty as a treatment strategy for various disease or disorders (87)

The success of such a technique depends on the balloon, the guidewire and imaging technology used. Despite the improved risk of procedural mortality, there are some limitations associated with the treatment, including valve restenosis and induced regurgitation. Although there is a low incidence of restenosis upon early outcome, late restenosis has been reported with congenital aortic valve stenosis. Freedom from re-intervention in children and neonates at 1, 5 and 12 years follow-up is 86%, 48% and 46%, respectively.(96)

Procedural induced regurgitation, such as pulmonary regurgitation, is commonly found in 10% to 40% of individuals who have undergone balloon valvuloplasty. Recently, it has come to light that the complication of regurgitation has induced right ventricular dilation and hence dysfunction, requiring pulmonary valve replacement later on in life. Procedural deaths are not unheard of in neonates.(94)

The need for re-intervention after balloon valvuloplasty is common, particularly in patients younger than 3 months. Half of patients younger than 3 months require re-intervention at 1 year follow-up, while re-intervention is required only in 20% of patients older than 3 months at 3 years follow-up.(94) If re-intervention is needed, repeat balloon valvuloplasty (if possible) can be performed. However, often other means of intervention are necessary, which may include surgical valve repair or even valve replacement. This emphasises the palliative nature of balloon valvuloplasty. It is thus clear that balloon valvuloplasty is generally only used as a bridge to further treatment involving other surgical repair procedures.

### **3.3.2 Surgical intervention**

There are numerous surgical repair techniques to correct congenital cardiac defects. If surgery is necessary, repair or reconstruction is the preferred approach to dealing with congenital defects in the young, because they allow for somatic growth by sparing the valve. Despite the growing success of such

techniques, they are not always feasible in paediatric patients, as their success depends on favourable valve anatomy and whether or not favourable results are foreseen.

There are numerous surgical procedures that can be used to treat symptoms. Such procedures and techniques involve complex shunts that essentially redirect blood flow through the heart, which is particularly useful for cyanotic cardiac diseases that require improved pulmonary circulation (see, for example, the Norwood procedure shown in Figure 3-3). The reason for the preference for such techniques in young patients is that they provide growth potential because no artificial materials are used as part of the surgery. In procedures where prosthetic conduits are used, the advantage of growth is eliminated, thus requiring re-intervention at a later point in life when the patient outgrows the conduit.

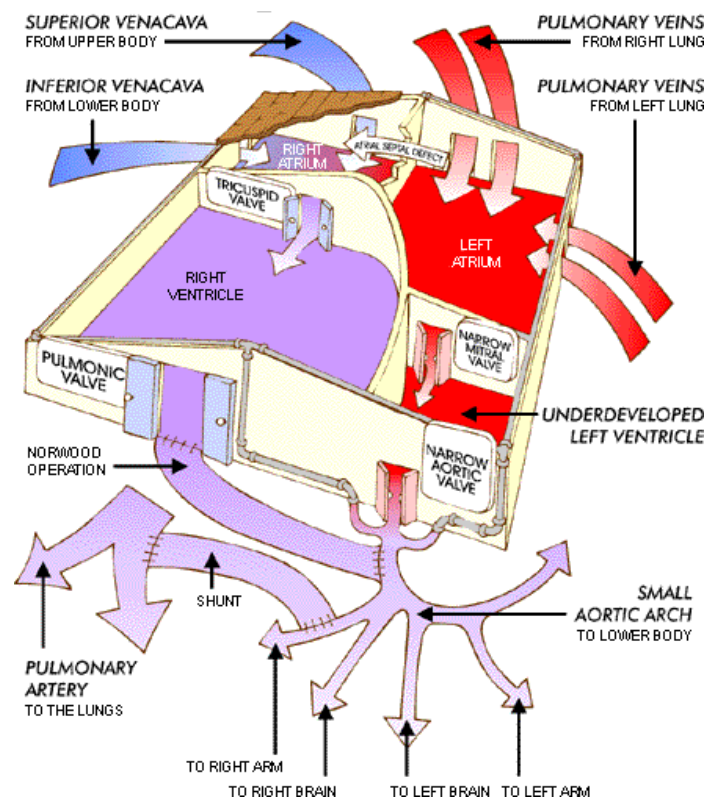


Figure 3-3: Schematic of the Norwood procedure performed as the first stage in shunting for HLHS (97)

There are numerous disadvantages of shunting techniques. Surgical complexity is the main disadvantage, which arises because shunting has to be performed in stages. Often three or more procedures are required to redistribute the great arteries or veins and this may take years. Systemic-pulmonary shunts are used for cyanotic diseases to allow for better pulmonary blood flow and are employed in the treatment of ToF, tricuspid atresia, pulmonary atresia, HLHS and Ebstein’s anomaly. This way, more oxygenated blood is supplied to the body by increasing blood flow to the lungs for re-oxygenation.(71,98)

Repair techniques other than the construction of anastomosis or shunts include valvectomy by cutting out the valve to relieve obstruction, and valvuloplasty by plastically repairing the valve through reconstruction, as well as the already mentioned valvotomy and balloon dilatation, a form of valvuloplasty.(99) See Table 3-3 for a description and the intended aim of various procedures available to the surgeon in treating paediatric valve disease and Figure 3-4 showing a method of valve leaflet repair known as valvuloplasty.

<b>Procedure</b>	<b>Description</b>	<b>Outcome</b>
<b>Anastomosis</b>	Connection of adjacent vessels	Normalize blood flow and relieve obstruction
<b>Shunting</b>	Divert blood from one area to another through the use of biological or synthetic conduits (valved or unvalved); similar to anastomosis but vessels are not necessarily adjacent	Normalize blood flow and relieve obstruction
<b>Banding</b>	Constricting a vessel with the use of a band	Decreasing pulmonary flow
<b>Valvectomy</b>	Excising a heart valve (removing part of or the whole valve)	Relieve obstruction for stenosis
<b>Valvotomy</b>	Making an surgical incision into a heart valve	Relieve obstruction for stenosis

<b>Valvuloplasty</b>	Any form of plastic surgery performed on a heart valve through surgical means with or without the use of implantable devices	Treating and minimizing regurgitation but may also be used to open up stenotic valves
----------------------	--	---

Table 3-3: A list of common palliative procedures performed when treating valvular disease (99)

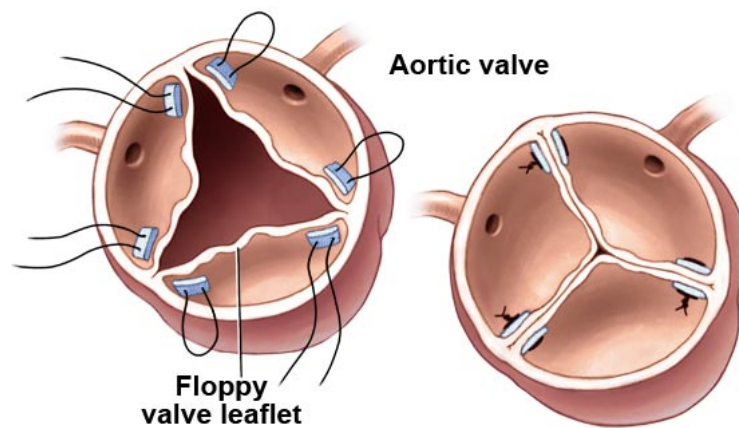


Figure 3-4: Aortic valvuloplasty to repair the regurgitant valve (100)

Although these procedures may temporarily achieve normal cardiac function and are perceived as corrective, they are not a definitive and permanent solution to the problem of valvular disease. They are not a cure, as a cure implies that there are “no adverse sequelae from disease” (91), in other words, there are no foreseeable complications and the disease does not recur.

Other than treating the symptoms, all the current paediatric palliative procedures can ultimately do is prolong the time between interventions. When repair or reconstruction fails in treating symptoms, there is no other choice but to perform a valve replacement, making it the procedure of choice for many congenital valve defects. Hence, valve replacements are discussed in the next chapter.

## **Chapter Four:**

### **Current status of paediatric valve replacement**

#### **4.1 Introduction**

There have been significant advances in valve replacement technology since the first procedure of its kind was done on children in 1964. Much of the technology surrounding paediatric valve replacements have been built on that applicable to adult patients.

Technological improvements include device and procedural advances, as well as a better understanding of valve disease in young patients. These advances, combined with greater surgical experience, with improved haemodynamic valve prostheses, has vastly improved short- and long-term clinical outcomes. Patients can now enjoy a longer life expectancy with lower morbidity than ever before. Individuals are now living well into adulthood and now represent the grown-up congenital heart (GUCH) population.

It is within this context that the historical learning curve and the current status of early life valve replacement prostheses are presented in this chapter.

#### **4.2 Valve types**

Currently there are two categories of replacement valves available for paediatric patients, namely mechanical and bioprosthetic valves. Mechanical valves are manufactured entirely from synthetic materials, usually biocompatible metal, but also other synthetic materials such as polymers. Bioprosthetic valves are biological tissue valves. These two categories are discussed in more detail below.



### 4.2.1 Mechanical heart valves

Mechanical heart valves are purely synthetic or non-biological valves. They are constructed of three main components: an occluder in a housing with a sewing ring around it.(101)

Mechanical heart valves have developed significantly since the first ball-in-cage valve introduced in the 1950s for adult patients. Today, many different configurations are found, but the most commonly used mechanical valve is of the tilting disc or bi-leaflet type, which has largely replaced the traditional ball-in-cage valves.

In mechanical valves, the occluder is a circular or semi-circular disc(s) that is hinged to the housing. Around this housing, there is a synthetic sewing ring allowing for surgical placement into or onto the valve annulus. The disc component can be singular or bi-leaflet, both of which allow for varying degrees of central flow.

A list of biomaterials used for mechanical heart valves is given in Table 4-1.

Component	Biomaterials used
Cage, housing or hinge design	Commercially pure titanium or titanium alloys (Ti6Al4V) Cobalt-based alloys (Stellite-21, Haynes-25) Pyrolytic carbon (LTI carbon)
Occluder, disc, leaflet or ball	Pyrolytic carbon (LTI carbon) Silicone rubber Polyacetals (Delrin) Polyolefins (ultra high molecular weight polyethylene)
Sewing ring	Polypropylene Polytetra fluoroethylene (Teflon) Polyethylene terephthalate – PET (Dacron)

Table 4-1: Materials used in mechanical valve prosthesis (102)

Ball-in-cage valves such as the Starr-Edwards (Edwards Lifesciences Corporation, Irvine, CA, USA) valve (see Figure 4-1a) were implanted in children in the 1970s, but they produced poor results early on by the 1980s. The Bjork-Shiley (Shiley Inc, Irvine, CA, USA) disc valve (see Figure 4-1b) become a

popular choice in the mid-1970s to the early 1980s, and became the valve of choice for children by the early 1980s.



Figure 4-1a): Starr-Edwards ball-in-cage heart valve (103)



Figure 4-1b): Bjork-Shiley valve prosthesis (104)

However, by the mid 1980s catastrophic device failure was associated with the strut, causing the device to be removed from the market by 1986. At that time, all types of mechanical valves were implanted in children, including the Medtronic Hall (Medtronic Inc, Minneapolis, MN, USA) valve (see Figure 4-2ba). However, after the introduction of the St Jude valve (St Jude Medical St Paul, MN, USA) (see Figure 4-2a), all other mechanical valve prostheses were used less, as the St Jude became the most promising alternative. DeWall *et al.* (105) and Van Gott (106) provide a detailed history of the evolution of mechanical heart valves. (105–109)



Figure 4-2a): St Jude Medical Regent valve (100)



Figure 4-2b): Medtronic Hall Easy-fit valve(100)

There is no definitive mechanical valve used in children today, but the St Jude valve seems to be the most widely reported mechanical valve prosthesis in use in children.(110–117) It has even been implanted in children in West Africa.(117) Long-term results with the device are slowly emerging.

Other valves that have been reported for use in children include the Carbomedic (Carbomedics, Austin, TX, USA) mechanical paediatric aortic and mitral heart valves (see Figure 4-3a and Figure 4-3b).(107,111,116–118)



Carbomedics Standard Pediatric  
AORTIC



Carbomedics Standard Pediatric  
MITRAL

Figure 4-3a): Carbomedics paediatric aortic valve (119)

Figure 4-3b): Paediatric mitral valve (119)

A list of other mechanical heart valves used in the paediatric population is given in Table 4-2.

Valve type	Description	Materials	Size range (diameter with sewing ring)	
<b>Bjork-Shiley</b>	Single tilting disc	<ul style="list-style-type: none"> <li>Pyrolitic carbon leaflet</li> <li>Teflon sewing ring</li> </ul>	Sewing ring: 17-33mm Orifice: 12-24mm	
<b>Medtronic Hall Easy-fit</b>	Single tilting disc	<ul style="list-style-type: none"> <li>Pyrolitic carbon leaflet</li> <li>PTFE sewing ring</li> <li>Titanium housing</li> </ul>	20-29mm ID: 20mm, OD:28.5mm Orifice:16-24mm	
<b>St Jude Medical bileaflet valve</b>	Bileaflet tilting disc valve	<ul style="list-style-type: none"> <li>Pyrolitic carbon leaflet and housing</li> <li>PTFE sewing ring</li> </ul>	17-31mm 19mm-29mm Orifice:14.7-26mm EOA: 1.7-3.5cm <sup>2</sup>	
<b>Sorin-Carbomedics heart valve</b>	Bileaflet tilting disc valve	<ul style="list-style-type: none"> <li>Pyrolitic carbon leaflet and housing</li> <li>PTFE sewing ring</li> </ul>	Mitral valve	16mm 18mm 21mm
			Aortic Valve	16mm 18mm
<b>ATS Medical Open Pivot AP valves</b>	Bileaflet tilting disc valve	<ul style="list-style-type: none"> <li>Pyrolitic carbon and housing</li> <li>Polyester ring</li> </ul>	Smallest size 16mm	

Table 4-2: Heart valves available in sizes small enough for the paediatric patient (101,120,121) OD: Outer diameter, ID: Inner diameter

In addition, there are conduit-mounted valves, termed valve-in-conduit, which can be used for the semilunar valves. However, their sizes are slightly larger and, in the case of the Carbomedica Carbo-Seal (Carbomedics, Austin, TX, USA) (see Figure 4-4), the smallest available size is a diameter of 21mm.(119)



Figure 4-4: Carbomedics Carbo-Seal Valve-in-Conduit (119)

The St Jude and non-conduit Carbomedic heart valves seem to be the most popular for use in the paediatric population. This is probably due to surgeons' preferences and vast experience with such valves, as well as the availability of these valves in low profile and small diameters.

Such small sizes are made possible by keeping the effective orifice area (EOA) as large as possible and merely altering the seating design of the sewing ring. This technique has managed to downsize the 19mm valve, creating 16 mm to 18 mm size valves. However, there is no indication that changes were made to the valve leaflet and housing design to cater for paediatric haemodynamics. It is unclear why the housing and occluder were not downsized to create valves even smaller than 16 mm to cater for infants. A possibility is that the mechanical integrity of the valve is compromised if it is any smaller.

When such valve sizes (16 mm to 18 mm) are too large for small patients, surgical techniques are used to enlarge the native annulus, such as aortic root enlargement. This allows a small patient to accommodate an oversized valve prosthesis. Alternatively, if this is not feasible, supra-annular device placement is used where possible. This involves implanting the valve on top of the native annulus, as opposed to inside it. However, in both cases, it involves implanting an oversized valve, which is in itself a questionable procedure, as it leads to

patient-prosthesis mismatch and is accompanied by a range of complications and risks.(14)

Although mechanical valves are renowned for their superior durability, compared to biological valves, because of the use of degradation-resistant material, they have one major disadvantage, namely the need for chronic anticoagulation therapy to stop the blood from clotting unnecessarily when it comes into contact with foreign materials.

The lifetime need for anticoagulation medication, such as warfarin, brings a range of complication risks with it. Anticoagulant-related complications include the risk of haemorrhaging. This may be problematic if a child is extremely active and at risk of injury. In addition, the patient is most likely to require other surgical procedures in his/her lifetime, not necessarily cardiac, and the risk of bleeding may be problematic.

Other complications such as thrombosis (clotting) often occur due to poor tolerance and patient non-compliance with the medication. This makes it difficult for clinicians to control minimising thromboembolic events, which in the worst case puts the patient at risk of sudden death.(122) The need for careful patient compliance may often be very difficult for children to understand and regimens may be difficult for them to adhere to, particularly when they are young.(107) This ultimately requires strict monitoring by parents and family during the early stages of life.

Anticoagulation medication also places limits on the activities of daily life; in other words, it limits patients from participating in very active sports, due to the risk of thromboembolic events and the risk of injury-related bleeding.

An additional complication arises if a patient becomes pregnant, because the use of anticoagulant medication is unsafe to the mother and the foetus. During pregnancy the mother is hypercoagulable and the risk of thrombotic events increases. Overall, the use of such medication is associated with a foetal loss in

12% of cases, and 6.4% of births involve some form of congenital defect. It also places the mother at risk of death, although this risk is lower, at 1.8%.<sup>(123)</sup> Women need to be educated when they are of childbearing age as to the complications associated with anticoagulation therapy and pregnancy. They are usually advised not to become pregnant.

These are some of the reasons that mechanical valves, despite their superior durability, are avoided in some paediatric patients. An alternative, which is growing in popularity in some institutions, is bioprosthetic valves.

#### **4.2.2 Bioprosthetic heart valves**

When considering bioprosthetic valves the options are

- xenografts;
- homografts; or
- autografts.

Xenografts are sourced from animals, porcine or bovine. Bovine pericardial xenografts involve fashioning a valve out of bovine-sourced pericardial tissue. It can then be stented or stentless. If it is stentless, no artificial material is used and the valve is implanted as is (see Figure 4-5).

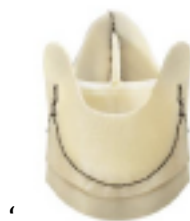

Figure 4-5: A stentless bovine pericardial valve (124)

If the valve is stented, the valve is stitched/anchored onto a frame that contains a sewing cuff (see Figure 4-6a and Figure 4-6b). The frame is manufactured from synthetic materials, such as titanium or polypropylene. This is then covered entirely by the tissue valve, or with Dacron or polyester fabric, so that

the stent is not exposed to blood. This is to eliminate the need for anticoagulation medication as a result of fashioning the frame often out of metallic components.(124,125)

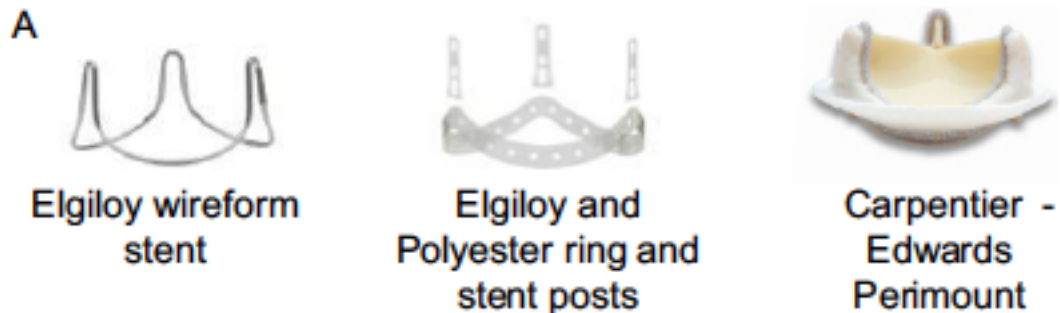


Figure 4-6a): Separate stent components (124)

Figure 4-6b) Final stented bovine pericardial valve with suturing cloth (124)

Alternatively, the valve can be sourced from a bovine jugular vein. In this case, usually a section of the vein is removed with the valve. This valve-in-conduit is then implanted, without the need for stenting. A bovine jugular vein valve available on the market for the paediatric cohort is the Contegra (Medtronic Inc, Minneapolis, MN, USA) bovine right ventricular pulmonary artery (RV-PA) conduit. It was approved by the Food and Drug Administration (FDA) for Humanitarian Device Exemption (HDE) in November 2003 and is available in a size range from 12 mm to 22mm (see Figure 4-7). The device has been reported to be associated with a freedom from re-operation in 94% of cases at 11.4 years follow-up, in spite of the fact that ever-increasing valvular regurgitation and some rare cases of thrombus formation on the valve leaflet has been reported. The advantage with the Contegra is its lower cost compared to that of pulmonary homografts. (122,126)

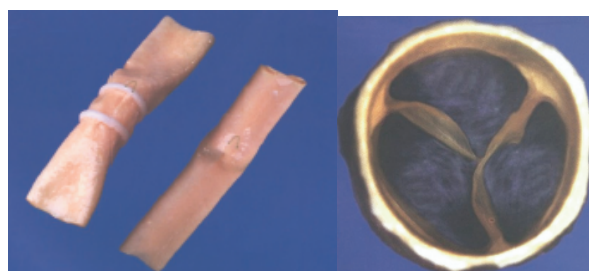


Figure 4-7: Contegra valve-in-conduit sourced from a bovine jugular valve (122)

Porcine valves are sourced as complete valves from pigs, for example, from the porcine aortic root. The valves can also be stented or stentless, in the same manner as bovine pericardial valves (see Figure 4-8).(103)

A recent report indicated that stentless valves have a larger effective orifice area (EOA) than stented bioprostheses. Stentless valves thus have better haemodynamics and coronary flow, and as a result exhibit a lower transvalvular pressure drop.(127)

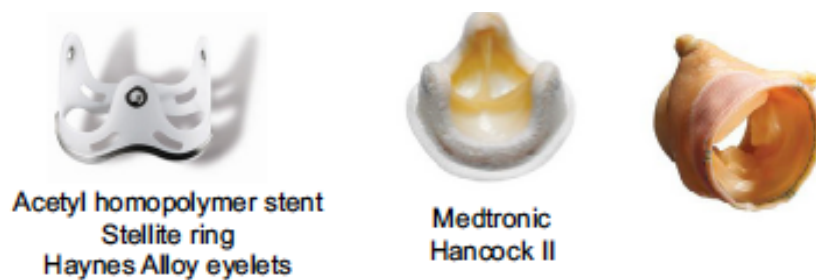


Figure 4-8: Medtronic valves (Medtronic Inc, Minneapolis, MN, USA) Medtronic Hancock porcine stented valve components (left) and assembled valve (middle) and (right) Medtronic Freestyle stentless porcine valve (124)

Autografts are valves taken from the valve recipient. They involve valve translocation from the healthy pulmonary valve to replace another diseased valve usually the aortic valve but also potentially the mitral valve. The pulmonary valve is then replaced with a prosthetic valve. Autografts are superior, not only because they last longer due to their better durability, but also because they also allow for growth potential, since the individual's own valve is used.

Homografts from human cadavers are of the valve-in-conduit type (see Figure 4-9). The advantage of homografts is the size range and their favourable handling characteristics. However, they are costly, have a limited shelf life and cannot readily be found in a small size for neonates. They generally have a freedom from re-operation between 30% and 80% at 10 years, but if the valve is smaller than 19 mm this freedom decreases drastically to less than 50%.(128) Compared to xenografts, they tend to have a shorter lifespan and ultimately need to be replaced within 10 to 20 years.(128)



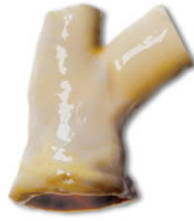

Figure 4-9: CryoValve (CryoLife Inc, Kennesaw, GA USA) pulmonary homograft (129)

Valved-conduits are often used in RVOT replacement, as right ventricle to pulmonary artery conduits (RV-PA). Other than homografts and jugular bovine vein, they can also be porcine valves in a Dacron conduit or pericardial tissue valve in a Gore-Tex conduit. It should be noted that if materials such as Gore-Tex or Dacron are used, the patient does not require anticoagulation medication.(130)

There are numerous bioprosthetic valves available on the market, all of which use advanced tissue treatment and preservation techniques. There are slight variations in their handling techniques during production or preparation, but nowadays such valves are treated with gluteraldehyde fixation, which is an anti-calcification method. Other anti-calcification techniques include amino-oleic acid and polysorbate treatment.(120)

Although the valves vary somewhat from one another, they generally have similar advantages and disadvantages. The greatest advantage with bioprostheses is that they are biocompatible and do not require the chronic use of anticoagulation medication. They also have excellent handling characteristics and are available in small sizes, especially xenografts. (128)

Unfortunately, they are not as durable as mechanical valves, as they tend to calcify and degenerate. Although new preservation and anti-calcification techniques are attempting to improve their durability, it is still significantly lower than that of their mechanical counterparts.

Xenograft valves are known for their late complications involving calcification and structural degeneration. This can be seen in approximately 70% of patients

at an average follow-up of 8 years. Xenografts in the mitral position only last between 3 and 5 years; in the aortic position, the degeneration is accelerated due to high blood flow velocities; better results are obtained in the tricuspid position. However, some disagree with the use of xenografts in the tricuspid position because low blood flow velocities make it prone to calcification. (122,131)

Pulmonary autografts are also prone to calcification and degeneration, but early and late complications within 7 years are fewer than with xenografts (11.9%). (118)

Homografts are somewhat disappointing in comparison, as they are less durable than autografts and xenografts – they tend to degenerate in a shorter time frame of 4 years or less, as reported in a comparative study by Turrentine *et al.* (118) However, they do have favourable histocompatibility and haemodynamics and are thrombotic- and infection-resistant. Studies suggest that homografts are better than xenografts, as xenografts' immunological response in the host is greater and they exhibit signs of obstruction that can have an adverse impact on the haemodynamics. It is in this light that it is suggested that homografts should be the primary bioprosthetic valve choice for non-autograft procedures. Homografts are the gold standard for treating RVOT replacements in children. In addition, the pulmonary homograft is preferred over the aortic homograft, since better clinical results can be obtained with it. (118,122,132)

High blood pressure can dilate a bioprosthetic valve due to its compliant nature. (128) It should be noted that the valve will not function in exactly the same way as it did in the donor. This difference in functioning between the host and donor is a result of handling and preservation procedures, as tissue has a fragile nature. Another limitation to bioprostheses is that they are non-living connective tissue. They can therefore not repair themselves when they are injured, nor can they grow with the recipient.(128,133)

Despite these limitations of such bioprostheses, they are favoured in patients who are deemed non-compliant with anticoagulation medication or who may wish to become pregnant in the future, where such medication would be contraindicated.(123) There is no consensus over which type of bioprosthetic valve is best suited for paediatric patients. Many factors influence a surgeon in selecting such a valve, including patient age and size, as well as valve availability.

It is beyond the scope of the study to provide an exhaustive list of bioprosthetic valves currently available on the market, but some of the major worldwide valve prostheses companies whose bioprosthetic valves have been reported in the scientific literature relevant to children are listed in Table 4-3.(1,107,118,120,124,126–129,134–137)

<b>Valve</b>	<b>Manufacturer</b>	<b>Description</b>	<b>Size range</b>
<b>Hancock valve</b>	Medtronic Inc.	Stented porcine valve	-
<b>Mosaic valve</b>		Semi-flexible stent	21-35 mm
<b>Freestyle</b>		Stentless porcine	19-29 mm
<b>Contegra</b>		Bovine jugular vein (used for neonates)	12-22 mm
<b>Carpentier-Edwards standard valve</b>	Edwards Lifesciences, Inc.	Stented porcine valve	19-29 mm
<b>Carpentier-Edwards PERIMOUNT valve</b>		Valve fashioned from bovine pericardium and housed in a stent	19-29 mm
<b>Edwards Prima Plus</b>		Stentless porcine	19-29 mm
<b>Toronto SPV</b>	St. Jude Medical Inc.	Stentless porcine	19-29 mm
<b>Quattro</b>		Stentless quadrileaflet pericardial	-
<b>Shellhigh</b>	Shellhigh Inc.	Porcine valved conduit	10-24 mm (useful for neonates)
<b>CryoValve</b>	CryoLife	Pulmonary homograft	Varies

Table 4-3: List of popular bioprosthetic valves used in children (120,128,129)

The four main stented and stentless valves from two of the major companies, Edwards Lifesciences Inc. and Medtronic Inc., are shown in Figure 4-10 and Figure 4-11, respectively.

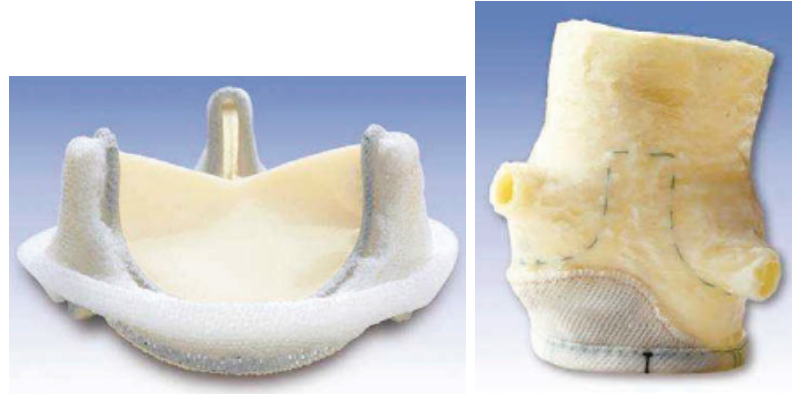

Figure 4-10: Carpentier-Edwards Perimount stented bovine pericardium (left) and the Edwards Prima Plus stentless porcine bioprosthesis (right) (Edwards Lifesciences, Irvine, CA, USA) (138)

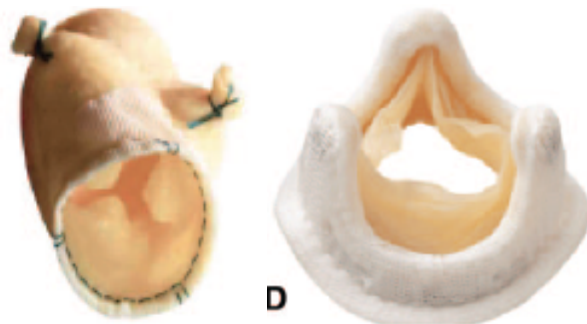


Figure 4-11: Medtronic Freestyle stentless porcine (left) and Medtronic Mosaic stented porcine (right) (Medtronic Inc, Minneapolis, MN, USA)(103)

### 4.3 The debate: mechanical versus bioprosthetic valves

There has been much debate as to the use of and need for mechanical valves versus their bioprosthetic counterparts. In considering the advantages and disadvantages of both types, clinicians are still divided over which type of valve is best suited for paediatric patients. It is clear is that the choice is individualized to the patient, with each type's advantages and disadvantages weighed against one another, providing a guide to valve selection.

It is not in the interest here to explore this debate in depth. Instead, some of the advantages and disadvantages with some reported clinical comparisons of both types of valve prostheses are summarised in Table 4-4.

	<b>Mechanical</b>	<b>Bioprosthetic</b>
<b>Durability</b>	Excellent	Poor
<b>Device life expectancy</b>	>15 years	10-15 years
<b>Haemodynamics</b>	Problematic – potential for thromboembolism	Excellent
<b>Reported time to redo</b>	7.6 years	3 years (homograft)
<b>Size</b>	≥16 mm (fixed diameter)	≥12 mm
<b>Medication required</b>	Anticoagulation	No medication
<b>Complications</b>	No growth potential Not as biocompatible Haemolysis Thromboembolism Infection Stroke Haemorrhage	Only growth potential for autografts Biodegradation
<b>Re-operation rate</b>	15.2%	Xenografts: 70% Pulmonary autograft: 11.9% Aortic homograft: 50%
<b>Survival rate</b>	87.8% at 10 years	Xenografts: 100% (at 10 years) Pulmonary autograft: 95.2% Aortic homograft: 6.6% (at 7 years)

Table 4-4: Comparison of mechanical and bioprosthetic valve types (118,139)

In general, bioprosthetic valves, despite their lower durability due to biodegradation, are advantageous because they do not require anticoagulation therapy and provide better haemodynamic flow and haemocompatibility than mechanical valves. This is shown in Figure 4-12, which demonstrates that the bioprosthetic valve has a more centralized flow, with a single orifice, while the mechanical valves have a double orifice with struts exposed to blood flow. Another advantage of bioprostheses is their greater availability in many size variations, particularly when using homografts or autografts.

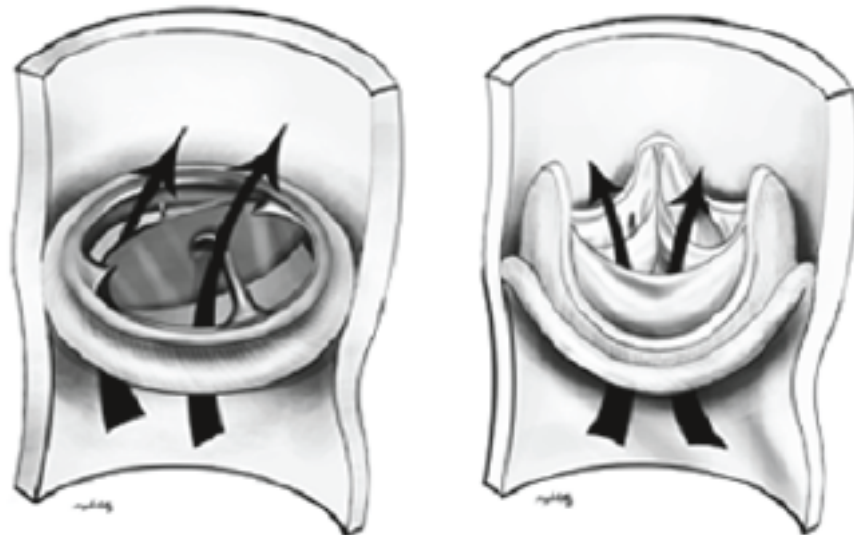


Figure 4-12: Blood flow through a mechanical valve (left) and a bioprosthetic valve (right) (120)

Autografts are the only growth potential valve available. However, they require the valve, in the donor valve position, to be replaced with a prosthetic valve that does not have growth potential. This causes a potential double valve disease problem, with two valves at risk of failure instead of the originally disease valve. Valve failure with autografts is reported to be as high as 45% within 10 years.(49)

Mechanical valves require anticoagulation, but have better durability and hence a longer device life expectancy. Complications with anticoagulation therapy include thrombotic risk during pregnancy as a result of the increased ability of the blood to clot during pregnancy. In addition, the use of warfarin, a type of anticoagulation medication, during pregnancy is associated with an increased risk of foetal defects. Other complications include the risk of anticoagulation-related haemorrhage, which can be problematic in highly active individuals. Despite these disadvantages, mechanical valves are associated with a lower risk of mortality than bioprostheses.(49,123)

Overall, there is no difference in the short-term quality of life of patients with mechanical or bioprosthetic valves, but the long-term outcomes regarding quality of life are less certain.(140)

With no superiority with either type of valve prosthesis, it remains the clinician's choice that determines the selection of the appropriate valve for a patient. The valve position under consideration for valve prosthesis implantation also plays a large role in this selection.

#### **4.4 Surgical valve replacement: options and outcomes**

The best choice of valve prosthesis for a patient depends strongly on the individual. What is suitable for an adolescent is not necessarily applicable to a child or an infant, not only because of prosthesis size and difference in life expectancy but also because of the metabolic and haemodynamic differences with increasing age.

There are potential complications and limitations in any surgery, but this is especially true for valve replacements in the paediatric population. Although there are common complications relating to the type of valve prosthesis, as discussed previously, there are also complications that are specific to valve location.(120) The clinical outcomes and complications are vast, so an outline of some of the most important complications is given in Section 4.6. It should be noted that operative mortality with valve replacements in children is high, 10% to 36%, which is much higher than that reported with adults.(107,141)

Long-term results in the grown-up child are now being reported, and some additional complications and limitations are now becoming increasingly apparent. These need to be addressed pre-emptively at the time of the initial valve replacement during early life, where possible. (71)

Since no ideal valve prosthesis exists for any of the four valves, and since a tissue-engineered valve is far from being clinically available on the market, the debate on the prosthetic valve of choice in the paediatric population is still on-

going. Many suggestions have been made, but no fixed rules apply. Instead, some guidelines are given, but even with such guidelines, valve choice remains based on an individual choice for an individual patient, particularly with paediatric patients, and rightfully so, since the variations in the anatomical and structural abnormalities seen in congenital disorders are vast. Extrapolating that which is applicable from one patient to another would be unwise, as the degree of cardiac structure development differs considerably from one patient to another.

Valve prosthesis selection depends on many factors, including patient age, co-morbidities, patient prognosis, valve position, patient compliance, expected complications and the potential effect on the patient's quality of life in relation to lifestyle.(120)

A suggested guideline reported in the literature is given in Table 4-5. Some of the reasoning justifying such choices and their clinical outcome are summarised in the following section for each valve position.

<b>Valve position</b>	<b>Valve replacement likelihood and reason for replacement</b>	<b>Prosthesis choice</b>
<b>Aortic</b>	Bicuspid valve – second-most common valve replacement in the paediatric valve population	Pulmonary autograft (Ross procedure) – young children Limited use of bioprostheses in older children OR Mechanical valves – often used for connective tissue disorders or when pulmonary valves are unsuitable for the Ross procedure
<b>Mitral</b>	Uncommon due to modern repair techniques Common in small children with small mitral annulus Replaced most often as a result of rheumatic disease	Pulmonary autograft (Ross II) Bi-leaflet mechanical valves in younger children Bioprostheses in older children  Problem valve: Highest associated



Valve position	Valve replacement likelihood and reason for replacement	Prosthesis choice
	<i>Rheumatic disease, Shone's complex – mitral stenosis and endocarditis</i>	mortality
<b>Pulmonary</b>	Most commonly replaced in the congenital population as a result of congenital defects (also because of its use as an autograft for aortic valve replacement) <i>ToF, pulmonary atresia, pulmonary stenosis, used for Ross procedure to replace aortic valve</i>	Homograft (mid1980s -2000) Valved conduits: xenograft or synthetic xenograft valves Mechanical valve in special cases in older children, especially if patient has had multiple prior surgery and if patient has other mechanical valves (Mechanical valves are controversial)
<b>Tricuspid</b>	<2% of valve replacement population <i>Failure of Ebstein's tricuspid repair</i>	Bioprosthetic valve Avoid mechanical valves due to lower blood flow velocities

Table 4-5: Indication of valve prosthesis selection for all heart valve positions (120,122,142)

#### 4.4.1 Aortic Valves

The aortic valve is the most commonly replaced valve in adults but the second most commonly replaced valve in children. Due to its position in the systemic circulation in the LVOT, it experiences high blood flow velocities. Thus a high durability prosthetic valve is required.

In response to this problem, the Ross procedure was developed. Today, it is a popular choice for very young patients, but less so for older children, where other alternatives can be sought.(142)

This technically demanding surgery involves a two-valve operation. It uses the healthy pulmonary valve as an autograft for the diseased aortic valve. This means that since the pulmonary valve is removed in order to replace the aortic valve, the pulmonary valve must be replaced with a prosthetic valve.(122)

There are a number of benefits to using a pulmonary autograft in the aortic position. These advantages include superior haemodynamics, greater freedom from re-operation, the fact that the patient does not need anticoagulation therapy, lower associated operative mortality compared to the use of other prosthetic valves, and its resistance to post-operative complications such as endocarditis. In addition, the autograft valve shows growth potential, because it is cellularized with the host's own cells: that is the donor and the host are the same person.

However, despite these advantages, the procedure creates a double-valve disease, risking pulmonary autograft failure in what was once a healthy valve. This makes the procedure somewhat controversial in the surgical community.(122) In addition to this controversy, there is the recently reported need for numerous re-operations after a Ross procedure. Such re-operations are often complex, not only because of autograft failure and aortic dilation, but the procedures risk involving other cardiac structures, including the mitral and tricuspid valves for regurgitation. Because of the high complexity, such re-operative procedures are associated with high morbidity and mortality. This has resulted in the technique being less favoured for use in older children who may benefit from alternative valve prostheses available in appropriate valve sizes.(131,143)

The various clinical results presented with the Ross procedure include a variety of documented rates of freedom from re-operating on the pulmonary autograft. Alsofi *et al.* (144) reported a freedom at 15 years follow-up of 82%. Ruzmetov *et al.*(131) reported the need for re-operation to only be 9%, but did not indicate the follow-up time for the group for which they report this low need for re-operation. Khwaja *et al.* (122) reported a similar low need for re-operation of only 2% at 69 months follow-up. Finally, Elkins *et al.* (145) reported this freedom at 16 years to be 83%  $\pm$ 6% with a survival rate of 84%  $\pm$ 8%.(145) The freedom from re-operating on the pulmonary autograft seems unclear, varying significantly from one centre to the next.

However, the need to re-operate on the pulmonary prosthetic valve must also be considered, even though it has been claimed to be less of a concern, because it is more manageable in relation to the aortic valve, since it is situated in the RVOT and is subjected to lower haemodynamic loads and velocities than the aortic valve.(122)

The reported rates for re-operating on the pulmonary prosthetic valve, with the use of a homograft, vary in the scientific literature. Khwaja *et al.* (146) reported this to be 6% to 20% at 10 years. Alsofi *et al.* (147) reported that at 15 years re-operative freedom was 74%, with a freedom from both homograft and pulmonary autograft replacement at 61%, while for other cardiac procedures it was 85%. Homograft failure in the pulmonary position is associated with risk factors such as smaller homograft size, younger patient age and truncus arteriosus.(147)

It is apparent from these statistics that approximately 20% of Ross patients will require re-operation on the pulmonary autograft within 15 years. The need for re-operating on the pulmonary valve when homograft prosthesis is used is also approximately 20%, with a further 15% needing re-operation for treating other cardiac structures. Finally, Alsofi *et al.* (142) indicate that the highest mortality rate, 15% to 20%, occurs in infants less than 1 year old. This is a significantly higher mortality risk rate than that reported in older children younger than 5 years, namely 4%.

These statistics are acceptable for young children, but problematic for use in infants. The emerging need for re-operating on Ross patients and the associated poor morbidity and mortality outcome lead some surgeons to prefer to seek alternative options for aortic valve replacements in the young.

Such alternative options include bioprosthetic and mechanical valves. Unfortunately, neither type of prosthesis has growth potential. The use of bioprosthetic valves, including homografts, in the aortic position is not

favoured, because bioprosthetic valves are prone to accelerated calcification and degeneration due to high blood flow velocities and high calcium metabolism in young children. In addition, they are associated with a higher need for re-operation, and in the case of homografts, regurgitation and obstruction. If valve failure results, it often requires replacement within 5 to 7 years. However, in older children with poor anticoagulation compliance, females of child-bearing age and in young children in whom the pulmonary valve is unsuitable for use in the Ross procedure, bioprostheses may be considered over the mechanical alternative.(120,122,129,134)

There is some division on the use of mechanical valves in the aortic position. Some say it is inferior, because it gradually weakens the individual and is associated with numerous complications and early mortality, claiming that mortality can be as high as 50% in children younger than 5 years.(142) Others argue that mechanical valves are a good prosthesis alternative to both the Ross procedure and bioprostheses, with a low associated operative mortality, reported to be 5.3% in a study involving 56 patients.(114)

It is generally agreed that mortality is in the range of 6% to 13% with the use of mechanical aortic valve replacement.(120) Good survival and freedom from re-operation results have been reported. Alexiou *et al.* (114) report survival to be 91% and 84.9% at 10 and 20 years respectively, but it can be as low as 64.3% in patients with complex congenital lesions. Other studies report survival between 70% (125) and 91% (114) at 10 years and 84.9% (114) at 20 years. The re-operation rate for mechanical aortic valves has been reported to be 15.2% (118) and 16% (2) at an average time interval of 7.2 and 7.6 years respectively.

The re-operation rate reported for mechanical aortic valve replacement is lower than that reported for xenografts (60% at only 5 years follow-up), but it is slightly higher than that for aortic homografts (14% at a mean follow-up of 5.8 years) in a comparative study involving 147 children (2). In another study with 99 children, the survival rate for mechanical aortic valve replacement was 87.8% at 10 years, compared to 100% in the xenograft group at 10 years, 95.2%

in the pulmonary autograft group and a poor 6.6% in the aortic homograft group, all at 7 years follow-up.(118)

Given that anticoagulant complications based on a 3-year experience with 147 children have been reported to be very low with the use of a mechanical valve in the aortic position, its acceptable risk of mortality and low need for re-operation has made it a safe option for aortic valve replacement in the young population. (2) This has caused some surgeons to adopt mechanical aortic valve replacement with a bileaflet valve as their first valve choice in young patients. Other surgeons who prefer the Ross procedure select mechanical prostheses for aortic valve replacement as their second choice when the pulmonary autograft is unsuitable for use in the Ross procedure. (118)

The best aortic valve prostheses for paediatric patients remains a hotly debated topic, although surgical valve replacement remains the gold standard and definitive treatment for aortic stenosis.(96) Given that 34% of patients have to undergo a second valve replacement within 10 years and 19% of patients die, while a mere 47% survive without any need for further aortic valve replacement (134), it is clear that clinical outcomes with AV replacements are not as good as they could be. Often a younger age, lower weight and smaller valve and annulus size are factors that can lead to an increased risk of a poor outcome. (122)

#### **4.4.2 Pulmonary valves**

Strategies for replacing the valve in the RVOT have changed over the years. It remains the most commonly replaced valve due to congenital defects in the paediatric population. RVOT replacement with porcine and homograft valves have been reported with acceptable outcomes. Freedom from valve re-do was found to be 100% and 70% at 8 years for porcine and homograft valves, respectively. Children younger than 3 years had a higher risk for re-operation; reported as 76% and 39% at 1 and 8 years respectively. When the risk for re-

operation due to younger age was taken into consideration, it was found that both valve types performed similarly, although the porcine xenograft valve seems to suggest longer freedom from re-operation compared to the homograft in the pulmonary position.(148)

Bioprosthetic valves in the pulmonary position risk valvular regurgitation, although this is found more frequently in homografts than in xenografts.(148) Because of regurgitation, the valve will require early re-intervention to avoid the long-term adverse affect regurgitation has on ventricular function: causing it to dilate.

Homografts or valved conduits remain a popular choice for valve replacement in the pulmonary position. This is particularly true for neonates in whom homografts or bovine jugular vein valves are a possible choice, as they are more durable in the pulmonary position than in the aortic position. For children and adolescents, the use of homografts, stented prosthetic valves and synthetic valved conduits are suitable.(128)

Valved conduits reported in the paediatric population include valve-in-Dacron conduit, xenograft and homograft conduits. Poor outcomes due to calcification was found in all of these options, although the homografts fared better, albeit with disappointing results overall. Freedom from re-operation ranges drastically, between 50% and 90% at 5 years.(130) Homografts have become the valve of choice and are the most commonly used valved conduit for the RVOT. Unfortunately the overall availability of homografts is problematic as well as the lack of availability in various sizes: due to lack in donors. An alternative was sought and included using pericardial valves mounted in a Gore-Tex conduit. In some studies (130) they have allowed for freedom from re-operation ranging from 4.3 years to up to 7 years. By the turn of the century, stentless bioprostheses had not even been implanted in the paediatric population.

Other studies report the use of not only bioprosthesis (including homografts) but also mechanical valves (148,149). However, this option is used significantly less because of thrombus formation and hence not widely reported. One of the biggest questions with pulmonary valve replacement in a paediatric patient is not what type of valve to select but rather the timing of intervention. Timing is critical, particularly in patients with prior ToF repair, in whom there is right ventricular failure and dilation as a result of iatrogenic pulmonary regurgitation.(149)

In the literature, the use of bioprosthesis as a valve choice for pulmonary valve replacement is discussed.(132,135) In addition, it is suggested that homografts be used where possible and that surgeons should only resort to xenografts when homografts are unavailable.(132)

#### **4.4.3 Mitral valves**

Where possible mitral valve repair is preferred because of the poor prognosis associated with mitral valve replacement, because mitral replacement has the greatest mortality in the young patient cohort (67% by 20 years follow-up(142)) compared with valves implanted in any other position.(122) Because of advanced technology in mitral repair strategies it is now possible to repair more mitral valves rather than replace them. Despite the trend towards repair there are still a few patients who require and may benefit from mitral valve replacement. Hence mitral valve replacement is the second least common valve replacement in the paediatric population.(55)

Few mitral valve replacement procedures are performed annually, with some institutions reporting fewer than seven mitral valve replacements, of which only two were performed in infants and neonates below the age of two, where the risk of mortality was the highest, namely 52%.(141) It is indicated that the smaller the prosthesis implanted and the younger the patient, the greater the risk of mortality. (141)

Mechanical valves with a low profile bileaflet configuration manufactured from pyrolytic carbon are a popular valve prosthesis choice for mitral valve replacement, because they are associated with minimal complications with anticoagulation therapy.(150) However, despite the minimal anticoagulant-related complications reported, the relative freedom from re-replacement and other major complications reported in the literature are somewhat disappointing, at only 45% at 5 years (120) and 17% (120) to 50% (122) at 10 years.

Bioprosthetic valves, excluding autografts, are not preferred in the mitral position due to the exposure of mitral valves to high pressure and high flow velocities combined with high calcium metabolism, which make bioprosthetic valves prone to degeneration. Bioprosthetic valves are therefore rarely used and where reported in the literature early re-operation was often required.(141,143,150,151) The limited number of sizes available is another limitation for their use in small children.(151) With older children, bioprosthetic valves may be particularly useful when calcium metabolism is lower and there is the potential for female patients to reach childbearing age. Autografts such as the PA-MVR show low degeneration, but this has rarely been reported as an option for mitral valve replacement.(151)

The Ross procedure has also been expanded to mitral valve replacement and is known as the Ross II procedure, a pulmonary autograft mitral valve replacement (PA-MVR). The advantage of using an autograft for the mitral position is the “preservation of mitral valve-left ventricular continuity” (122). This has been demonstrated in older children and young adults with pulmonary valves at least 20 mm in diameter. (122)

Annulus enlargement is often performed in very young patients to permit prosthesis placement. However, this has recently been shown to increase the risk of mortality and does not necessarily reduce the need for re-intervention, which was hoped for by allowing the surgeon to place an oversized valve to



compensate for the ensuing somatic growth. Instead this option is now shown to increase the risk for need of re-operation. Because of such disappointing outcomes and the surgical complexity of mitral valve replacement, it is avoided at almost all costs and is only performed in the most extreme cases.(142)

#### **4.4.4 Tricuspid valves**

Tricuspid valve replacement is rare compared to replacement in the other positions and hence they are replaced the least.(122) Few studies could be found documenting the use of prosthesis in this position. In the studies found the main cause for valve replacement were Ebstein's anomaly, pulmonary atresia and ToF. The use of mechanical and bioprosthesis was more or less equally divided in the smaller studies,(131,143) while a much larger study reported by Bartlett *et al.* (144) mainly used mechanical prostheses for infants less than 1 year old, while infants older than 1 year tended to receive bioprosthetic valves. Usually tricuspid valve replacement is performed in addition to other procedures to treat other co-existing defects. The risk of mortality remains high, at 9% to 36%. Valves reported for use in the tricuspid position include the St Jude (St Jude Medical, St Paul, MN, USA) and Carbomedics mechanical valves (Carbomedics, Austin, TX, USA), and the Carpentier-Edwards (Edwards Lifesciences, Irvine, CA, USA) and Hancock (Medtronic Inc, Minneapolis, MN, USA) bioprosthetic valves.

The relationship between valve size and age used in Bartlett *et al.*'s (144) study indicated a valve size range of 17 mm to 21 mm for infants younger than 1 year, while those older than 1 year had a valve size ranging from 22 mm to 28 mm. The outcome of the study indicated the importance of valve sizing in the tricuspid position. In addition, the numerous complications experienced specific to valve replacement in this position lead to the recommendation that heart transplantation in the very young patient be considered as an alternative and, where that option is not suitable, the use of a bioprosthetic valve might lower the rate of thrombosis complication.(144)

The patient outcome and suitability of bioprosthetic valve implantation depends on valve position. It has been shown that the best outcomes in the tricuspid position have been achieved with bioprosthetic valves because they have a lower propensity for calcification and structural alterations in the tricuspid position compared to those in any other position. However, having said that others view the use of homografts in the tricuspid position problematic due to their proneness to calcification as a result of low blood flow velocities.(131)

Freedom from re-operation is less with bioprosthesis valves than with mechanical valves and it differs in the tricuspid position compared to the other positions. If bioprosthetic valves are used porcine valves are recommended.(122)

#### **4.5 Grown Up Congenital Heart (GUCH) problems**

With survival to adulthood at more than a 90% survival rate now reaching well into the fourth decade of life, or more, there is a need to provide continued follow-up for such individuals.(71) It is said that this adult congenital population will “grow linearly” (152). It is expected that more than 50% will have serious CHD, and just under 30% will have complex CHD.

It is suggested that the GUCH population older than the age of 16 is growing by more than 1 600 patients annually, having reached approximately 165 000 in the UK alone by 2010.(152) This suggests the success rate of early intervention, but poses a new problem in the continued need of re-intervention in the later years in adult life. The distribution of the type of lesions involved in grown-up individuals with congenital heart disease, in the order from the greatest to least contributors, include ToF, aortic stenosis, BAV, Marfan’s syndrome, pulmonary atresia and Ebstein’s anomaly.(71)

ToF patients have a 90% chance of survival to the age of 40 years. Because children with heart defects now live longer, new long-term complications emerge later in their adult lives, presenting as adult complications. Such complications experienced with ToF patients who have undergone corrective surgery include pulmonary valve regurgitation, atrial and ventricular arrhythmias and the risk of sudden cardiac death. Arrhythmias are found in 35% of ToF patients, and sudden cardiac death in 6% at 30 years follow-up. Often regurgitation becomes progressively worse, eventually leading to right heart failure as a result of volume overload, leading to ventricular enlargement and dysfunction. It is important to note that heart failure is a common complication in the GUCH population and is not only seen in grown-up ToF patients.(71)

#### **4.6 Technological limitations**

Limitations of valve replacement technology are related to the prosthesis itself and/or the surgical aspects. Those that are prosthesis-related are generally associated with the device's long-term outcomes and the implantation approach and technique, both of which should have minimal adverse consequences or complications.

Other limitations associated with surgery involve operative equipment, including the surgical instruments and cardiac imaging equipment at hand, and even the skill of the surgical staff. The cardiac surgeon's experience plays a pivotal role in device implantation success.

As with any new medical device, there is a significant learning curve associated with device implantation. Not only should appropriate patients be identified to undergo novel procedures, but surgical training is very important in successfully developing and bringing a product to the market.

#### 4.6.1 Limitations with prostheses

There are three central themes around limitations with current valve prostheses. These are

- the available prosthesis size;
- prostheses durability; and
- the lack of growth potential.

In addition to the limited number of valve sizes available, device limitations are focused around the longevity of the prostheses. A device's life expectancy depends on its durability, which in turn is influenced by its predisposition to degenerate, as well as the patient's somatic growth. The degree of influence of both factors also depends on the individual's age. Younger children have growth spurts and grow significantly faster than older children. This growth involves high calcium metabolism. Thus somatic growth has a two-fold effect: it results in a patient-prosthesis mismatch and it leads to early device failure due to calcification.(120)

Patient-prosthesis mismatch, due to somatic growth, results when a patient outgrows his/her valve prosthesis, both anatomically and physiologically. It is evident in both mechanical and bioprostheses, with the exception of autografts that show growth potential.(122)

Anatomically, the heart can place strain on the prosthesis as the annulus enlarges, while the prosthesis remains fixed.(141) This anatomical mismatch causes physiological changes in the heart. The haemodynamics are affected, leading to functional stenosis and/or regurgitation. The patient will present with symptoms that may lead to heart failure. It is important to note that the adverse affect of poor haemodynamics differs for each valve position. It might take time for symptoms to present themselves, for example, with the tricuspid valve, whereas with the aortic valve symptoms may be more apparent sooner due to the high blood flow velocities involved in the systemic circulation.(120)

When symptoms of functional stenosis and/or regurgitation are found, they bring about the need for re-operation and upsizing the prosthesis.(120,143,153) Unfortunately, there is a limit to the degree of upsizing possible at each re-operation – no more than a 2 mm to 3 mm diameter increase in annulus size can be achieved.(122) This limitation is imposed by the need to avoid severe cardiac shock, which accompanies a change in valve prosthesis with its associated change in haemodynamics. The heart must slowly become accustomed to the change in haemodynamics presented by the larger valve, otherwise severe shock may lead to sudden death. This limitation in the degree of upsizing that can be done at each procedure affects the number of procedures a patient will have to undergo over his/her lifespan. It is estimated that over a child's lifespan the individual will need between two and four valve replacements to accommodate somatic growth.(154)

Few mechanical valve designs are produced in small enough sizes for infants and young children and although bioprostheses can be found in small sizes, in the case of homografts they are often expensive and hard to come by. The lack of available small valve prostheses results in surgeons' often using larger valves, which contributes to other complications associated with a patient-device mismatch. It also places unnecessary strain on the cardiac structures, and has been shown to produce worse clinical outcomes than patient-device matched smaller prostheses.(142)

The type of valve selected for the paediatric patient has limitations, other than growth and size availability, namely the limitation of lifelong durability. Although mechanical valves are very durable, and in theory can last the patient's entire lifespan, they require the lifelong use of anticoagulation therapy to limit thrombotic events and the risk of thromboembolism. Anticoagulants have a number of drawbacks (also see Section 4.2.1), which involve their metabolism in the liver and the risk of bleeding that comes with taking this kind of medication. In addition, the use of such medication in the paediatric population carries a higher risk of mortality than its use in adults.(118)

These complications risks, albeit small, are serious and generally limit the use of mechanical valves for patients who are already on anticoagulant therapy or who have other mechanical valves. In addition, these complications limit the use of such valves in active children who may injure themselves, and in women who wish to get pregnant in the future.

Bioprostheses do not require anticoagulation, but are not as durable as mechanical prostheses, because of the predisposition of bioprostheses to calcify and degenerate. This limits their use in children, because the prostheses will ultimately have to be replaced, usually within 10 years. Replacing valves more often than is strictly necessary is not desirable, because of the risk of surgical complications and the poor clinical outcome experienced with each re-operation.(133)

The poor durability of bioprosthesis is also as a result of their fragile nature. This places limitations on the degree to which they can be handled, both during tissue preservation treatment procedures and inter-operatively. Surgeons must take great care when implanting such valves. The need for minimal handling requires great skill by the surgical team.(155)

#### **4.6.2 Limitations with surgery**

There are numerous complications and risks inherent in any surgery, and open-heart valve surgery is no exception (see Table 4-6 Such complications include the need for cardiopulmonary bypass and the invasiveness of surgery causing significant trauma to the patient, which then necessitates lengthy hospital stays and long periods of recovery.

<b>Complications or limitations)</b>	<b>Description</b>
<b>Oversizing prosthesis</b>	May lead to subaortic obstruction and prosthetic leaflet entrapment
<b>Heart block</b>	Perioperative risk

<b>Endocarditis</b>	Perioperative risk
<b>Thrombosis</b>	Perioperative and device-related risk
<b>Thromboembolism</b>	Low $\pm$ 1% incidence per year 20 times more likely in the tricuspid position 2-3 times more likely in MV (compared to AV) Reported to be lower in children than in adults
<b>Stroke</b>	Perioperative risk
<b>Bleeding</b>	Operative risk Mechanical heart valve: Anticoagulation-related haemorrhage, although low risk
<b>Mechanical failure</b>	Bioprosthetic degeneration Rarely mechanical valve failure

Table 4-6: Common complications and limitations experienced with surgery (120,151)

The use of cardiopulmonary bypass or heart-lung machine has associated complications. They include, but are not limited to, stroke, myocardial infarction, inflammatory response, acute kidney injury and acute lung injury, aortic manipulation and hypothermic cardiac arrest. These complications are considered to be due not only to the use of cardiopulmonary bypass itself, but to the techniques used to place the patient on bypass.(156) The risk of any of these complications increases with the length of time the patient is on cardiopulmonary bypass. This limits the operative time available to the surgeon to implant a valve. A valve that is difficult to implant requires more time. That means longer times on cardiopulmonary bypass, more risk of perioperative complications and longer recovery times.

As already mentioned above, currently valves in children must be replaced a number of times in their lifetime, between 2 and 4 times. With each re-operation, the operative complications increase and the risk of mortality goes up, because of the invasiveness of surgery causing tissue trauma, combined with complications as a result of the need for cardiopulmonary bypass. Re-interventions require cutting into previously scarred and thus already traumatised tissue. This cumulative trauma puts the patient at risk of sudden death. This limits the number of procedures a surgeon can safely perform to replace a heart valve. Surgical limitations may also be placed on extremely high-

risk patients who have undergone numerous repair procedures prior to valve implantation.

Cardiac surgery and particularly re-operation procedures require surgical skill, even more so for paediatric patients whose congenital defects tend to be complex, often requiring concomitant procedures during valve replacement. Each time a new repair technique is presented or valve prosthesis becomes available, it takes time for surgeons to learn and become competent in the procedure. In complex procedures, this learning curve is often steep and operations require highly skilled and experienced surgeons to perform them. Valve replacements are no different, but a procedure of particular concern is the Ross procedure, which is particularly complex and technically demanding.(114) Likewise, less invasive procedures are also technically demanding, requiring great skill, partly because minimally invasive procedures do not necessarily provide an adequate view of the implantation field. Both the Ross and minimally invasive procedures are particularly associated with a steep learning curve for surgeons.

Since the best clinical outcomes, with any valve replacement, depend on how skilled and proficient the surgeon is in implanting the valve, it is the surgeon's competence with a device that may pose a limitation as to what can be achieved inter-operatively.(157) Poor competence leads to unfavourable clinical results. This may be a deterrent for surgeons to openly accept complex procedures.

Other deterrents to surgical intervention include not only procedural complexity and associated high risks, but also the child's psychosocial quality of life. This may be adversely affected due to scarring as a consequence of open-heart surgery.(158) Such aspects of the patient's quality of life are often less focused upon, even though surgeon's face huge challenges, due to technological limitations, in addressing the problem of scarring (see Figure 4-13).

Psychological factors include depression, which is common among GUCH individuals. Patients may even resist undergoing repeat cardiac surgeries – they



might not report symptoms that may be critical to appropriately medically manage the patient, for fear of undergoing surgery.(71) This places the surgeon in a dilemma, as it may prevent surgery from being performed early enough to limit the progress of symptoms due to disease.

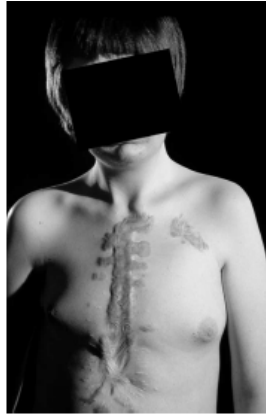

Figure 4-13: Scarring after open-heart surgery (158)

As technologies and surgical procedures in the treatment of congenital heart disease continuously improve, it is not surprising that children born with defects, such as ToF, have a longer life expectancy today. This better long-term clinical outcome, resulting in longer survival rates, comes at a cost in the form of the complications the grown-up child experiences in his/her adult life. As time goes by, patients often neglect to visit their cardiologist until it is too late to reverse such complications. It has even been documented that at the onset of symptoms in their adult life, patients may not have gone for follow-ups for up to 10 years prior to their adult symptoms.(49)

As the GUCH population is on the rise, with more GUCH women at childbearing age, prosthetic valves implanted at an early age may become a problem if the individual wishes to become pregnant. With CHD contributing up to 25% of maternal deaths, it is important to bear the risks associated with prosthetic valve choice in mind, even if such risks are relevant only later in an individual's life. Much has been documented on pregnant women who have undergone prosthetic valve replacement, but little has been said of GUCH women who have potentially already had several surgical procedures, including, but not limited to, prosthesis re-implantation. Such women are said to be at moderate risk of morbidity, with a mortality risk between 1% and 5%.(71)

## Chapter Five: Future perspectives

### 5.1 Introduction

There has been much recent discussion on the possible directions in which valve replacement technologies will go. Kidane *et al.* (159) give an excellent and concise description of emerging valve technologies. In their paper they discuss three fields. These are

- tissue engineered valves;
- polymeric heart valves; and
- percutaneous valve implantation.

Several other authors have gone into great depth arguing the superiority of some of these technology fields over others. Narayan *et al.* (160) and Lutter *et al.* (161) look into the future of percutaneous technologies, while Ghanbari *et al.* (162) and Grikscheit *et al.* (163) discuss polymeric heart valves and tissue engineering, respectively.

Of all of these technologies, percutaneous heart valves have tended to dominate the cardiac field. Since the first such implantation in 2000, a wealth of scientific literature has emerged on this topic. Some discuss complex valve prosthesis designs allowing exchangeable leaflets (164) and repositionable percutaneous valves (165), while others discuss repeat percutaneous valve-in-valve implantation (166) or valve-in-valve implantation for failed bioprosthesis (167). However, only a fraction of the literature found reports on the use of such valves in children. It is thus important to note that percutaneous valves are used in children, but it should also be noted that they are not used in children to the same extent as in adults.

In this literature review, the direction in which emerging valve and some other cardiac technologies are moving in terms of polymeric, tissue engineered and percutaneous heart valves, as well as other novel percutaneous mitral repair

devices are briefly discussed. Ultimately such technologies can provide insight into developing a paediatric specific heart valve, thus further expanding the cardiac surgeon's armamentarium.

## **5.2 Emerging technologies**

There are numerous emerging technologies to deal with valvular disease in paediatric patients. Not all of these emerging technologies have shown clinically promising results. Institutions around the world have developed programmes focusing on how to treat a congenital valve defect child where valve replacements were lacking.

The Children's Hospital Boston has developed such a programme, the "Cardiovascular Program" as part of their Congenital Heart Valve Centre (CHVC) to address the need for dealing with children and adults with congenital valvular defects. They use novel treatments to try to overcome the problem of somatic growth and valve degeneration. Their focus is on tissue engineered valves, better valve reconstruction using micro-electro mechanical systems (MEMS) devices, minimally invasive procedures by using better imaging modalities and steerable catheters, and modelling patient-specific valve function for preoperative planning. In addition, they are assessing the suitability of stent-mounted percutaneous valves and absorbable polymer devices. The hospital arguably has some of the most experienced surgeons in the world, and the team has performed numerous procedures in children and adults alike. They have considerable experience in dealing with stenosis in the HLHS foetus and trans-catheter valves and aim to reduce the number of procedures a child will need to undergo in his/her lifetime.(168)

The distribution of valve surgeries performed at this state-of-the-art institution is given in Figure 5-1.

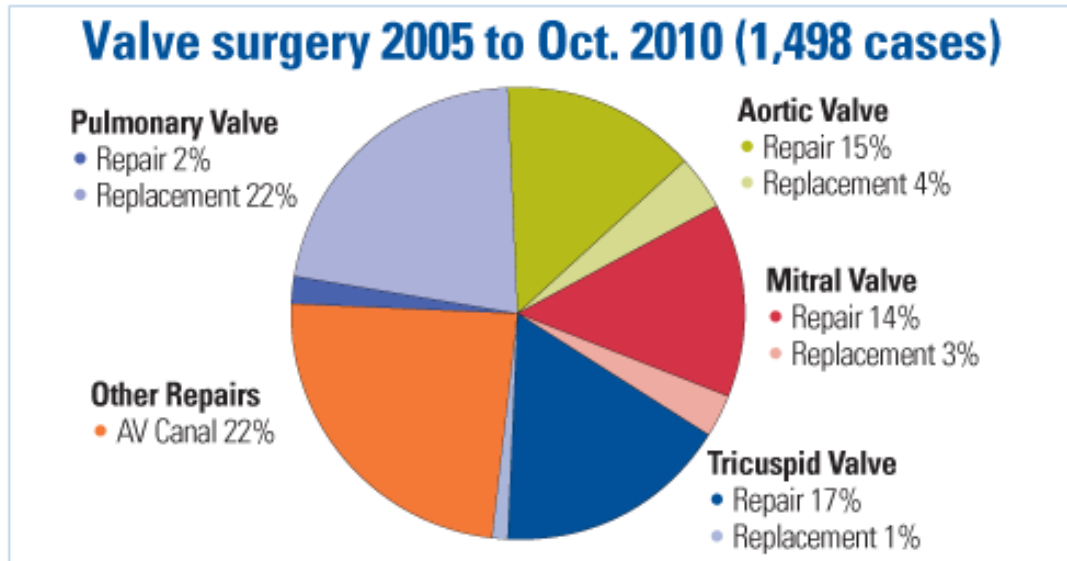


Figure 5-1: Valve surgeries performed at the Boston Children's Hospital (168)

Other research institutions such as the UCLA Henry Samueli School of Engineering and Applied Science are developing a percutaneous heart valve specifically for children. This stented heart valve uses a unique new superelastic shape memory alloy, a form of nitinol, but in a thinner configuration, which is called thin film nitinol or e-Nitinol and is used as the material for the valve leaflets. The valve has a low profile and can be collapsed to be smaller than any other percutaneous heart valve available or currently in design.(169)

Of all these novel techniques, only a handful truly focuses on valve prostheses. Insight is given here on some of these novel approaches, such as tissue engineered heart valves, novel materials, and percutaneous heart valves, as well as a few promising valve repair devices.

### 5.2.1 Tissue engineered heart valves

Some suggest that tissue engineered valves provide the solution to valve replacement options for all positions in the paediatric cohort.(61,163,170) However, it is acknowledged that such technologically advanced valve options will not be a reality in the near future, due the numerous technical and non-technical challenges that must first be faced before these valves can be clinically

implemented. Thus alternative approaches still need to be sought until such valves become a feasible reality for implantation.(122,171)

Several attempts have been made to find a growth potential tissue engineered heart valve. Numerous research groups are involved in this field to try to answer the problems of valve replacement specific to children.

Once such research group is Xeltis, a spin-off company from the University of Zurich and the Eindhoven University of Technology, which works with numerous partners throughout Europe in the search of 'living heart valve' replacements. Their autologous tissue engineered heart valve using foetal stem cells is intended for percutaneous implantation (see Figure 5-2). They claim that their developed technology is at a stage where they plan to implant such autologous tissue engineered valves in patients by 2014. However, thus far, only *in vitro* studies have been performed, and *in vivo* animal trials are still on-going. The results of these studies are therefore unclear. (172)

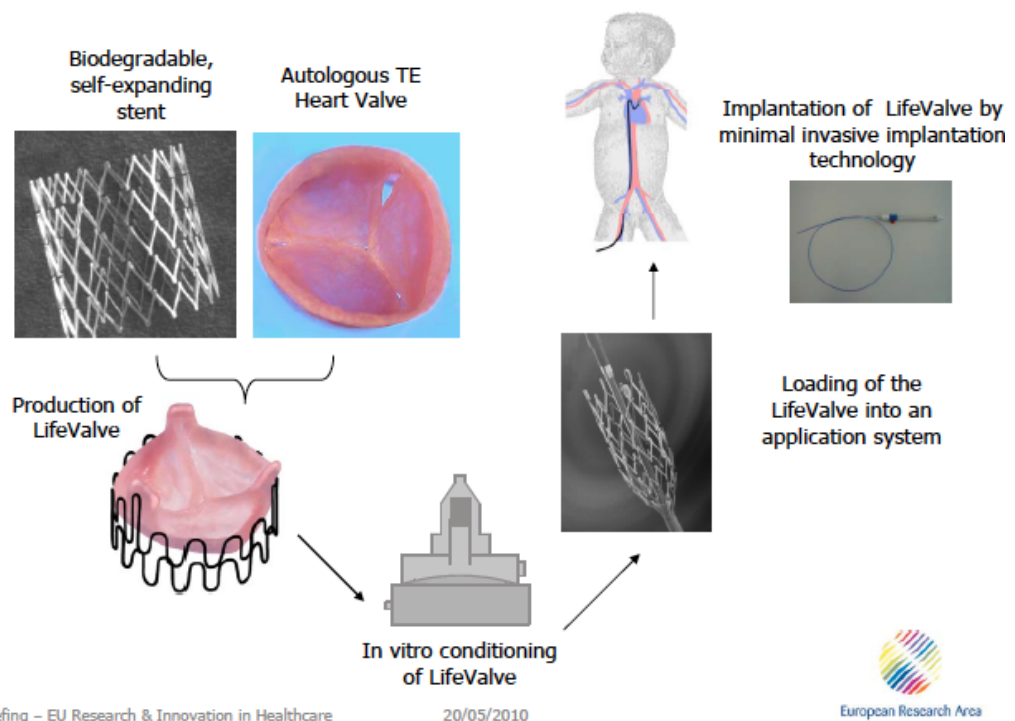


Figure 5-2: Tissue engineered heart valve concept using foetal stem cells to engineer a percutaneous heart valve mounted on a stent intended for paediatric use (172)

Other worldwide research groups are numerous, but none have fared any better or got any further than animal trials. (170)

The most recent tissue engineering technology that has been tried in humans is the CryoValve SynerGraft from CryoLife Inc. The valve technology involves decellularised porcine heart valves, known as acellular matrix valves. The technology addresses the limitations with currently cryopreserved xenografts and aims to increase durability with a tissue valve by decellularising it in the hope that the host's cells will seed the valve *in situ*. Seeding the valve *in vitro* with autologous tissue has been hinted at, but has yet to be done.(170) The Synergraft valves were briefly implanted in a number of children with such disappointing results that caution was urged with the use of the device. The poor results included problems with inflammatory reactions and structural failure possibly due to a lack of complete decellularization. This has caused the heart valve community to cease implantation of this allograft device with the device removed from market in 2004.(173)

The poor results with the world's first tissue engineered decellularized porcine heart valve does not suggest particular promise in the near future for companies such as Xeltis which claim that they have found the answer for paediatric growth potential valves.

### **5.2.2 Repair techniques: annuloplasty devices and leaflet clips**

With advances in surgical techniques, valve repair has become an increasingly popular alternative to valve replacement. In some cases, as with mitral regurgitation, it has even become the therapy of choice and standard of care, particularly so in the older child and adolescent. It has become so popular, in fact, that it accounted for nearly half of all mitral procedures performed in the USA by 2005. This has led to a reduction in mitral valve replacements of nearly 20% over the same period (1998 to 2005).(55) This increase in mitral repair

procedures is attributed not only to the increased survival due to surgical technique advances, but also the greater use of perioperative TEE.

Perhaps one of the greatest advances is that made with mitral valve surgery, which holds an increased risk of mortality due to the complex nature of invasive surgery. In the case of mitral valve replacement, this risk has been reported to be as high as 30%. Hence, avoiding invasive surgery in this situation has been of particular interest within the surgical community.(122)

Hence, minimally invasive mitral valve surgery (MI MVS) was born. This has led to the introduction of transcatheter valve repair using various devices. Often the aim of such devices is to “correct prolapse” (55) by achieving better leaflet coaptation and to “restore annular geometry” (55) by preventing annular dilation. This is achieved by repairing any or all of the valvular complex components: the leaflets, tendinae chordae and/or annulus.

Catheter-based devices provide significant advantages in that they allow the patient to return to activities of daily living more quickly and are associated with lower operative morbidity.(55) Such devices include mitral valve clips and coronary sinus devices for annuloplasty procedures. Both are currently being investigated in human trials, and have thus far been shown to be a safe and viable treatment option. One can go as far as to say that their use may even prevent or at least delay the need for valve replacement. Despite their promising use in adults, their effectiveness in the paediatric cardiac population must still be ascertained.

Two such minimally invasive repair devices, the coronary annuloplasty devices and mitral valve clip are discussed below.

### 5.2.2.1 Coronary sinus annuloplasty devices

Annuloplasty is the reconstruction of a regurgitant valve through plastic repair. Devices used for annuloplasty procedures are often rigid prosthetic annular supporting rings (see Figure 5-3). With the introduction of trans-catheter technology, such devices can now be implanted percutaneously. Such devices are the MONARC system and Carillon XE devices. Both are coronary sinus annuloplasty devices, in other words, they are both percutaneously implanted through the jugular vein and into the coronary sinus .

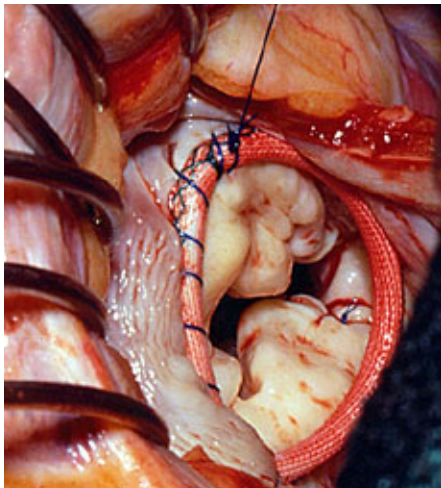


Figure 5-3a): Annuloplasty ring implanted in mitral valve position (100)

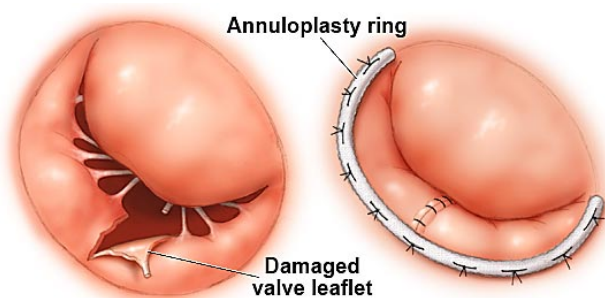


Figure 5-3b): Representation of an annuloplasty ring used to fix a damaged mitral valve (100)

The MONARC (Edwards Life Sciences, Irving, California) coronary sinus annuloplasty (see Figure 5-4 left) is a 120 mm to 159 mm long coiled device with two stents, on either end. The larger and smaller stents can be found in 10 mm to 18mm, and 6 mm to 8 mm sizes, respectively. Bridging the two stents is a biodegradable-coated spring. The coating degrades over weeks, up to 2 months, over which time the distance between the two stents is decreased. This narrows and supports the valve annulus, preventing dilation. Thus far the device has been implanted as part of trials in humans with promising short-term results, despite the complication of coronary artery compression in a number of patients.(174–177)



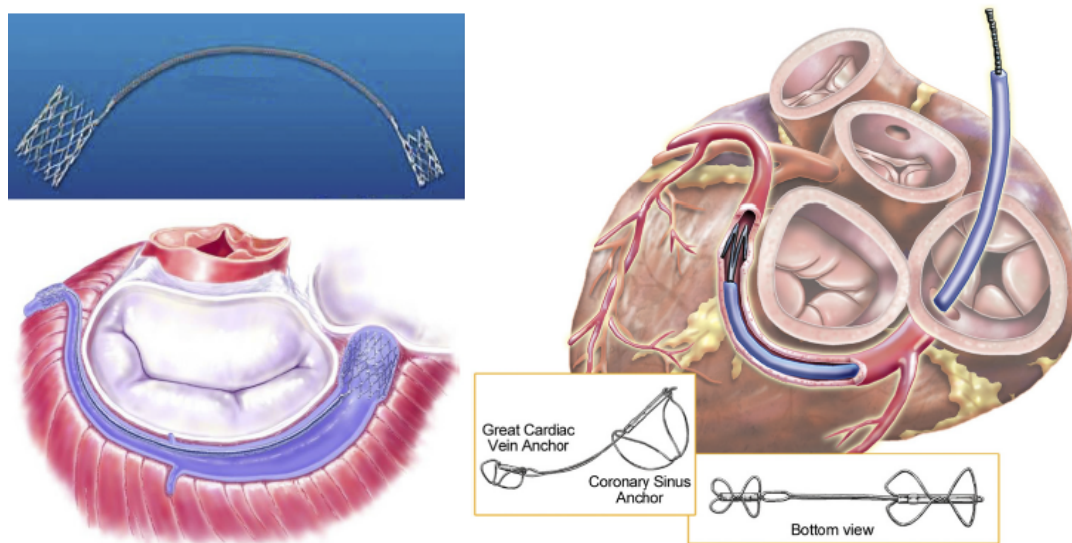


Figure 5-4: Coronary sinus annuloplasty devices: MONARC (Edwards Life Sciences, Irving, California) (177) (left) and CARILLON XE device (Cardiac Dimension, In., Kirkland, Washington) (right)(175)

The CARILLON XE device (Cardiac Dimension, Inc., Kirkland, Washington) (see Figure 5-4 right) is constructed of nitinol wire and contains two self-expanding helical anchors bridged by a single curved nitinol wire. The device is implanted by means of a 9F (3mm) sheath catheter and the distal anchor is deployed first. Tension is then applied to the device, shortening its overall length, before the proximal anchor is deployed.(174,177)

The device applies restraint and support of the annulus, restricting its dilation, thus reducing regurgitation. Despite a successful reduction in regurgitation ranging from 22% to 32% (55), the device has only been successfully implanted in 60% of patients. Of the remainder, 30% had to have the device removed due to complications associated with device fracture, inadequate reduction in regurgitation and coronary sinus trauma.(178)

Despite the fact that the device only provides adequate reduction in regurgitation in a number of patients, the advantage with the CARILLON device is that regurgitation can be assessed inter-operatively. That means that if the

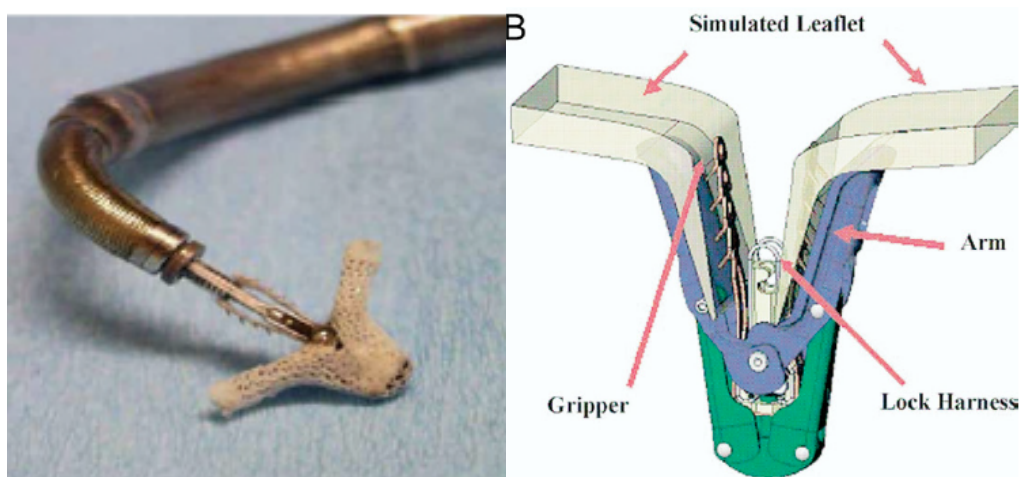
device does not produce adequate results, it may be removed without the need for re-operation.(175)

### 5.2.2.2 MitraClip

A device that can be used for mitral regurgitation is the MitraClip (Abbott Vascular Inc., Menlo Park, CA). It is the only minimally invasive repair device of its kind currently available to surgeons. It is a two-prong clip mechanism, manufactured from cobalt-chromium, which catches on the flail valve leaflets, clamping them together. This reduces the effective orifice area by producing two orifices, thus creating a double mitral orifice valve (see Figure 5-5).

During ventricular systole, when blood is pumped out of the ventricles, mitral regurgitation is limited by preventing the leaflets from prolapsing into the left atrium. The device can be percutaneously implanted, making it a minimally invasive procedure, called an edge-to-edge repair.

The device is currently undergoing FDA trials, but has been approved for clinical use in Europe since 2008. To date, it has shown promising results and is a safe technique in comparison to surgery. Unfortunately, it does not produce as excellent an outcome as surgery does, but it still provides an effective means of treating regurgitation in high-risk patients.



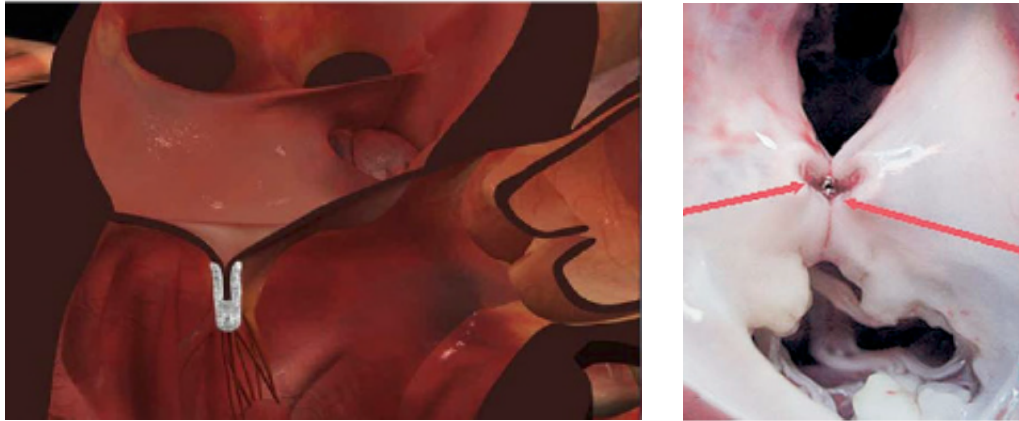


Figure 5-5: MitraClip device with catheter (top left)(177), the device mechanism (top right)(174), a schematic of the implanted MitraClip clamping the bileaflet mitral valve (bottom left) (177) and the double orifice created reducing effective orifice area (bottom right)(174)

The downside of the device is that it is rather large, requiring a 22-24Fr (7.3 mm to 8 mm) catheter sheath, even though the width of the device is only 4 mm. This makes the device ineligible for use in young children whose anatomical size is too small to permit its use.(174,175,177,179)

As with the MitraClip, CARILLON XE and MONARC devices, other minimally invasive catheter-based procedures have shown promise because their use avoids the complications associated with invasive surgery. Technology based around percutaneous procedures has also expanded to include valve replacements.

### 5.2.3 Percutaneous valve implantation

Since the first percutaneous valve was implanted in the pulmonary position using a bovine jugular vein in 2000, implantations in the aortic (2002) and even the tricuspid position have been performed (2011). With 2012 marking a decade in transcatheter aortic valve implantation (TAVI), many improvements have been made in the technology and it is evidently becoming a very promising alternative to open-heart surgical valve implantation.(180,181)

Percutaneous or transcatheter implantation involves implanting a valve by inserting it through a catheter-based procedure via a major artery or vein and deploying the valve in the desired valve position. This approach is similar to that described in cardiac catheterization and balloon valvuloplasty. It can be performed in antegrade, retrograde and transapical approaches. In the antegrade approach (see Figure 5-6a) it involves inserting the valve in the direction in which blood is flowing. In the case of the aortic valve, this is done via the femoral vein and accessing the left side of the heart by creating a hole in the inter-atrial septum and gaining access to the valve by passing through the mitral valve.

In the retrograde approach (see Figure 5-6b), direct access is gained to the semilunar valves and access opposes the direction of blood flow. In the case of aortic valve, implantation, access is obtained via the femoral artery. The retrograde approach is much preferred for both aortic and pulmonary valve implantation due to its lower complexity, because it avoids passing through the mitral and tricuspid valves. (180,182)

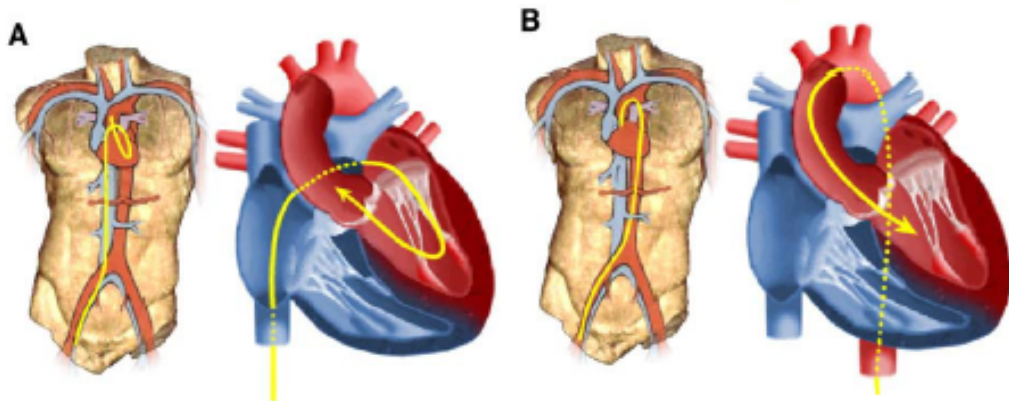


Figure 5-6a): Antegrade approach (182)

Figure 5-6b) Retrograde approach (182)

Alternatively, if need be, a transapical approach can be used. It is more invasive than the antegrade or retrograde approaches, but still less invasive than open-heart surgery. This gains access to the pulmonary or aortic valve through the apex of the heart and does not involve using a vessel (see Figure 5-7).

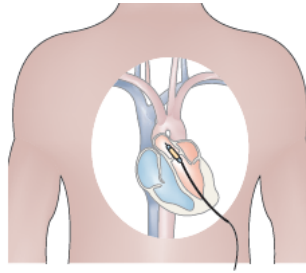


Figure 5-7: Transapical approach to aortic valve implantation (180)

Currently there are two percutaneous valves that are FDA approved, namely the Medtronic Melody (Medtronic Inc., Minneapolis, MN, USA) valve (see Figure 5-8) and Edwards SAPIEN XE (Edwards Life Sciences Corporation, Irvine, CA, USA) valve (see Figure 5-9a-b). The Medtronic Melody pulmonary valve was the first percutaneous valve to become CE marked in October 2006 and to gain FDA approval in June 2010 under HDE. HDE approval included its use in the paediatric population with RVOTs larger than 16 mm.(183)

The Edwards SAPIEN XT valve gained FDA approval in November 2011 for use as a pulmonary and aortic valve implantation. The company may distribute its 23 mm and 26 mm valve for use in high-risk patients commercially, although it is unclear whether the paediatric population is included. Since approval in 2011, the FDA is considering expanding approval to include lower-risk patients. The SAPIEN heart valve received CE approval in September 2007.

The Medtronic Melody (valve consists of an 18 mm bovine jugular vein valve inside a collapsible, 6 mm, platinum-iridium stent. The device is implanted in a 22Fr catheter sheath (see Figure 5-8).(184)

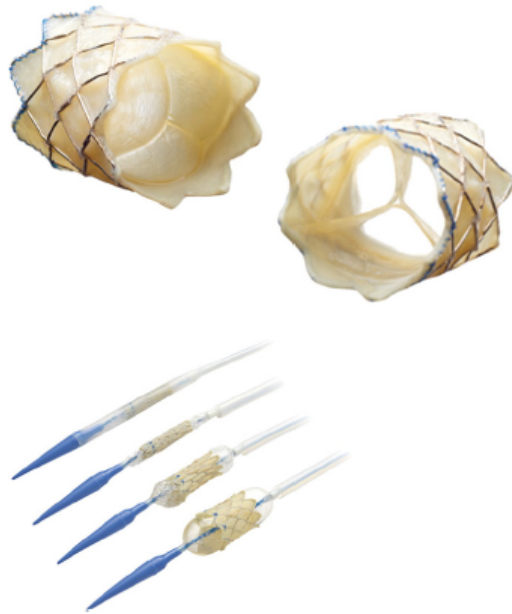

Figure 5-8: Medtronic Melody percutaneous pulmonary valve (Medtronic Inc., Minneapolis, MN, USA) (184)

Shortly after Medtronic introduced the Melody pulmonary valve, the company also introduced the CoreValve (Medtronic, CV Luxembourg), a TAVI. This was CE approved in 2007 and enrolled in an FDA IDE (Investigational Device Exemption) in October 2010. Medtronic have since then closed enrolment in January 2012. The CoreValve has yet to receive FDA approval, but was the first percutaneous aortic valve to receive European approval (CE mark).

The CoreValve is currently in its third generation and consists of a self-expandable nitinol stent with a porcine pericardial valve. The valve size is 26 mm and is placed in an 18Fr (6 mm) catheter (see Figure 5-9c and figure 5-9d)(180)



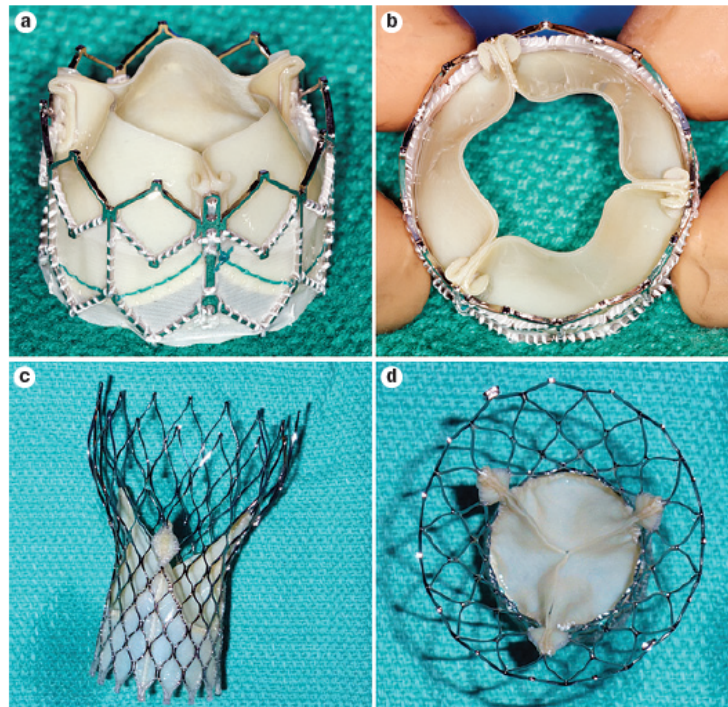


Figure 5-9: Transcutaneous aortic valves – Edwards SAPIEN XT (Edwards Life Sciences Corporation, Irvine, CA, USA)(a and b, top left and top right) and the CoreValve (Medtronic CV Luxembourg)(c and d, bottom left and bottom right).(180)

The Edwards SAPIEN XT can be implanted into the pulmonary or aortic position. The current third generation valve is a balloon-expandable trileaflet pericardial bovine valve mounted in a cobalt chromium stent. The smaller size valves include a 20 mm and 23 mm valve mounted in 16-18Fr (5.3-6 mm) sheathed catheters (see Figure 5-9a and Figure 5-9b, above).(180)

Since then many other valves have been introduced, some have been implanted and are undergoing preclinical trials, others are only in the early design stage. For a detailed list comparing available designs, materials and sizes, see Chiam and Ruitz (185), Narayan and Sharma (160), and Veseley (164).

Overall, there are approximately 14 aortic valves of which the main valves are the SAPIEN and CoreValve, both which have been implanted in more than 1 000 patients each as of 2009.(185)

One valve of particular interest is the Paniagua (Endoluminal Technology Research, Miami, Fl, USA), first implanted in 2005, which can be collapsed to

2 mm (see Figure 5-10a). The 20 mm valve can be implanted using an 11Fr (3.7 mm), 12Fr (4 mm) or 16Fr (5.3 mm) sized catheter. Similarly, the HeartLeaflet valve (Heart Leaflet Technologies, Maple Grove, MN, USA) (see Figure 5-10b) can be collapsed and used with a 16Fr catheter.(160,185)

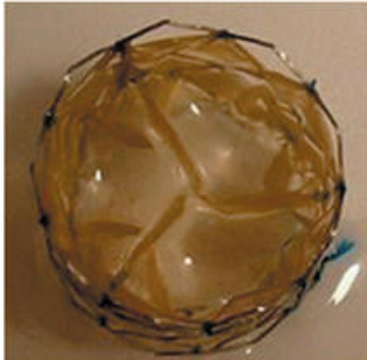

Figure 5-10a): Paniagua (Endoluminal Technology Research, Miami, FL, USA) (186)

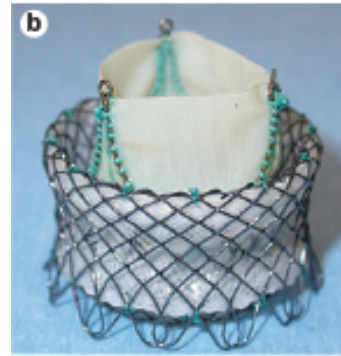


Figure 5-10b): Heart leaflet (Heart Leaflet Technologies, Maple Grove, MN, USA) (180)

Although the Sadra LotusValve (Boston Scientific SciMed Inc, Maple Grove, MN, USA) (see Figure 5-11 right) and Direct Flow (Direct Flow Medical, Santa Rosa, CA, USA) (see Figure 5-11 left) valves are not small (23 mm in a 21Fr (6.93 mm) sheath), they have the helpful feature of being repositionable during implantation. The other valve that differs significantly from all other percutaneous designs is the ABS PercValve (Advanced Bioprosthetic Surfaces, San Antonio Tx) (see Figure 5-12a-c). It is an all-mechanical percutaneous valve manufactured from nanosynthesised nitinol. It has been implanted in animals and has been shown to be biocompatible, with the added benefit of quickly endothelialising. Since it is manufactured from synthetic material, a very small valve can be obtained, with a 10Fr catheter sheath. Unfortunately, it is not repositionable.(160,185)





Figure 5-11: Direct flow (Direct Flow Medical, Santa Rosa, CA, USA) (left) (180) and Sadra Lotus percutaneous heart valve (Boston Scientific SciMed Inc, Maple Grove, MN, USA) (right)(185)




Figure 5-12: ABPS PercValve (Advanced Bioprosthesis, San Antonio Tx) a) Closed valve b) Top view and c) partially collapsed (187)

Except for the PercValve, all other percutaneous valves use stainless steel, nitinol, cobalt chromium or cheathum platinum for the stent material. In general, the nitinol stents are self-expandable, while the other stent material tends to be deployed by balloon expansion. For the valve, they all use bioprosthetic valves from bovine, porcine or even equine sources.(160,185)

There is one other percutaneous valve that has been very innovative in its design. That is the ValveXchange valve (ValveXchange Inc., Aurora, CO, USA). It is currently in its design phase, and the valve size is not indicated. It has yet to be implanted in animals. It is novel because it has the unique feature of exchangeable leaflets. This allows for percutaneous removal and replacement of leaflets while leaving the annulus intact. Not only does it provide for exchangeable leaflets, it is also repositionable, has flexible stent posts, does not

provide coronary overlap in the aortic position, and features symmetrical leaflets and a circular stent (see Figure 5-13).(185)

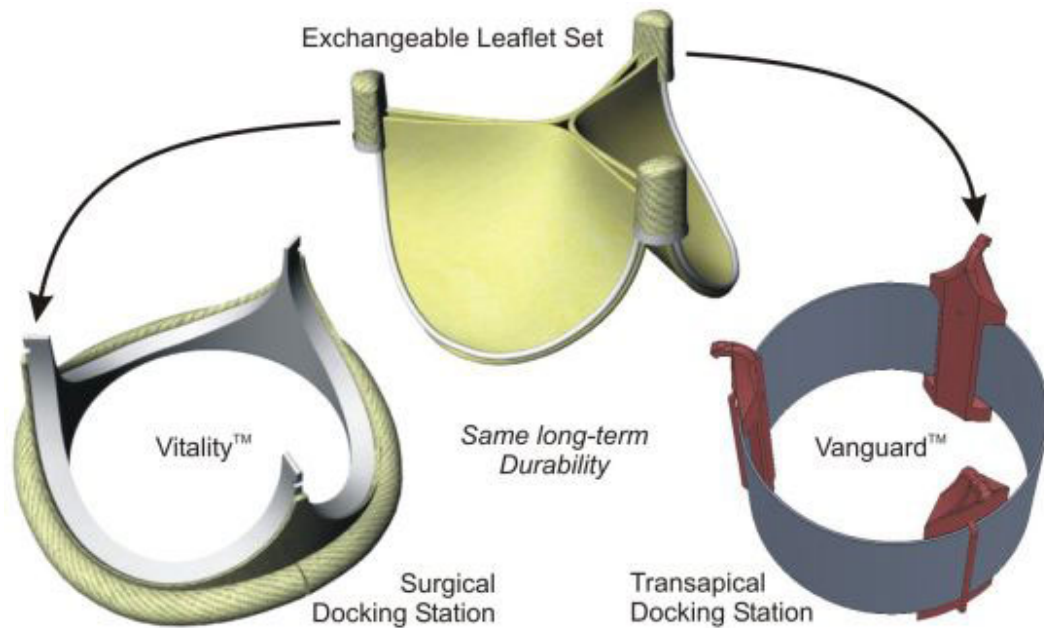


Figure 5-13: ValveXchange valve components (ValveXchange Inc., Aurora, CO, USA) (188)



Figure 5-14: Assembled ValveXchange valve (185)

This is not the first exchangeable leaflet design mentioned in the scientific literature. As early as 1988, the design of a replaceable valve prosthesis was mentioned by Cooper *et al.* (189). This involved a somewhat rudimentary design concept using a circlip (see Figure 5-15), although other design concepts were discussed. (189) More recently, however, in 2007, Fukamachi *et al.* (190) described a replaceable heart valve using a magnet ring locking mechanism (see Figure 5-16a-c) and even went as far as to implant it in three sheep. Their study showed that a replaceable valve design was possible.(190) In addition, Ebner *et*

*al.* (191) recently discussed a three-part valve with flexible stent posts and exchangeable leaflets (see Figure 5-17).(191)

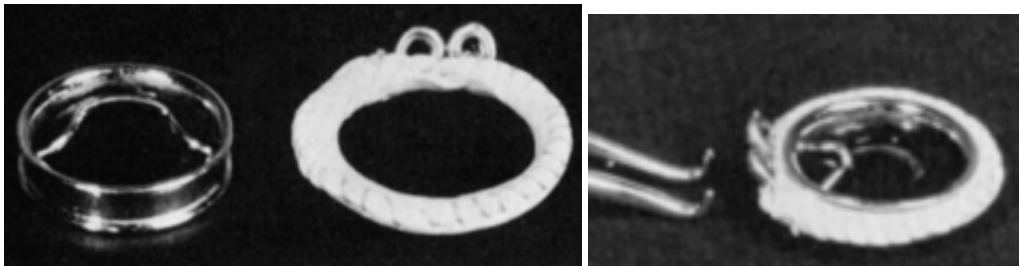


Figure 5-15: Bjork Shiley prosthesis on left with sewing ring embedded with a circlip (left) and valve assembly with detachable annulus(right) (189)

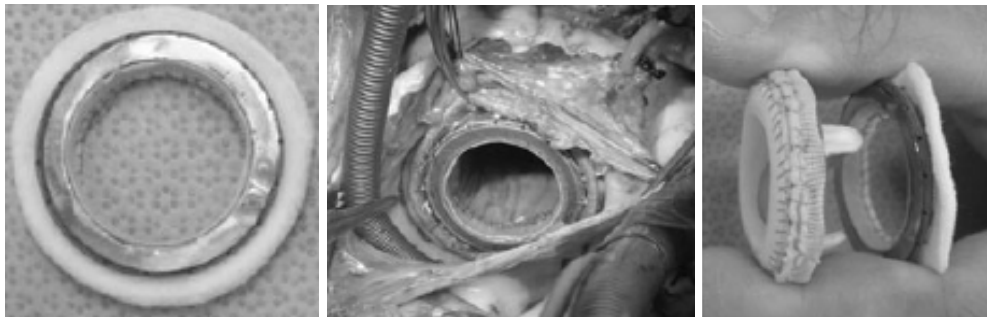


Figure 5-16: Prototype of replaceable valve by Fukamachi *et al.* (190), Base magnetic ring (left) and magnetic annulus implanted in mitral valve position (middle) and assembly mechanism (right)(190)

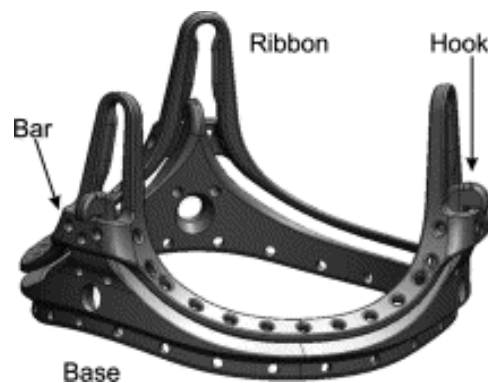


Figure 5-17: Schematic of Ebner *et al.*'s (191) assembled three-part replaceable valve design (191)

So far, none of these replaceable valve leaflet designs incorporate the concept with percutaneous implantation. Only ValveXchange combines both technologies.

The next generation percutaneous heart valves aim to address the shortcomings of the first valves, the Melody, CoreValve and Sapien valves. However, until then problems with procedural complications including stroke, vascular trauma, coronary blood flow interruption and conduction disturbances leading to heart block and the need for permanent pacemaker implantation must first be addressed. (159,192)

Percutaneous valve implantation has been widely reported in adults, but where it has been suggested for use in children, few reports provide the relevant clinical data. With delivery systems ranging on average between 22Fr to 26Fr (7.3 mm to 8.7 mm) capable of implanting 23 mm to 26 mm diameter valves, only device deployment in adults or older children is catered for. Sheaths suitable for children, at 18Fr (6 mm) size, can implant a 20 mm valve. Ideally smaller, than 18Fr (6 mm) sheaths would best for use in children. Despite the lack of available small transcatheter valves they have still been implanted in children as young as 10 months.

Feinstein *et al.* (193) reported a case of a percutaneous implantation of a pulmonary valve in a 10-month old infant with Shone's complex and co-existing mitral and aortic stenosis. It became the first case reported for an infant, and at the time (2005) of the procedure this patient was the youngest patient to receive a percutaneous valve. Due to the small anatomical size of the infant, the authors constructed their own percutaneous valve from a 12 mm Hancock valved conduit and mounted it into a stent without the conduit. This 'off-the shelf' valve was then mounted on a 12 mm balloon and implanted with a 7Fr (2.3 mm) and 16Fr (5.3 mm) sheath via the right internal jugular vein. Prior to the procedure, the patient had undergone a Ross procedure, with a 12 mm pulmonary homograft that failed, leading to severe pulmonary regurgitation. The patient was an extremely high-risk patient and thus percutaneous valve implantation was used. The authors concluded that although percutaneous pulmonary implantation is feasible in an infant, there is a need for smaller delivery systems.(193)

Other percutaneous valve implantations were reported for children, but generally children older than 10 years. Bonhoeffer *et al.* (194) reported a series of pulmonary valve placements in seven children between the ages of 10 and 17 years. All the children in the series had had previous surgeries, including failed bioprosthetic conduit placement. The authors used 16 mm and 18 mm bovine jugular vein valves, which they mounted on a stent and placed in a 18Fr (6 mm) to 20Fr (6.7 mm) catheter. At 10 months follow-up, the patients showed symptom improvement and no complications were found during early follow-up.(194)

Vezmar *et al.* (137) reported a 2-year follow-up of 28 adolescents, 10.9 to 19 years old, with percutaneously implanted pulmonary valves. The results were deemed good, with freedom from surgery and transcatheter re-intervention at 36 months at 83% and 80%, respectively. The study shows that the procedure was safe and feasible to be used in older children.(137) Boudjemline *et al.* (195) implanted a pulmonary valve into a 12-year old child and at 24 months also showed good results with a competent valve.(195)

A few other studies by McElhinney *et al.* (196) and Khambadkone and Bonhoeffer (197) reported the short- and medium-term outcomes in children older than 7 years, but generally older than 9 years, and weighing more than 20 kg, with pulmonary implanted valves.

In Khambadkone and Bonhoeffer's (196) study, pulmonary valves were implanted due to pulmonary atresia or absent valve as a consequence of ToF. The freedom from device removal due to failure was reported to be 89%, 83.3%, 79.7% and 69.8% at 6, 12, 24, 36 months, respectively. This was lower than expected (91.7% at 24 months), because they constructed their own valve with a platinum-iridium stent and a bovine jugular vein valve. They experienced device-related problems with their valve design, as it became stenotic due its loosening from the stent.(197)

McElhinney et al. (196) used the Melody pulmonary valve and reported the short and medium outcomes in children older than 7. years They noted that younger children were at higher risk of valve dysfunction and hence had shorter freedom from valve-related failure.

The very first percutaneous tricuspid implantation series was documented by R. Robert et al. (198) in 2011. It included two paediatric patients, aged 8 and 9. Both had had previous tricuspid valve implantations. Failure of these previous implants resulted in the use of a 23 mm percutaneous tricuspid valve for both patients. The potential of transcatheter valve implantation in the tricuspid position was demonstrated to be feasible, albeit for very high-risk patients. Prior to the series, such valve implantation was only implanted in animals by Boudjemline and colleagues in 2005.(182)

Unlike with the tricuspid valve, it is unlikely that much attention will be given to percutaneous mitral valve implantation, because percutaneous repair is favoured, while valve replacement is avoided due to its poor prognosis.(182)

A common finding in all the studies presented here, reflected in a general comment made by all the authors, was that the size mismatch between the devices and femoral vessels in small children was a significant limitation in device implantation.(199) Similarly, children with a RVOT greater than 22 mm were not suitable candidates for the procedure. This meant that sheath sizes of 21Fr (9.93 mm) could only be used in children older than 5 years and weighing more than 20 kg. Small valve size was also noted to contribute to early complications. In addition, the valve for the aortic position needs to be smaller to minimize damage to the often problematic vessels and to limit disruption to the systemic blood flow.(159)

Other limitations involved the use of bioprosthetic valves. They were still prone to calcification and degeneration, raising the problem of valve durability. Bioprosthetic valves are fragile, which makes them problematic to mount on a stent without damaging the tissue. This potential for damage, combined with

the valves starting to dehydrate prematurely pre-implantation, necessitates that the valve be crimped into the catheter sheath at the time of the procedure. With early designs, stent failure was found as a result of fracture. This resulted in valve dysfunction as a consequence of instability and restenosis.(182) Problems were experienced with correctly positioning the valve prior to deployment and as a consequence increased the concern of device migration. Because the device cannot yet be percutaneously removed, the procedure requires great skill by the surgeon to correctly seat the valve before final deployment. It is particularly difficult when implanting an aortic valve, because of its proximity to the mitral valve and coronary artery sinuses, with some designs blocking them.

The less invasive nature of percutaneous valve replacement procedures is immediately evident in that beating heart surgery is made possible and thus the need for cardiopulmonary bypass is eliminated. Therefore the risks associated with cardiopulmonary bypass were eliminated and opened up possibilities for high-risk patients to be considered for valve replacement who would otherwise not receive a prosthetic valve. Such a minimally invasive technique also allows for quicker time to recovery and lower cost of therapy.(159)

Despite these advantages, the greatest limitations for the use of percutaneous procedures in a paediatric patient are the valve design and delivery system and their inability to be significantly reduced in size. Large sheaths are problematic, not only because they risk vascular trauma, but also because they cannot be used in small children with small femoral vessels.(159)

Due to the non-invasive nature of device deployment, percutaneous heart valves have been classed (in the European CE system) as a Class IIa device, a lower device risk classification than surgical valve replacements, a Class III device. Others suggest that percutaneous valves should be classified under the lowest medical device rating, Class I.(87)

## 5.2.4 Novel cardiovascular materials: polymeric valve and eNitinol

There are numerous novel cardiovascular materials emerging in the field of paediatric cardiac research. Those that have been shown to be promising as heart valve materials are polymeric heart valve and eNitinol, a thin film nitinol membrane. Below, there is a brief outline of recent developments with these two novel materials.

### 5.2.4.1 Polymeric heart valves

Although polymeric heart valves (see Figure 5-18) are not currently in use as valve replacements, research on them has come a long way since they were first introduced in the 1950s.(159) Modern polymeric valves address the issue of thrombosis and valve degeneration or bio-instability experienced with the first generation polymeric valves. Although these first generation valves have had many pitfalls, they have provided invaluable information allowing the advance of modern polymeric material into clinically feasible biomaterials for use in artificial heart devices and pacemaker leads.(200–202)

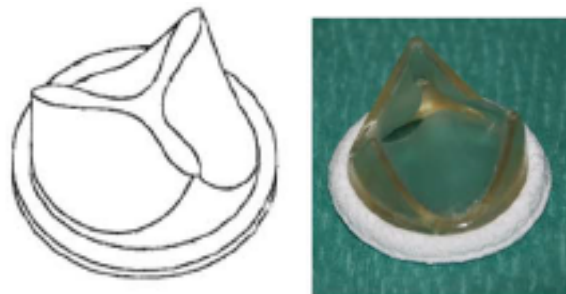


Figure 5-18: Representation of a possible Polymeric heart valve design (left) and a manufactured PHV with Dacron suturing ring (right)(162)

Modern polymeric heart valves, in theory, have the advantage of mechanical valve durability while exhibiting improved haemodynamic properties, as is present with bioprosthetic valves. In addition, surface-modified polymers obviate the need for anticoagulation therapy, due to their improved biocompatibility.



Although there are numerous polymeric materials that have been studied for use as heart valves, polyurethanes have outperformed other polymers such as PTFE (Teflon), silicone and collagen.(162,203). Suitable bulk material properties can be obtained so that the valve can haemodynamically match native heart valves without compromising valve durability. This allows the leaflets to open more fully than mechanical valves. In turn, this leads to better valve durability, due to lower pressure drop across the valve (as a high pressure drops tends to cause valvular degradation).(202) In addition, a specific leaflet configuration and thickness profile can be obtained to match native heart valves. In the case of aortic valves, a tricuspid leaflet configuration can be achieved and an asymmetric bileaflet design can be produced for the mitral valve.(162) It is clear that the haemodynamic performance of polyurethane valves is superior to those of mechanical valves.

Recently, new materials have emerged due to the advances of material science and nanomaterials. Such novel nanomaterials include polyhedral oligomeric silsesquioxane (POSS), a new generation in modified materials that may provide even better degradation resistance and greater biocompatibility than the first generation polymeric valves while exhibiting lowered thrombogenicity.(204) This may provide the desired heart valve leaflet properties for use in valve replacements, and percutaneous heart valve procedures could benefit significantly from the use of such materials.(162)

Despite the vast improvements in material science, polymeric valves still exhibit calcification, although this is markedly lower than with first generation materials. This calcification leads to leaflet stiffening and thus tearing and premature failure, making such valves less than ideal as a long-term clinical solution for heart valve replacements. In future, a better understanding of the calcification model in human valves may allow further improvements in material modifications. (162,203)

Polyurethanes allow for a broad range of physical properties. It is this quality, combined with their excellent biocompatibility that has made polyurethanes

successful in clinical use in pacemaker leads and artificial hearts and assist devices. Unfortunately, although the material is promising for prosthetic heart valves, it remains a material that raises great debate. Much research has gone into it, but there is still no clinically approved device on the market today.

Polymeric heart valves have a flexible structure – they have a similar stiffness to native valves and they can move freely, with the heart contracting and expanding. This is particularly useful for movement in the aortic root.(133)

It is likely that polymeric valves will become possible in the future, however, such materials must first survive strict regulation and clinical studies in humans, which have yet to be performed. There is one valve that is already close to clinical trials in humans (162), but so far, the clinical outcome of polymeric valves in humans is still unknown. Only time will tell how feasible this option will be as a material for long-term valve replacement.

#### **5.2.4.2 eNitinol: thin film nitinol**

Heart valve replacement technology has taken a new direction over the last decade, particularly since the introduction of shape memory materials such as Nitinol, now commonly used as a stent material. eNitinol, a thin film nitinol membrane, is a thinner version of the traditional stent nitinol. It has suitable properties as a valve leaflet material. This material has been used in the development of the PercValve, a percutaneous, all synthetic heart valve.(187)

eNitinol has been researched as a biocompatible leaflet material for use in paediatric heart valves, since small valve sizes (<5Fr or <1.67 mm) can be obtained.(187) Like polymeric valves, this technology merges the advantages of mechanical and bioprosthetic valves. It provides for high durability without the need for anticoagulation medication, because the material does not elicit a biological response in the host, as it can be readily endothelialised, at least in theory.

In the PercValve design, the entire valve is manufactured from this novel material. It can be percutaneously implanted and is a self-expandable valve placed in a 4.3-10Fr (1.43 mm to 3.33 mm) sheath. Other advantages of the PercValve is that it has a low profile design and is not prone to calcification. (187)

UCLA Active Materials Laboratory is currently studying the PercValve, for intended use in the paediatric population. To date no data are available confirming the claimed advantages, nor has the valve been implanted in humans. If results are promising, then this will be the first percutaneous mechanical valve available, and the paediatric valve population would benefit greatly from such an advance.(187).

### 5.3 Paediatric valve rationale: the challenge

There are many features that are sought in an ideal heart valve. These features have been dubbed the ‘ten commandments’ for any ideal prosthetic heart valve. (164)

A list of the criteria, consisting of the necessities and recommendations in the pursuit of an ideal heart valve, is given in Table 5.1. The rationale behind these design and functional recommendations is also presented here.

Design feature	Description
<b>Durability</b>	<ul style="list-style-type: none"> <li>• Longevity: At least 7-10 years, if not for patient’s lifespan</li> <li>• Geometric and structural durability</li> <li>• Durability under a variety of haemodynamic conditions</li> </ul>
<b>Growth potential</b>	<ul style="list-style-type: none"> <li>• Ability to grow with the patient or at least expand gradually with somatic growth</li> </ul>
<b>Product availability</b>	<ul style="list-style-type: none"> <li>• Availability in sizes &lt; 20 mm</li> <li>• Ease of handling</li> <li>• Absence of logistical problems – if assembling is required</li> </ul>
<b>Surgery</b>	<ul style="list-style-type: none"> <li>• Minimal invasiveness</li> <li>• Minimal healing and recovery time</li> </ul>

<b>Design feature</b>	<b>Description</b>
	<ul style="list-style-type: none"> <li>• Minimal damage caused to other anatomical structures</li> </ul>
<b>Device positioning</b>	<ul style="list-style-type: none"> <li>• Secureness – permanent fixation with no risk of device loosening</li> <li>• Inter-operative repositionability</li> <li>• Potential for removal and replacement - exchangeable leaflets or valve-in-valve</li> </ul>
<b>Geometry</b>	<ul style="list-style-type: none"> <li>• Circular with precise central gap</li> <li>• 120° leaflet symmetry</li> <li>• Efficient valve opening and closing &lt;0.05 seconds</li> <li>• Maximum effective orifice area</li> <li>• No paravalvular leakage</li> </ul>
<b>Material</b>	<ul style="list-style-type: none"> <li>• Biocompatibility</li> <li>• Minimal damage to blood</li> <li>• Easily endothelialised</li> <li>• Resistance to wear and degradation -non-biodegradable valve</li> <li>• Non-calcific</li> <li>• Minimal degradation products - must be biocompatible</li> </ul>
<b>Affect on blood and tissue</b>	<ul style="list-style-type: none"> <li>• Inertia -Non-haemolytic, non-thrombogenic, non-infection, non-immunogenic, non-inflammatory, non-calcific</li> <li>• Non-resistance to blood flow</li> </ul>
<b>Sterilization</b>	<ul style="list-style-type: none"> <li>• Easily sterilization</li> </ul>
<b>Imaging</b>	<ul style="list-style-type: none"> <li>• MRI compatibility</li> </ul>
<b>Valve specific design features</b>	<ul style="list-style-type: none"> <li>• Aortic valve – no coronary overlap</li> <li>• Tricuspid and mitral valve – no effect on valvular complex components</li> </ul>
<b>Other possible design feature</b>	<ul style="list-style-type: none"> <li>• Possibly exchangeability of leaflets</li> <li>• Flexibility of stent posts</li> </ul>
<b>Other</b>	<ul style="list-style-type: none"> <li>• Quietness</li> </ul>

Table 5-1: List of design features sought in an ideal paediatric heart valve (96,122,133,154,164)

In pursuit of a paediatric heart valve, the limitations of growth, durability and size availability are central to the effective functioning of the valve in the young population.

Firstly, the valve must be able to withstand structural and geometrical changes in the heart as the child grows. Its durability must therefore not be adversely affected under a range of haemodynamic conditions during rest and activity. Ideally, the valve should last a patient's lifespan,  $\pm 40$  years, but if this is not possible, it must last at least 10 years.

This durability and function must not be compromised by somatic growth. This requires that the valve must show growth potential by expanding gradually during somatic growth. This expansion must be gradual, otherwise severe cardiac shock will result as a consequence of drastic changes in haemodynamics. It is therefore best that the valve be able to enlarge on its own without the need for manual enlargement by a surgeon. Growth potential ensures minimal patient-prosthesis mismatch and thus continued excellent haemodynamics over the device's lifespan. This reduces the need for re-operations and decreases the overall risk of patient mortality.

These functions may be excellent in a particular valve, but if the device is not available in small enough sizes, then the use of larger valves is necessitated. This results in a patient-prosthesis mismatch, with poor associated clinical outcomes, increasing the risk of mortality.

Smaller valves, less than 20 mm, may be trickier to handle. Thus they may not be so fragile that implanting them becomes near impossible. The need for handling the valve must be minimized so as not to compromise the device and/or adjacent cardiac structures during implantation. In addition, if the valve needs to be handled, for example, when repositioning during seating, such handling should not adversely affect it to such an extent that its function is compromised. In securing the valve in place, the seating must be permanent without the risk that the device will loosen from the annulus.

With this in mind, it is best if the procedure is minimally invasive. This limits device handling to some extent and causes significantly less trauma than conventional open-heart surgery. The aim is to cause minimal physiological

damage (limiting the need for surgically intervening in other previously healthy structures), to reduce recovery time and to improve quality of life. This must be the focus of the surgical technique used to implant a valve.

A percutaneous approach is a possible answer to the need for minimal interference. However, it must be considered in the light of the other possible congenital defects a patient may have. It is of little use to implant a valve percutaneously when the repair of other cardiac structures necessitates open-heart surgery. In a child with congenital defects, this may well be necessary during the first surgical intervention. However, thereafter, if the valve needs to be replaced, percutaneous valve removal and replacement may be suitable. This shows the importance of considering the need for repair of other cardiac structures beside valve replacement when designing a paediatric heart valve.

Valve design factors involve the selection of a suitable material and geometrical design. The geometrical configuration of a trileaflet valve should show  $120^\circ$  symmetry. This is to ensure a central flow profile that ensures that no one particular leaflet experiences more stress and strain than another.

The valve must open and close efficiently, taking less than 0.05 seconds to do so, and must operate quietly. In addition to quickly opening and closing, it must do so in an easy manner, that is without the need for excessively high pressures to force the valve open or closed. When open, it must produce a large open orifice with the leaflets open as far as possible. This means it must allow for unrestricted blood flow through the valve by creating the greatest possible effective orifice area in relation to the valve size. When the valve is closed, it must seal properly to limit paravalvular and central regurgitation through the valve. If the regurgitation during closure is too high then the heart must pump harder in order to produce the same cardiac output. This may lead to heart failure, which is precisely what should be avoided by using a valve prosthesis.

All these design features must be incorporated using biocompatible materials. Thus the materials may not adversely affect tissue by causing necrosis or

damage to the blood components. An example of how blood components can be damaged during valve closure is shown in Figure 5-18, which shows a mechanical aortic heart valve with paravalvular and central leakage. These tiny openings allow blood to leak through the valve, damaging red blood cells by means of shear. This damage leads to the destruction of the red blood cells (haemolysis).(133)

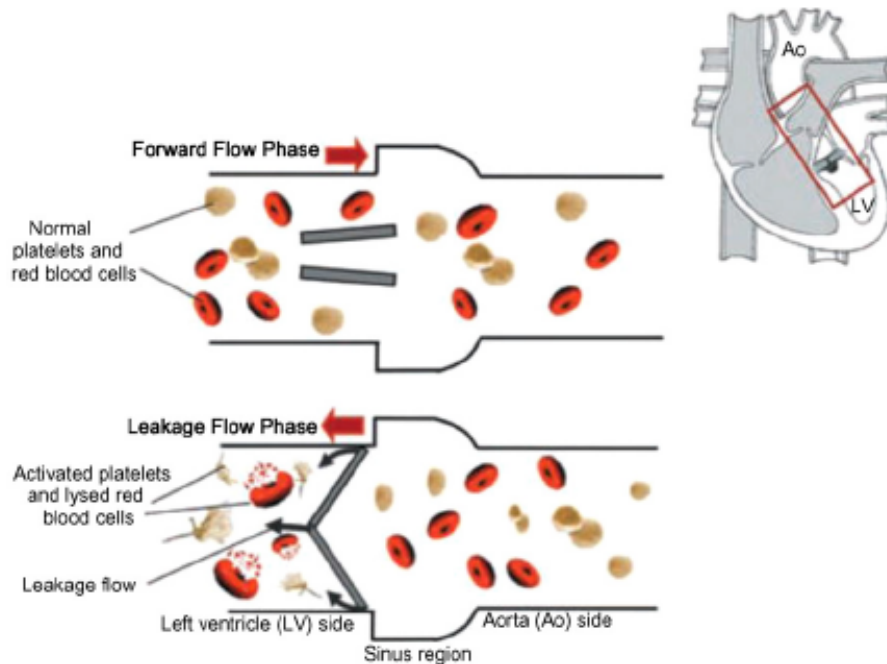


Figure 5-19: Schematic description of the damage caused to blood cell components during valve closing and as a result of leakage during closure (133)

In order for the device to be considered biocompatible, the materials used and their combination of use may not induce a biological reaction in the body. In other words, the materials must be biologically inert, by being non-haemolytic, non-thrombogenic, non-immunogenic (non-infection and non-inflammatory) and above all non-calcific.

In addition to all these factors, to encourage material biocompatibility, the valve must be easily endothelialised so that the exposure of the foreign material to blood is limited. This will encourage resistance to wear and degradation. However, if the valve does show signs of degradation, then the debris must also be biocompatible.

In addition the valve should be easily and properly sterilized to limit biological responses in the host. It should also be MRI compatible, where possible, as this imaging modality may be needed at some point during the individual's lifetime.

A few design features to take into consideration with the aortic and atrioventricular valves are the need for there to be no obstruction of the coronary arteries and no impact on the valvular complex components, respectively. Other design features that might be of use is the consideration of having exchangeable leaflets so that they can be quickly and easily replaced if necessary and flexible stent posts in order to minimize stresses and strains experienced by the valve.

A very important factor to consider when dealing with the many technical challenges mentioned above is the quality of life of the patient. The quality of life of a paediatric and eventually adult patient depends on many factors. Medical factors include obviating the need for anticoagulation therapy and prolonging valve durability in such a way that the individual's activities of daily life are affected as little as possible. Other factors include the patient's readiness to undergo surgery and the ultimate acceptance of lifestyle changes that will occur. Such changes should not include an endless list of dos and don'ts, as the patient may not comply with them.

Finally, although growth potential is fundamental to valve-related procedures in children, other requirements depend on co-existing defects and how they influence prosthesis function. It is necessary to narrow down the associated defects to those that have an adverse impact on valve prosthesis, compromising its function and leading to re-intervention. A potential example would be a repaired atrioventricular septal defect where scarring might impede prosthetic valve placement. An alternative possibility is the interaction of a prosthetic valve with an occluder device, such as the Amplatzer, used to close ventricular septal defects (see Figure 5-20).



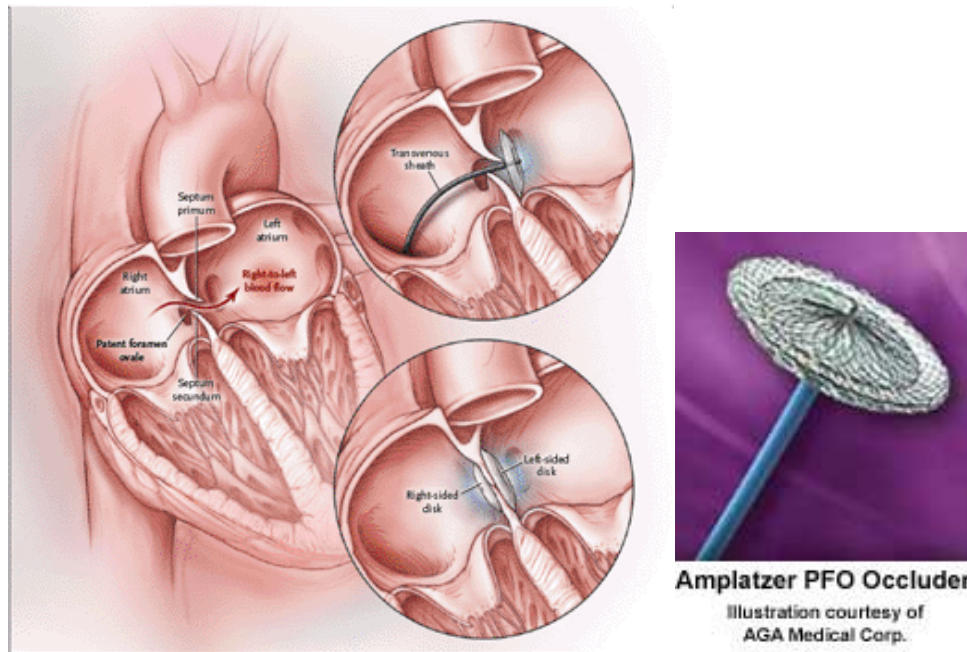


Figure 5-20: a) An occluder used to patch an atrial septal defect and b) The Amplatzer patent foramen ovale (PFO) occluder (205)

If device implantation is too complex and technically demanding on a surgeon, it is less likely to be widely adopted. Not all paediatric surgeons have the same level of experience. Similarly, not all will easily adopt controversial procedures. When dealing with high-risk patients, such as the paediatric cardiac population, surgeons may prove reluctant to accept new technology that does not provide a clear advantage and improvement in the patient's quality of life.

This is a concise description of the general design features sought in a paediatric heart valve. It is not possible for all of these requirements to be met fully. So, for example, the body will always have a biological response to foreign material, but as long as this response is limited and within reason there should be no cause for serious concern.

The next question is how to achieve the design of such a valve. Hence, the literature review concludes with some suggestions on where research should go next to meet the challenge of creating an ideal paediatric valve.

#### **5.4 Meeting the Challenge: where to from here?**

Having carried out this literature survey, only paediatric-size heart valves, rather than paediatric valves, have been found. There are remarkable differences between a paediatric-size valve versus a paediatric valve. Although they may seem synonymous, a paediatric-size valve is simply an adult valve down-sized to meet the anatomical need of a smaller patient. It does not provide for growth and hence does not lower the need for re-intervention at a later stage when the patient outgrows the valve.

A paediatric valve, on the other hand, addresses such shortcomings and takes into consideration both the clinical outcome in terms of cardiac function, and a more holistic view of the patient's quality of life (health, activities of daily living and psychosocial well-being). To this day, there is no paediatric heart valve, largely due to the inability of a valve to grow with the patient.

Currently, even paediatric-size valves are few and far between. They invariably come with lifestyle compromises and high associated morbidity. It is the lack in availability of paediatric valve prostheses that complicates matters in managing congenital valve defects in children. Despite much effort to avoid valve replacement, by palliative shunting, valvuloplasty or valvotomy procedures, it is not always possible to do so. Although procedural technique advancements are currently used to make up for the lack of small valves available, through annular enlargement and other procedures, this has not alleviated the need for better and smaller prostheses. On the contrary, it has revealed a greater need for them.

With paediatric patients' living longer than ever before and now contributing to the GUCH population, the need for more durable paediatric valve prostheses will only increase in the coming years, despite of the low number of valve implantations performed in the paediatric population, compared to the number in the adult population.

The debate of mechanical versus bioprosthetic valves is on-going, with no clarity on the superiority of either prosthesis type. Thus it may be best to aim towards combining the advantages of both types, similar to what is being done with polymeric heart valves, for example. This might be a good start in addressing currently available mechanical and bioprosthetic valve limitations regarding valve size, growth and durability. Regardless of the final direction that is adopted, mechanical or tissue based, the focus must remain on meeting the quality of life requirements of the young individual.

Since thus far no valve has been produced that meets these requirements, it may be necessary to broaden the research field and not focus purely on what is being done in valve replacement technologies. Much insight can be gathered by investigating cardiac interventional technologies, which includes valve clips and coronary sinus annuloplasty devices. Much can be learned from such technologies with regard to their shortcomings, procedural complications, device design and material use. This might bring new developments to the understanding of how to go about designing a paediatric heart valve.

A very important factor in the design and development of paediatric heart valves is the choice of material and surgical procedure. With promising materials, such as eNitinol used in the PercValve and those used in polymeric heart valves, the pursuit of a durable leaflet material may be realised. Similarly, minimally invasive approaches, such as percutaneous valve implantation, may bring about a reduction in the need for invasive surgery. A good starting point may be combining all of these technologies: percutaneous implantation for its minimally invasive nature, polymeric leaflets for its durability and the added feature of exchangeable leaflets for quick and easy valve replacement over the individual's lifespan. The combination of such features may contribute to a further reduction in the risk of morbidity and mortality.

Although no device will ever truly be risk-free, risks can be minimized and controlled to some extent. Such a reduction in risks can also be obtained with a better understanding of the nature of disease, thereby matching the correct

valve treatment strategy to a patient on an individual basis. It may be that having different valve designs available to address different diseases might be beneficial, but this will undoubtedly add to logistical complexity. Thus the degree of complexity is most likely to outweigh the small advantage, which individualized valve designs might bring. Instead, it may be best to focus on one valve design for all valvular diseases.

It may be also necessary to focus on a particular valve category, the semilunar valves. This is because the pulmonary and aortic valves are most commonly affected by disease in the young, while the atrioventricular valves present a significantly lower need for replacement technologies. However, the need for mitral and tricuspid valve replacement should not be entirely ignored. They should at least be taken into consideration during the initial semilunar valve design process, so that in time, if need be, the same design, or an adaptation thereof, can be used to develop atrioventricular valves.

Design is an iterative process. This can be seen with percutaneous valves now emerging in their third generation, addressing the shortcomings of the first designs. With 2012 marking a decade since the first TAVI, only a handful of valve designs have been approved for use in the general population, of which only one, the Medtronic Melody Pulmonary valve, has been FDA approved for use in the paediatric population.

It is therefore most likely that the same will happen in the pursuit of a paediatric valve. Many valve designs may be introduced, but only a handful will be clinically feasible and safe. However, this should not deter continuing research in the field. Instead, it should highlight the fact that addressing the need for paediatric valves should not be postponed, especially since tissue engineered heart valves will not become a reality soon and other options in the surgeon's armamentarium (e.g. valvuloplasty, valvotomy etc.) are not as effective as valve replacement.

The many technical challenges in developing a paediatric valve presents a number of hurdles to both clinicians and engineers. Both must undergo a steep learning curve in pursuit of the optimal solution. However, despite the sometimes overwhelming obstacles, there is great potential to overcome many hurdles by applying that, which has been already implemented within the medical field.

Last but not least, it is necessary that clinicians collaborate with engineers in pursuit of a paediatric heart valve. Only then can the quest for such a valve be truly realized. This literature review shows that although designing a paediatric heart valve, for any one or all the valve positions, is technically challenging and although success will not come overnight, the challenge is not insurmountable.

## REFERENCES:

1. Alsoufi B, Manlhiot C, McCrindle BW, Canver CC, Sallehuddin A, Al-Oufi S, et al. Aortic and mitral valve replacement in children: is there any role for biologic and bioprosthetic substitutes? *European Journal of Cardio-Thoracic Surgery : Official Journal of the European Association for Cardio-Thoracic Surgery* [Internet]. 2009 Jul [cited 2012 Apr 30];36(1):84–90; discussion 90. Available from: <http://www.ncbi.nlm.nih.gov/pubmed/19369085>
2. Ruzmetov M, Vijay P, Rodefeld MD, Turrentine MW, Brown JW. Evolution of aortic valve replacement in children: a single center experience. *International Journal of Cardiology* [Internet]. 2006 Nov 10 [cited 2012 Jun 3];113:194–200. Available from: <http://www.ncbi.nlm.nih.gov/pubmed/16376439>
3. Nkomo V, Gardin J, Skelton T. Burden of valvular heart diseases: a population-based study. *The Lancet* [Internet]. 2006 [cited 2012 Aug 8];36B:1005–11. Available from: <http://www.sciencedirect.com/science/article/pii/S0140673606692088>
4. Butcher JT, Mahler GJ, Hockaday L a. Aortic valve disease and treatment: the need for naturally engineered solutions. *Advanced drug delivery reviews* [Internet]. Elsevier B.V.; 2011 Apr 30 [cited 2012 Mar 10];63:242–68. Available from: <http://www.ncbi.nlm.nih.gov/pubmed/21281685>
5. Supino P., Borer JS. The epidemiology of valvular heart diseases: the problem is growing. In: Borer JS, Isom O., editors. *Pathophysiology, evaluation and management of valvular heart diseases volume 2 Advances in Cardiology* [Internet]. New York: Karger; 2004 [cited 2012 Aug 9]. p. 9–15. Available from: <http://books.google.com/books?hl=en&lr=&id=dOXezUal-gcC&oi=fnd&pg=PA9&dq=The+epidemiology+of+valvular+heart+disease:+the+problem+is+growing&ots=BxfTJ-iMCW&sig=NrAZnVo7eQm7v24owpQUIiUEatk>
6. Bar-Dayyan Y, Elishkevits K, Goldstein L, Goldberg A, Ohana N, Onn E, et al. The prevalence of common cardiovascular diseases among 17-year-old Israeli conscripts. *Cardiology* [Internet]. 2005 Jan [cited 2012 Jun 3];104(1):6–9. Available from: <http://www.ncbi.nlm.nih.gov/pubmed/15942176>
7. Iaizzo PA. General Features of the Cardiovascular System. In: Iaizzo PA, editor. *Handbook of Cardiac Anatomy, Physiology, and Devices*. 2nd ed. Minneapolis: Springer; 2009. p. 3–12.
8. Hinton RB, Yutzey KE. Heart valve structure and function in development and disease. *Annual review of physiology* [Internet]. 2011 Mar 17 [cited 2012 Mar 8];73:29–46. Available from: <http://www.ncbi.nlm.nih.gov/pubmed/20809794>
9. Weinhaus AJ, Roberts KP. Anatomy of the Human Heart. In: Iaizzo PA, editor. *Handbook of Cardiac Anatomy, Physiology, and Devices* [Internet]. 2nd ed. Totowa, NJ: Humana Press; 2009 [cited 2012 Apr 1]. p. 59–85. Available from: <http://www.springerlink.com/index/10.1007/978-1-60327-372-5>
10. Schneck DJ. An outline of cardiovascular structure and function. In: Bronzino JD, editor. *Biomedical Engineering Handbook* [Internet]. 2nd ed. Boca Raton: CRC Press LLC; 2000 [cited 2012 Jun 4]. Available from: <http://books.google.com/books?hl=en&lr=&id=HBps207cORgC&oi=fnd&am>

p;pg=PA4&dq=An+Outline+of+Cardiovascular+Structure+and+Function&ots=vte  
wlsChmc&sig=QJuj9Xfr2SXu7DEFQJM36bFKCFE

11. Health Personal Inc. Human Heart Anatomy [Internet]. Human Health Education. 2009 [cited 2012 Aug 8]. Available from: <http://labelled-diagram-of-the-human-heart.blogspot.co.uk/2009/07/human-heart-atomy.html>
12. Martini F, Judi LN, Edwin EF. Fundamentals of Anatomy and Physiology [Internet]. 9th ed. Boston: Benjamin Cummins; 2011 [cited 2012 Jun 4]. p. 669–763. Available from: <http://www.mendeley.com/research/fundamentals-of-anatomy-and-physiology/>
13. Svensson L. Diseases and Conditions [Internet]. The Cleveland Clinic. 2012 [cited 2012 Aug 8]. Available from: [http://my.clevelandclinic.org/heart/disorders/bicuspid\\_aortic\\_valve\\_disease.aspx](http://my.clevelandclinic.org/heart/disorders/bicuspid_aortic_valve_disease.aspx)
14. Anderson R, Baker E, Penny D, Redington A, Rigby M, Wernovsky G. Paediatric cardiology [Internet]. 3rd ed. Cardiology in the. Churchill Livingstone; 2003 [cited 2012 Jun 4]. Available from: <http://journals.cambridge.org/production/action/cjoGetFulltext?fulltextid=306956>
15. Otto CM, Bonow. Valvular heart disease: a companion to Braunwald's heart disease [Internet]. 3rd ed. Otto C, Bonow R, editors. Valvular heart disease: a companion to Braunwald's heart disease. Philadelphia: Saunders Elsevier; 2009 [cited 2012 Jun 4]. Available from: <http://onlinelibrary.wiley.com/doi/10.1002/cbdv.200490137/abstract>
16. Schoen FJ. Mechanisms of function and disease of natural and replacement heart valves. Annual review of pathology: Mechanisms of Disease [Internet]. 2012 Jan [cited 2012 May 11];7:161–83. Available from: <http://www.ncbi.nlm.nih.gov/pubmed/21942526>
17. Silbiger JJ, Bazaz R. Contemporary insights into the functional anatomy of the mitral valve. American Heart Journal [Internet]. Mosby, Inc.; 2009 Dec [cited 2012 Apr 3];158(6):887–95. Available from: <http://www.ncbi.nlm.nih.gov/pubmed/19958853>
18. Schoen FJ. Cardiac valves and valvular pathology: update on function, disease, repair, and replacement. Cardiovascular pathology : the official journal of the Society for Cardiovascular Pathology [Internet]. 2005 [cited 2012 Mar 10];14(4):189–94. Available from: <http://www.ncbi.nlm.nih.gov/pubmed/16009317>
19. University of Southern California. Cardiothoracic and Vascular Program Heart Valve Laboratory [Internet]. University of Southern California Keck School of Medicine. 2012 [cited 2012 Aug 8]. Available from: <http://www.cts.usc.edu/research-heartvalvelaboratory.html>
20. Waite L. Biofluid Mechanics in Cardiovascular Systems. New York: McGraw-Hill; 2006.
21. Duke University School of Medicine. The semilunar valves Aortic root disease [Internet]. Echo in Context. 2000 [cited 2012 Jul 25]. Available from: [http://www.echoincontext.com/int1/skilli1\\_15.asp](http://www.echoincontext.com/int1/skilli1_15.asp)
22. Feldman T, Kar S, Rinaldi M. Percutaneous Mitral Repair With the MitraClip system Safety and midterm durability in the initial EVEREST (Endovascular Valve Edge-to-Edge REpair Study ) Cohort. Journal of the American College of Cardiology [Internet]. American College of Cardiology Foundation; 2009 [cited 2012 Aug 8];54(8):686–94. Available from: <http://dx.doi.org/10.1016/j.jacc.2009.03.077>

23. Sacks MS, David Merryman W, Schmidt DE. On the biomechanics of heart valve function. *Journal of Biomechanics* [Internet]. Elsevier; 2009 Aug 25 [cited 2012 Mar 21];42(12):1804–24. Available from: <http://www.pubmedcentral.nih.gov/articlerender.fcgi?artid=2746960&tool=pmcentrez&rendertype=abstract>
24. Yoganathan AP, Lemmon JD, Ellis JT. Heart Valve Dynamics. In: Bronzino JD, editor. *The Biomedical Engineering Handbook*. 2nd ed. Boca Raton: CRC Press LLC; 2000.
25. Rahman S, Eid N, Murarka S, Heuser R. Remodeling of the mitral valve using radiofrequency energy : review of a new treatment modality for mitral regurgitation. *Cardiovascular Revascularization Medicine ...* [Internet]. Elsevier Inc.; 2010 [cited 2012 Aug 8];11(4):249–59. Available from: <http://dx.doi.org/10.1016/j.carrev.2009.10.004>
26. Misfeld M, Sievers H-H. Heart valve macro- and microstructure. *Philosophical transactions of the Royal Society of London. Series B, Biological sciences* [Internet]. 2007 Aug 29 [cited 2012 Mar 21];362(1484):1421–36. Available from: <http://www.pubmedcentral.nih.gov/articlerender.fcgi?artid=2440405&tool=pmcentrez&rendertype=abstract>
27. Cleveland Clinic. Aorta anatomy [Internet]. Heart and Vascular Institute (Miller Family). 2012 [cited 2012 Aug 8]. Available from: <http://my.clevelandclinic.org/heart/heart-blood-vessels/aorta.aspx>
28. Atkins BZ, Kon ND, Hughes GC. Contemporary considerations in aortic valve surgery. In: Wang A, Bashore TM, editors. *Contemporary Cardiology: Valvular Heart Disease* [Internet]. Totowa, NJ: Humana Press; 2009 [cited 2012 Jul 8]. p. 281–310. Available from: <http://www.springerlink.com/index/10.1007/978-1-59745-411-7>
29. Edward Lifesciences. How do heart valves work [Internet]. Heart Basics. 2012 [cited 2012 Aug 8]. Available from: <http://www.yourheartvalve.com/heartbasics/pages/heartvalves.aspx>
30. Marino B, Digilio MC. Congenital heart disease and genetic syndromes: specific correlation between cardiac phenotype and genotype. *Cardiovascular pathology : the official journal of the Society for Cardiovascular Pathology* [Internet]. 2000;9(6):303–15. Available from: <http://www.ncbi.nlm.nih.gov/pubmed/11146300>
31. Nucleus Medical Media Inc. Aortic Insufficiency [Internet]. Lifescript. 2009 [cited 2012 Jul 27]. Available from: [http://www.lifescript.com/health/centers/heart\\_health/related\\_conditions/aortic\\_insufficiency.aspx](http://www.lifescript.com/health/centers/heart_health/related_conditions/aortic_insufficiency.aspx)
32. The MetroHealth System. Obstructive defects (valvular stenosis and coarctation of aorta) [Internet]. MetroHealth Heart and Vascular Centre. 2012 [cited 2012 Jul 27]. Available from: <http://www.metrohealth.org/body.cfm?id=1529>
33. Park MK. *Pediatric Cardiology for Practitioners*. 5th ed. Philadelphia: Mosby Elsevier; 2008.
34. Domnina YA, Muñoz R, Kreutzer J, Morell VO. Pulmonary Stenosis. In: Munoz R, Morell V, Cruz E, Vetterly C, editors. *Critical Care of Children with Heart Disease: Basic Medical and Surgical Concepts* [Internet]. 1st ed. London: Springer-Verlag; 2010 [cited 2012 Jun 4]. p. 231–40. Available from: <http://www.springerlink.com/index/10.1007/978-1-84882-262-7>



35. Tamburino C, Ussia GP. Percutaneous treatment of left side cardiac valves A practical guide for the interventional cardiologist. 1st ed. Percutaneous Treatment of Left side Cardiac Valves. Springer-Verlag; 2010. p. 125–214.
36. Linefsky JP, Otto CM. Aortic valve disease. Medicine [Internet]. Elsevier Ltd; 2010 Oct [cited 2012 Jun 6];38(10):541–4. Available from: <http://linkinghub.elsevier.com/retrieve/pii/S1357303910001805>
37. Healthwise Incorporated. Aortic valve with stenosis [Internet]. MyHealth.Alberta.ca. 2011 [cited 2012 Jul 27]. Available from: <https://myhealth.alberta.ca/health/pages/conditions.aspx?hwid=zm2794&>
38. Shipton B, Wahba H. Valvular heart disease: review and update. American Family Physician [Internet]. 2001 [cited 2012 Jun 6];63(11):2201–8. Available from: [http://www.aafp.org/link\\_out%3Fpmid=11417772](http://www.aafp.org/link_out%3Fpmid=11417772)
39. Minich LL, Tani LY, Williams RV, Puchalski MD. Valve disease in children. In: Otto CM, Bonow RO, editors. Valvular heart disease: a companion to Braunwald's heart disease. 3rd ed. Philadelphia: Saunders: Elsevier; 2009. p. 399–423.
40. Esmaeilzadeh M, Naderi N, Tabaei A. Aortic atresia with normally developed left ventricle in a young adult. Cardiology Journal [Internet]. 2011 [cited 2012 Aug 8];18(3):304–6. Available from: [http://www.cardiologyjournal.org/inpress/2010\\_04\\_Esmaeilzadeh.pdf](http://www.cardiologyjournal.org/inpress/2010_04_Esmaeilzadeh.pdf)
41. Stephens EH, Kearney DL, Grande-Allen KJ. Insight into pathologic abnormalities in congenital semilunar valve disease based on advances in understanding normal valve microstructure and extracellular matrix. Cardiovascular pathology : the official journal of the Society for Cardiovascular Pathology [Internet]. Elsevier Inc.; 2012 [cited 2012 May 25];21(1):46–58. Available from: <http://www.ncbi.nlm.nih.gov/pubmed/21349746>
42. Fernandes SM, Sanders SP, Khairy P, Jenkins KJ, Gauvreau K, Lang P, et al. Morphology of bicuspid aortic valve in children and adolescents. Journal of the American College of Cardiology [Internet]. 2004 Oct 19 [cited 2012 Jun 1];44(8):1648–51. Available from: <http://www.ncbi.nlm.nih.gov/pubmed/15489098>
43. Fernandes S, Khairy P. Bicuspid aortic valve morphology and interventions in the young. Journal of the American College of Cardiology [Internet]. 2007 [cited 2012 Aug 8];49(22):2211–4. Available from: <http://www.sciencedirect.com/science/article/pii/S0735109707009837>
44. Yale University. Bicuspid Aortic Valve [Internet]. Atlas of Echocardiography. 1999 [cited 2012 Aug 8]. Available from: [http://www.yale.edu/imaging/echo\\_atlas/entities/aortic\\_stenosis\\_bicuspid.html](http://www.yale.edu/imaging/echo_atlas/entities/aortic_stenosis_bicuspid.html)
45. Lincoln J, Yutzey KE. Molecular and developmental mechanisms of congenital heart valve disease. Birth defects research. Part A, Clinical and molecular teratology [Internet]. 2011 Jun [cited 2012 May 25];91(6):526–34. Available from: <http://www.ncbi.nlm.nih.gov/pubmed/21538813>
46. Gazit AZ, Huddleston CB, Checchia P a, Fehr J, Pezzella a T. Care of the pediatric cardiac surgery patient-part 1. Current problems in surgery [Internet]. 2010 Mar [cited 2012 Jun 6];47(3):185–250. Available from: <http://www.ncbi.nlm.nih.gov/pubmed/20159189>
47. Shah PM. Tricuspid and Pulmonary Valve Disease Evaluation and Management. Revista Española de Cardiología (English Edition) [Internet]. Elsevier; 2010 Jan [cited 2012 Jun

- 6];63(11):1349–65. Available from:  
<http://linkinghub.elsevier.com/retrieve/pii/S1885585710702590>
48. Damien. Pulmonary atresia [Internet]. Damien's Habitat. 2012 [cited 2012 Aug 8]. Available from: <http://www.damiens-habitat.com/id13.html>
  49. Fox D, Devendra GP, Hart S a, Krasuski R a. When “blue babies” grow up: What you need to know about tetralogy of Fallot. *Cleveland Clinic Journal of Medicine* [Internet]. 2010 Nov [cited 2012 Mar 20];77(11):821–8. Available from: <http://www.ncbi.nlm.nih.gov/pubmed/21048055>
  50. A.D.A.M Inc. Absent pulmonary valve [Internet]. University of Maryland Medical Center. 2008 [cited 2012 Jul 27]. Available from: <http://www.umm.edu/imagepages/19876.htm>
  51. Nucleus Communications Inc. Mitral valve stenosis [Internet]. *emedicinehealth*. 2000 [cited 2012 Jul 27]. Available from: <http://www.emedicinehealth.com/script/main/art.asp?articlekey=135643&ref=136917>
  52. Barton KP, Kreutzer J, Morell VO, Muñoz R. Mitral Stenosis. In: Munoz R, Morell VO, Cruz EM, Vetterly C, editors. *Critical Care of Children with Heart Disease: Basic Medical and Surgical Concepts*. 1st ed. London: Springer; 2010. p. 301–12.
  53. Ismail I, Haverich A. Pathology and Classification of Mitral Valve disease. In: Bonser RS, Pagano D, Haverich A, editors. *Mitral Valve Surgery* [Internet]. London: Springer London; 2011 [cited 2012 Apr 27]. p. 21–9. Available from: <http://www.springerlink.com/index/10.1007/978-1-84996-426-5>
  54. Séguéla P-E, Houyel L, Acar P. Congenital malformations of the mitral valve. *Archives of cardiovascular diseases* [Internet]. 2011 Aug [cited 2012 Jun 6];104(8-9):465–79. Available from: <http://www.ncbi.nlm.nih.gov/pubmed/21944149>
  55. Augoustides JGT, Atluri P. Progress in mitral valve disease: understanding the revolution. *Journal of cardiothoracic and vascular anesthesia* [Internet]. Elsevier Inc.; 2009 Dec [cited 2012 Apr 3];23(6):916–23. Available from: <http://www.ncbi.nlm.nih.gov/pubmed/19944356>
  56. Children's Heart Specialists PSC. Mitral Valve Prolapse [Internet]. Children's Heart Specialists Medical Information. 2009 [cited 2012 Jul 27]. Available from: <http://mykentuckyheart.com/information/MitralValveProlapse.htm>
  57. Bruce CJ, Connolly HM. Right-sided valve disease deserves a little more respect. *Circulation* [Internet]. 2009 May 26 [cited 2012 Apr 7];119(20):2726–34. Available from: <http://www.ncbi.nlm.nih.gov/pubmed/19470901>
  58. Mancini MC. Tricuspid Atresia [Internet]. *Medscape Reference*. 2011 [cited 2012 Jul 27]. Available from: <http://emedicine.medscape.com/article/158359-overview#a0101>
  59. PubMed Health. Tricuspid Atresia [Internet]. A.D.A.M Medical Encyclopedia. 2011 [cited 2012 Jul 27]. Available from: <http://www.ncbi.nlm.nih.gov/pubmedhealth/PMH0002100/>
  60. Cruz EM, Kaufman J, Morell VO, Tissot C, Buckvold S, Goldberg S, et al. Ebstein's Disease. In: Munoz R, Morell V, Cruz E, Vetterly C, editors. *Critical Care of Children with Heart Disease: Basic Medical and Surgical Concepts* [Internet]. London: Springer London; 2010 [cited 2012 Jun 4]. p. 411–22. Available from: <http://www.springerlink.com/index/10.1007/978-1-84882-262-7>

61. Bittles A, Bower C, Hussain R, Glasson E. The four ages of Down syndrome. *The European Journal of Public Health* [Internet]. 2007 [cited 2012 Aug 8];17(2):221–5. Available from: <http://eurpub.oxfordjournals.org/content/17/2/221.short>
62. Domnina YA, Muñoz R, Kazmerski TM, Kreutzer J, Morell VO. Hypoplastic left heart syndrome. In: Munoz R, Morell V, Cruz E, Vetterly C, editors. *Critical Care of Children with Heart Disease: Basic Medical and Surgical Concepts* [Internet]. 1st ed. London: Springer; 2010 [cited 2012 Aug 8]. p. 323–30. Available from: <http://www.sciencedirect.com/science/article/pii/S000349759190978Y>
63. Sybert VP, Mccauley E. Turner's syndrome. *New England Journal of Medicine* [Internet]. 2004 [cited 2012 Aug 8];351:1227–38. Available from: <http://www.nejm.org/doi/full/10.1056/NEJMra030360>
64. Health Grades Inc. Prevalence and incidence of Stickler Syndrome [Internet]. Right Diagnosis. 2012 [cited 2012 Jul 27]. Available from: [http://www.rightdiagnosis.com/s/stickler\\_syndrome/prevalence.htm](http://www.rightdiagnosis.com/s/stickler_syndrome/prevalence.htm)
65. Luxenberg DM, Torchen L. Tetralogy of Fallot. In: Abdulla R, editor. *Heart Diseases in Children: A Pediatrician's Guide* [Internet]. Boston, MA: Springer US; 2011 [cited 2012 Jul 4]. p. 167–76. Available from: <http://www.springerlink.com/index/10.1007/978-1-4419-7994-0>
66. Shinebourne E, Babu-Narayan S, Carvalho J. Tetralogy of fallot: from fetus to adult. *Heart* [Internet]. 2006 [cited 2012 Aug 8];92:1353–9. Available from: <http://heart.bmj.com/content/92/9/1353.short>
67. Chrysostomou C, Domnina YA, Kazmerski TM, Muñoz R, Morell VO. Tetralogy of Fallot. In: Munoz R, Morell V, Cruz E, Vetterly C, editors. *Critical Care of Children with Heart Disease: Basic Medical and Surgical Concepts*. 1st ed. London: Springer-Verlag; 2010. p. 199–206.
68. Sharieff GQ, Wylie TW. Pediatric cardiac disorders. *The Journal of Emergency Medicine* [Internet]. 2004 Jan [cited 2012 Apr 4];26(1):65–79. Available from: <http://linkinghub.elsevier.com/retrieve/pii/S0736467903003032>
69. Chrysostomou C, Domnina YA, Kazmerski TM, Muñoz R, Morell VO. Tetralogy of Fallot with Pulmonary Atresia. In: Munoz R, Morell V, Cruz E, Vetterly C, editors. *Critical Care of Children with Heart Disease: Basic Medical and Surgical Concepts*. 1st ed. London: Springer-Verlag; 2010. p. 213–9.
70. Chrysostomou C, Tsifansky M, Morell VO. Tetralogy of Fallot with Absent Pulmonary Valve. In: Munoz R, Morell V, Cruz E, Vetterly C, editors. *Critical Care of Children with Heart Disease: Basic Medical and Surgical Concepts*. 1st ed. London: Springer-Verlag; 2010. p. 207–11.
71. Hepburn L, Kelleher A. Grown-up congenital heart disease. *Anaesthesia & Intensive Care Medicine* [Internet]. 2009 [cited 2012 Aug 8];10(9):451–6. Available from: <http://www.sciencedirect.com/science/article/pii/S1472029909001519>
72. Mayo Clinic. Hypoplastic Left Heart Syndrome [Internet]. Mayo Clinic Health Information. 2012 [cited 2012 Jul 27]. Available from: <http://www.mayoclinic.org/hlhs/enlargeimage1519.html>

73. Johnson WH, Moller J. Pediatric Cardiology: The Essential Pocket Guide [Internet]. 2nd ed. Oxford: Wiley-Blackwell; 2008 [cited 2012 Aug 8]. Available from: [http://books.google.com/books?hl=en&lr=&id=laT22uYsLP4C&oi=fnd&pg=PT7&dq=Pediatric+Cardiology+The+Essential+Pocket+Guide&ots=o7nK8qufVK&sig=s-MQ4KkgvPMSD-jX\\_00Ahcf6t-A](http://books.google.com/books?hl=en&lr=&id=laT22uYsLP4C&oi=fnd&pg=PT7&dq=Pediatric+Cardiology+The+Essential+Pocket+Guide&ots=o7nK8qufVK&sig=s-MQ4KkgvPMSD-jX_00Ahcf6t-A)
74. Feinstein J a, Benson DW, Dubin AM, Cohen MS, Maxey DM, Mahle WT, et al. Hypoplastic left heart syndrome: current considerations and expectations. *Journal of the American College of Cardiology* [Internet]. Elsevier Inc.; 2012 Jan 3 [cited 2012 Jul 18];59(1 Suppl):S1–42. Available from: <http://www.ncbi.nlm.nih.gov/pubmed/22192720>
75. A.D.A.M Inc. Ebstein's Anomaly [Internet]. University of Maryland Medical Center. 2008 [cited 2012 Jul 27]. Available from: <http://www.umm.edu/imagepages/19884.htm>
76. Narvencar KPS, Karina A, Patil VR. Shone's Complex. *JAPI* [Internet]. 2009 [cited 2012 Aug 8];57(May):415–7. Available from: [http://www.japi.org/may\\_2009/article\\_12.pdf?q=shones](http://www.japi.org/may_2009/article_12.pdf?q=shones)
77. Hoffman JIE, Kaplan S. The incidence of congenital heart disease. *Journal of the American College of Cardiology* [Internet]. 2002 Jun 19;39(12):1890–900. Available from: <http://www.ncbi.nlm.nih.gov/pubmed/12084585>
78. Parker MW, Thompson PD. Exercise in valvular heart disease: risks and benefits. *Progress in cardiovascular diseases* [Internet]. Elsevier B.V.; 2011 [cited 2012 Apr 14];53(6):437–46. Available from: <http://www.ncbi.nlm.nih.gov/pubmed/21545930>
79. Health Grades Inc. Ehler-Danlos syndrome [Internet]. Right Diagnosis. 2012 [cited 2012 Jul 27]. Available from: [http://www.rightdiagnosis.com/e/ehlers\\_danlos\\_syndrome/prevalence.htm#prevalence\\_intro](http://www.rightdiagnosis.com/e/ehlers_danlos_syndrome/prevalence.htm#prevalence_intro)
80. Tsifansky M, Muñoz R, Morell VO. Left Ventricular Outflow Tract Obstruction. In: Munoz R, Morell V, Cruz E, Vetterly C, editors. *Critical Care of Children with Heart Disease: Basic Medical and Surgical Concepts* [Internet]. 1st ed. London: Springer; 2010 [cited 2012 Jun 4]. Available from: <http://www.springerlink.com/index/10.1007/978-1-84882-262-7>
81. Pober B. Williams–Beuren syndrome. *New England Journal of Medicine* [Internet]. 2010 [cited 2012 Aug 8];362:239–52. Available from: <http://www.nejm.org/doi/full/10.1056/NEJMra0903074>
82. van der Burgt I. Noonan syndrome. *Orphanet journal of rare diseases* [Internet]. 2007 Jan [cited 2012 Mar 29];2(4). Available from: <http://www.pubmedcentral.nih.gov/articlerender.fcgi?artid=1781428&tool=pmcentrez&rendertype=abstract>
83. Thompson WR, Yosowitz T, Stone S. Pediatric Echocardiography. In: Abdulla R, editor. *Heart Diseases in Children: A Pediatrician's Guide* [Internet]. Boston, MA: Springer US; 2011 [cited 2012 Jul 4]. Available from: <http://www.springerlink.com/index/10.1007/978-1-4419-7994-0>
84. Stout KK, Otto CM. Aortic Valve Disease. *Medicine* [Internet]. 2002 May;30(5):114–7. Available from: <http://linkinghub.elsevier.com/retrieve/pii/S1357303906003471>
85. National Heart Lung and Blood Institute. What to expect during transesophageal echocardiography [Internet]. *Transesophageal Echocardiography*. 2012 [cited 2012 Jul 27]. Available from: <http://www.nhlbi.nih.gov/health/health-topics/topics/tee/during.html>

86. Lang RM, Tsang W, Weinert L, Mor-Avi V, Chandra S. Valvular heart disease. The value of 3-dimensional echocardiography. *Journal of the American College of Cardiology* [Internet]. Elsevier Inc.; 2011 Nov 1 [cited 2012 May 12];58(19):1933–44. Available from: <http://www.ncbi.nlm.nih.gov/pubmed/22032703>
87. Feltes TF, Bacha E, Beekman RH, Cheatham JP, Feinstein J a, Gomes AS, et al. Indications for cardiac catheterization and intervention in pediatric cardiac disease: a scientific statement from the American Heart Association. *Circulation* [Internet]. 2011 Jun 7 [cited 2012 May 29];123(22):2607–52. Available from: <http://www.ncbi.nlm.nih.gov/pubmed/21536996>
88. A.D.A.M Inc. Left heart catheterization [Internet]. University of Maryland Medical Center. 2008 [cited 2012 Jul 27]. Available from: <http://www.umm.edu/imagepages/18143.htm>
89. Perlowski A, St Goar F, Glower DG, Feldman T. Percutanenous therapies for mitral regurgitation. *Current problems in cardiology* [Internet]. Elsevier Inc.; 2012 Feb [cited 2012 Apr 11];37(2):42–68. Available from: <http://www.ncbi.nlm.nih.gov/pubmed/22230740>
90. Hayek E, Griffin BP. Current medical management of valvular heart disease. *Cleveland Clinic journal of medicine* [Internet]. 2001 Oct;68(10):881–7. Available from: <http://www.ncbi.nlm.nih.gov/pubmed/11596627>
91. Joffs C, Sade RM. Congenital Heart Surgery Nomenclature and Database Project: Palliation, Correction or Repair? *Annals of Thoracic Surgery*. 2000;69:S369–72.
92. Brunicardi FC, Anderson DK, Billiar TR, Dunn DL, Hunter JG, Matthews DB, et al., editors. *Schwartz's principles of surgery* [Internet]. 9th ed. McGraw-Hill; 2005 [cited 2012 Aug 8]. Available from: <http://www.lavoisier.fr/livre/notice.asp?id=OOLWRKARO6OOWW>
93. WebMD Inc. Balloon valvuloplasty for narrowed cardiac valves [Internet]. *Interventional Cardiology Ass, PA*. 2002 [cited 2012 Jul 28]. Available from: <http://www.katycardiology.com/procedures/>
94. Balmer C, Beghetti M, Fasnacht M, Arbenz U. Balloon aortic valvoplasty in paediatric patients: progressive aortic regurgitation is common. *Heart* [Internet]. 2004 [cited 2012 Aug 8];90:77–81. Available from: <http://heart.bmj.com/content/90/1/77.short>
95. Feldman T. Percutaneous balloon valvuloplasty and mitral valve repair. In: Wang A, Bashore TM, editors. *Contemporary Cardiology: Valvular Heart Disease* [Internet]. Totowa, NJ: Humana Press; 2009 [cited 2012 Jul 8]. p. 393–409. Available from: <http://www.springerlink.com/index/10.1007/978-1-59745-411-7>
96. Dworakowski R, Prendergast B, Wendler O, MacCarthy P. Valvular heart disease: percutaneous alternatives. *Medicine* [Internet]. Elsevier Ltd; 2010 Oct [cited 2012 Jun 3];38(10):550–4. Available from: <http://linkinghub.elsevier.com/retrieve/pii/S1357303910001787>
97. Abdallah HM. Congenital Heart Defects [Internet]. The Children's Heart Institute. 2012 [cited 2012 Jul 19]. Available from: <http://www.childrensheartinstitute.org/educate/defects/defects.htm>
98. Yuan S-M, Jing H. Palliative procedures for congenital heart defects. *Archives of cardiovascular diseases* [Internet]. 2009 [cited 2012 Jul 20];102(6-7):549–57. Available from: <http://www.ncbi.nlm.nih.gov/pubmed/19664575>

99. Kisslo JA, B. AD, Leech GJ. Essentials of Echocardiography Surgical Procedures for Congenital Heart disease [Internet]. Echo in Context. 2000 [cited 2012 Aug 8]. Available from: [http://www.echoincontext.com/advanced/chd\\_22.asp](http://www.echoincontext.com/advanced/chd_22.asp)
100. Pick A. Heart valve surgery resources for patients and caregivers [Internet]. Heart Valve Surgery.com. 2012 [cited 2012 Jul 28]. Available from: <http://www.heart-valve-surgery.com/>
101. Butany J, Ahluwalia M, Munroe C, Fayet C, Ahn C, Blit P, et al. Mechanical heart valve prostheses:: identification and evaluation (erratum). Cardiovascular Pathology [Internet]. 2003 [cited 2012 Jul 30];12:322–44. Available from: <http://www.sciencedirect.com/science/article/pii/S1054880703001054>
102. Nair K, Muraleedharan C, Bhuvaneshwar G. Developments in mechanical heart valve prosthesis. Sadhana [Internet]. 2003 [cited 2012 Aug 9];28(June/August Parts 3 & 4):575–87. Available from: <http://www.springerlink.com/index/4741263G682J0886.pdf>
103. Pibarot P, Dumesnil JG. Prosthetic heart valves: selection of the optimal prosthesis and long-term management. Circulation [Internet]. 2009 Feb 24 [cited 2012 Jul 15];119(7):1034–48. Available from: <http://www.ncbi.nlm.nih.gov/pubmed/19237674>
104. Blot WJ, Ibrahim M a, Ivey TD, Acheson DE, Brookmeyer R, Weyman A, et al. Twenty-five-year experience with the Björk-Shiley convexoconcave heart valve: a continuing clinical concern. Circulation [Internet]. 2005 May 31 [cited 2012 Jul 30];111(21):2850–7. Available from: <http://www.ncbi.nlm.nih.gov/pubmed/15927993>
105. DeWall R a, Qasim N, Carr L. Evolution of mechanical heart valves. The Annals of thoracic surgery [Internet]. 2000 May;69(5):1612–21. Available from: <http://www.ncbi.nlm.nih.gov/pubmed/10881865>
106. Gott VL, Alejo DE, Cameron DE. Mechanical heart valves: 50 years of evolution. The Annals of Thoracic Surgery [Internet]. 2003 Dec [cited 2012 Apr 3];76(6):S2230–S2239. Available from: <http://linkinghub.elsevier.com/retrieve/pii/S0003497503018150>
107. Menon RG, AlDelamie T, Valliathu J, Zacharias S, Al Lawati A. Pediatric valve replacement: 15 years experience in Oman. Indian Journal of Thoracic and Cardiovascular Surgery [Internet]. 2006 [cited 2012 Aug 9];22:173–7. Available from: <http://www.springerlink.com/index/FW7M42VV40789V7L.pdf>
108. Elliott M, de Leval M. Valve replacement in children. World Journal of Surgery [Internet]. 1985 [cited 2012 Aug 9];9:568–78. Available from: <http://www.ncbi.nlm.nih.gov/pubmed/884814>
109. Antunes MD. Prosthetic heart valve replacement. Choice of prosthesis in a young, underdeveloped population group. South African medical journal = Suid-Afrikaanse tydskrif vir geneeskunde [Internet]. 1985 Nov 9;68(10):755–8. Available from: <http://www.ncbi.nlm.nih.gov/pubmed/3904038>
110. Tiete AR, Sachweh JS, Groetzner J, Gulbins H, Muehler EG, Messmer BJ, et al. Systemic mechanical heart valve replacement in children under 16 years of age. Clinical research in cardiology : official journal of the German Cardiac Society [Internet]. 2006 May [cited 2012 Jun 4];95(5):281–8. Available from: <http://www.ncbi.nlm.nih.gov/pubmed/16680580>
111. Daou L, Sidi D, Mauriat P, Butera G, Kachaner J, Vouhé PR, et al. Mitral valve replacement with mechanical valves in children under two years of age. The Journal of thoracic and

- cardiovascular surgery [Internet]. 2001 May [cited 2012 Jul 30];121(5):994–6. Available from: <http://www.ncbi.nlm.nih.gov/pubmed/11326249>
112. Lubiszewska B, Rozanski J, Szufladowicz M, Szaroszyk W, Hoffman P, Ksiezycka E, Rydlewska-Sadowska W, Ruzylo W. Mechanical valve replacement in congenital heart disease in children. *Journal of Heart Valve Disease*. 1998;8(1):74–9.
  113. Popov A-F, Coskun KO, Tirilomis T, Schmitto JD, Hinz J, Kriebel T, et al. Mechanical aortic valve replacement in children and adolescents after previous repair of congenital heart disease. *Artificial organs* [Internet]. 2009 Nov [cited 2012 Jun 4];33(11):915–21. Available from: <http://www.ncbi.nlm.nih.gov/pubmed/19817736>
  114. Alexiou C, McDonald A, Langley SM, Dalrymple-Hay MJ, Haw MP, Monro JL. Aortic valve replacement in children: are mechanical prostheses a good option? *European journal of cardio-thoracic surgery : official journal of the European Association for Cardio-thoracic Surgery* [Internet]. Department of Cardiac Surgery, The General Hospital, Tremona Road, Southampton, UK.; 2000 Feb;17(2):125–33. Available from: <http://ukpmc.ac.uk/abstract/MED/10731647>
  115. Arnold R, Ley-Zaporozhan J, Ley S, Loukanov T, Sebening C, Kleber J-B, et al. Outcome after mechanical aortic valve replacement in children and young adults. *The Annals of thoracic surgery* [Internet]. 2008 Mar [cited 2012 Jul 30];85(2):604–10. Available from: <http://www.ncbi.nlm.nih.gov/pubmed/18222274>
  116. Masuda M, Kado H, Tatewaki H, Shiokawa Y, Yasui H. Late results after mitral valve replacement with bileaflet mechanical prosthesis in children: evaluation of prosthesis-patient mismatch. *The Annals of thoracic surgery* [Internet]. 2004 Mar [cited 2012 Jul 30];77(3):913–7. Available from: <http://www.ncbi.nlm.nih.gov/pubmed/14992898>
  117. Edwin F, Aniteye E, Tettey MM, Tamatey M, Frimpong-Boateng K. Outcome of left heart mechanical valve replacement in West African children- A 15-year retrospective study. *Journal of cardiothoracic surgery* [Internet]. BioMed Central Ltd; 2011 Jan [cited 2012 Jun 4];6(1):57. Available from: <http://www.pubmedcentral.nih.gov/articlerender.fcgi?artid=3107788&tool=pmcentrez&rendertype=abstract>
  118. Turrentine M, Ruzmetov M, Vijay P, Randall G, Brown J. Biological versus mechanical aortic valve replacement in children. *The Annals of Thoracic Surgery* [Internet]. 2001 [cited 2012 Aug 9];71:356–60. Available from: <http://www.sciencedirect.com/science/article/pii/S0003497501025073>
  119. Sorin Group. Mechanical Valves - Carbomedics product line [Internet]. Medical Professionals Heart Valves. 2012 [cited 2012 Jul 29]. Available from: <http://www.sorin.com/products/international/8/category/88/127#product-1873>
  120. Wearden PD. Prosthetic Valves. In: Munoz R, Morell V, Cruz E, Vetterly C, editors. *Critical Care of children with Heart Disease: Basic Medical and Surgical Concepts* [Internet]. 1st ed. London: Springer; 2010 [cited 2012 Jun 4]. p. 313–22. Available from: <http://www.springerlink.com/index/10.1007/978-1-84882-262-7>
  121. Medtronic Inc. Hall easy-fit mechanical valve [Internet]. *Heart Valve Disease*. 2012 [cited 2012 Aug 4]. Available from: <http://www.medtronic.com/patients/heart-valve-disease/about-surgery/our-heart-valve-products/hall-easy-fit-mechanical-valve/index.htm>

122. Husain SA, Brown JW. When reconstruction fails or is not feasible: valve replacement options in the pediatric population. *Seminars in thoracic and cardiovascular surgery. Pediatric cardiac surgery annual* [Internet]. 2007 Jan [cited 2012 Apr 6];10:117–24. Available from: <http://www.ncbi.nlm.nih.gov/pubmed/17434003>
123. Suri V, Keepanasseril A, Aggarwal N, Chopra S, Bagga R, Sikka P, et al. Mechanical valve prosthesis and anticoagulation regimens in pregnancy: a tertiary centre experience. *European journal of obstetrics, gynecology, and reproductive biology* [Internet]. 2011 Dec [cited 2012 Jun 4];159(2):320–3. Available from: <http://www.ncbi.nlm.nih.gov/pubmed/21962462>
124. Piazza N, Bleiziffer S, Brockmann G, Hendrick R, Deutsch M-A, Opitz A, et al. Transcatheter aortic valve implantation for failing surgical aortic bioprosthetic valve: from concept to clinical application and evaluation (part 1). *JACC. Cardiovascular interventions* [Internet]. Elsevier Inc.; 2011 Jul [cited 2012 Aug 5];4(7):721–32. Available from: <http://www.ncbi.nlm.nih.gov/pubmed/21777879>
125. Bloomfield P. Valve disease Choice of heart valve prosthesis. *Heart (British Cardiac Society)* [Internet]. 2002 Jun;87(6):583–9. Available from: <http://www.pubmedcentral.nih.gov/articlerender.fcgi?artid=1767148&tool=pmcentrez&rendertype=abstract>
126. Sfyridis P, Avramidis P, Kirvassilis GV, Zavaropoulos PN, Papagiannis JK, Sarris G. The Contegra® Valved Heterograft Conduit for Right Ventricular Outflow Tract Reconstruction: A Reliable Solution. *Hellenic Journal of Cardiology* [Internet]. 2011 [cited 2012 Aug 5];52:501–8. Available from: [http://hellenicjcardiol.com/archive/full\\_text/2011/6/2011\\_6\\_501.pdf](http://hellenicjcardiol.com/archive/full_text/2011/6/2011_6_501.pdf)
127. Funder JA. Current status on stentless aortic bioprosthesis: a clinical and experimental perspective. *European journal of cardio-thoracic surgery : official journal of the European Association for Cardio-thoracic Surgery* [Internet]. 2012 Apr [cited 2012 Jun 4];41(4):790–9. Available from: <http://www.ncbi.nlm.nih.gov/pubmed/22219434>
128. Emani SM. Options for Prosthetic Pulmonary Valve Replacement. *Pediatric Cardiac Surgery Annual* [Internet]. Elsevier Inc.; 2012;15(1):34–7. Available from: <http://dx.doi.org/10.1053/j.pcsu.2012.01.015>
129. CryoLife® Inc. CryoValve® SG pulmonary human heart valve The ideal valve® for RVOT reconstruction and the Ross procedure [Internet]. *Products and Services*. 2012 [cited 2012 Aug 4]. Available from: <http://www.cryolife.com/products/synergraft-technologies/cryovalve-sg-pulmonary-human-heart-valve>
130. Allen B, El-Zein C, Cuneo B, Cava JP, Barth MJ, Ilbawi MN. Pericardial tissue valves and Gore-Tex conduits as an alternative for right ventricular outflow tract replacement in children. *Annals of Thoracic Surgery* [Internet]. 2002 [cited 2012 Aug 9];74:771–7. Available from: <http://www.sciencedirect.com/science/article/pii/S0003497502037670>
131. Yu J-H, Guo H, Zhang G, Wu S, Song G-M, Sun W-Y. Valve replacement in pediatric patients: a single center experience. *Chinese Medical Journal* [Internet]. 2011 [cited 2012 Aug 9];124(2):218–22. Available from: <http://www.cmj.org/Periodical/abstractlist.asp?titleid=LW2011123841805409921>
132. Dittrich S, Alexi-Meskishvili VV, Yankah a C, Dähnert I, Meyer R, Hetzer R, et al. Comparison of porcine xenografts and homografts for pulmonary valve replacement in children. *The Annals of Thoracic Surgery* [Internet]. 2000 Oct;70(3):717–22. Available from: <http://www.ncbi.nlm.nih.gov/pubmed/11016299>



133. Mohammadi H, Mequanint K. Prosthetic aortic heart valves: modeling and design. *Medical engineering & physics* [Internet]. Institute of Physics and Engineering in Medicine; 2011 Mar [cited 2012 Mar 19];33(2):131–47. Available from: <http://www.ncbi.nlm.nih.gov/pubmed/20971672>
134. Karamlou T, Jang K, Williams WG, Caldarone C a, Van Arsdel G, Coles JG, et al. Outcomes and associated risk factors for aortic valve replacement in 160 children: a competing-risks analysis. *Circulation* [Internet]. 2005 Nov 29 [cited 2012 Jul 7];112(22):3462–9. Available from: <http://www.ncbi.nlm.nih.gov/pubmed/16316968>
135. Brown JW, Ruzmetov M, Rodefeld MD, Vijay P, Darragh RK. Valved Bovine Jugular Vein Conduits for Right Ventricular Outflow Tract Reconstruction in Children: An Attractive Alternative to Pulmonary Homograft. *The Annals of Thoracic Surgery* [Internet]. 2006 Sep;82(3):909–16. Available from: <http://www.sciencedirect.com/science/article/pii/S0003497506004322>
136. Brown JW, Ruzmetov M, Eltayeb O, Rodefeld MD, Turrentine MW. Performance of SynerGraft decellularized pulmonary homograft in patients undergoing a Ross procedure. *The Annals of thoracic surgery* [Internet]. Elsevier Inc.; 2011 Feb [cited 2012 Jul 28];91(2):416–22; discussion 422–3. Available from: <http://www.ncbi.nlm.nih.gov/pubmed/21256282>
137. Vezmar M, Chaturvedi R, Lee K-J, Almeida C, Manlhiot C, McCrindle BW, et al. Percutaneous pulmonary valve implantation in the young 2-year follow-up. *JACC. Cardiovascular interventions* [Internet]. Elsevier Inc.; 2010 Apr [cited 2012 Jun 13];3(4):439–48. Available from: <http://www.ncbi.nlm.nih.gov/pubmed/20398873>
138. Abu-Omar Y, Ratnatunga CP. Prosthetic heart valves. *Surgery (Oxford)* [Internet]. 2007 May;25(5):224–7. Available from: <http://linkinghub.elsevier.com/retrieve/pii/S0263931907000609>
139. Travancas PR, Dorigo AH, Simões LC, Fonseca SC, Bloch KV, Herdy GV. Comparison of mechanical and biological prostheses when used to replace heart valves in children and adolescents with rheumatic fever. *Cardiology in the young* [Internet]. 2009 Apr [cited 2012 Jul 7];19(2):192–7. Available from: <http://www.ncbi.nlm.nih.gov/pubmed/19267944>
140. Sedrakyan A, Hebert P, Vaccarino V, Paltiel AD, Elefteriades JA, Mattera J, et al. Quality of life after aortic valve replacement with tissue and mechanical implants. *The Journal of Thoracic and Cardiovascular Surgery* [Internet]. 2004 Aug 1;128(2):266–72. Available from: <http://jtc.ctsnetjournals.org/cgi/content/abstract/128/2/266>
141. Erez E, Kanter KR, Isom E, Williams WH, Tam VKH. Mitral valve replacement in children. *Journal of Heart Valve Disease* [Internet]. 2003 [cited 2012 Aug 9];12(1):26–30. Available from: [http://www.icr-heart.com/journal/content/2003/jan/pdfs/Erez\\_1522.pdf](http://www.icr-heart.com/journal/content/2003/jan/pdfs/Erez_1522.pdf)
142. Alsoufi B. Aortic and mitral valve replacement in children: current options and outcomes. *Expert Review of Cardiovascular Therapy* [Internet]. 2011 Jul;9(7):805–9. Available from: <http://www.ncbi.nlm.nih.gov/pubmed/21809960>
143. Atik F a, Dias AR, Pomerantzeff PM, Barbero-Marcial M, Stolf N a, Jatene a D. Immediate and long term evolution of valve replacement in children less than 12 years old. *Arquivos brasileiros de cardiologia* [Internet]. 1999 Nov;73(5):424–8. Available from: <http://www.ncbi.nlm.nih.gov/pubmed/10887362>

144. Bartlett HL, Atkins DL, Burns TL, Engelkes KJ, Powell SJ, Hills CB, et al. Early outcomes of tricuspid valve replacement in young children. *Circulation* [Internet]. 2007 Jan 23 [cited 2012 Jun 4];115(3):319–25. Available from: <http://www.ncbi.nlm.nih.gov/pubmed/17200445>
145. Elkins RC, Thompson DM, Lane MM, Elkins CC, Peyton MD. Ross operation: 16-year experience. *The Journal of Thoracic and Cardiovascular Surgery* [Internet]. 2008 Sep;136(3):623–630.e5. Available from: <http://www.sciencedirect.com/science/article/pii/S0022522308010635>
146. Khwaja S, Nigro JJ, Starnes V a. The Ross procedure is an ideal aortic valve replacement operation for the teen patient. *Seminars in thoracic and cardiovascular surgery. Pediatric cardiac surgery annual* [Internet]. 2005 Jan [cited 2012 Jun 4];173–5. Available from: <http://www.ncbi.nlm.nih.gov/pubmed/15818374>
147. Alsoufi B, Fadel B, Bulbul Z, Al-Ahmadi M, Al-Fayyadh M, Kalloghlian A, et al. Cardiac reoperations following the Ross procedure in children: spectrum of surgery and reoperation results. *European journal of cardio-thoracic surgery : official journal of the European Association for Cardio-thoracic Surgery* [Internet]. 2012 Jan 20 [cited 2012 Apr 18];0:1–7. Available from: <http://www.ncbi.nlm.nih.gov/pubmed/22290910>
148. Kanter KR, Budde JM, Parks WJ, Tam VKH, Sharma S, Williams WH, et al. One hundred pulmonary valve replacements in children after relief of right ventricular outflow tract obstruction. *The Annals of thoracic surgery* [Internet]. 2002 Jul;73(6):1801–6; discussion 1806–7. Available from: <http://www.ncbi.nlm.nih.gov/pubmed/12078772>
149. Lim C, Lee JY, Kim W-H, Kim S-C, Song J-Y, Kim S-J, et al. Early replacement of pulmonary valve after repair of tetralogy: is it really beneficial? *European journal of cardio-thoracic surgery : official journal of the European Association for Cardio-thoracic Surgery* [Internet]. 2004 May [cited 2012 Jul 31];25(5):728–34. Available from: <http://www.ncbi.nlm.nih.gov/pubmed/15082274>
150. Guntehr T, Mazzitelli D, Schreiber C, Wottke M, Paek S-U, Meisner H, et al. Mitral valve replacement in children under 6 years of age. *European Journal of Cardio-thoracic Surgery* [Internet]. 2000 Oct;53(10):426–30. Available from: <http://www.ncbi.nlm.nih.gov/pubmed/16279585>
151. Alsoufi B, Manlhiot C, Al-Ahmadi M, McCrindle BW, Kalloghlian A, Sibli G, et al. Outcomes and associated risk factors for mitral valve replacement in children. *European journal of cardio-thoracic surgery : official journal of the European Association for Cardio-thoracic Surgery* [Internet]. 2011 Sep [cited 2012 Jun 4];40(3):543–51. Available from: <http://www.ncbi.nlm.nih.gov/pubmed/21353791>
152. Wren C, Sullivan JJO. Survival with congenital heart disease and need for follow up in adult life. *Heart*. 2001;85:438–43.
153. O’Gara PT, Bonow RO, Otto CM. Prosthetic Heart Valves. In: Otto C, Bonow R, editors. *Valvular heart disease: a companion to Braunwald’s heart disease*. 3rd ed. Philadelphia: Saunders Elsevier; 2009. p. 383–98.
154. Hijazi ZM. Transcatheter valve replacement: a new era of percutaneous cardiac intervention begins. *Journal of the American College of Cardiology* [Internet]. 2004 Mar 17 [cited 2012 Jul 5];43(6):1088–9. Available from: <http://www.ncbi.nlm.nih.gov/pubmed/15028371>
155. Heim F, Durand B, Chakfe N. Textile Heart Valve: Novel Shaping Process and Material Performances. *Materials and Manufacturing Processes* [Internet]. 2011 Oct [cited 2012 Jun

4];26(10):1303–9. Available from:  
<http://www.tandfonline.com/doi/abs/10.1080/10426914.2011.552018>

156. Mohr F-W. To beat or not to beat? From one size fits it all to an individual coronary revascularization strategy. *European Heart Journal* [Internet]. 2010 Oct [cited 2012 Jul 31];31(20):2441–3. Available from: <http://www.ncbi.nlm.nih.gov/pubmed/20729225>
157. Grunkemeier G, Li H, Naftel D, Starr A, Rahimtoola S. Long-term performance of heart valve prostheses. *Current Problems in Cardiology* [Internet]. 2000 [cited 2012 Jun 4];25(2):76–154. Available from: <http://www.ncbi.nlm.nih.gov/pubmed/10709140>
158. Deanfield J, Thaulow E, Warnes C, Webb G, Kolbel F, Hoffman A, et al. Management of grown up congenital heart disease the task force on the management of grown up congenital heart disease of the European Society of Cardiology. *European Heart Journal*. 2003;24:1035–84.
159. Kidane AG, Burriesci G, Cornejo P, Dooley A, Sarkar S, Bonhoeffer P, et al. Current developments and future prospects for heart valve replacement therapy. *Journal of Biomedical Materials Research. Part B, Applied Biomaterials* [Internet]. 2009 Jan [cited 2012 Mar 18];88(1):290–303. Available from: <http://www.ncbi.nlm.nih.gov/pubmed/18615473>
160. Narayan RL, Sharma SK. Looking to the future of percutaneous treatment of patients with valvular heart disease. *Interventional Cardiology Clinics* [Internet]. Elsevier Inc; 2012;1(1):139–49. Available from: <http://dx.doi.org/10.1016/j.iccl.2011.09.004>
161. Lutter G, Ardehali R, Cremer J, Bonhoeffer P. Percutaneous valve replacement: current state and future prospects. *The Annals of thoracic surgery* [Internet]. 2004 Dec [cited 2012 Apr 21];78(6):2199–206. Available from: <http://www.ncbi.nlm.nih.gov/pubmed/15561078>
162. Ghanbari H, Viatge H, Kidane AG, Burriesci G, Tavakoli M, Seifalian AM. Polymeric heart valves: new materials, emerging hopes. *Trends in Biotechnology* [Internet]. 2009 Jun [cited 2012 Mar 19];27(6):359–67. Available from: <http://www.ncbi.nlm.nih.gov/pubmed/19406497>
163. Grikscheit TC, Vacanti JP. The history and current status of tissue engineering: The future of pediatric surgery. *Journal of Pediatric Surgery* [Internet]. 2002 Mar [cited 2012 Jul 5];37(3):277–88. Available from:  
<http://linkinghub.elsevier.com/retrieve/pii/S0022346802164402>
164. Vesely I. Invited Review Transcatheter Valves : A Brave New World. *Journal of Heart Valve Disease* [Internet]. 2010 [cited 2012 Jun 24];19(5):543–58. Available from: [http://www.icr-heart.com/journal/content/2010/sep/pdfs/4258\\_Vesely.pdf](http://www.icr-heart.com/journal/content/2010/sep/pdfs/4258_Vesely.pdf)
165. Zegdi R, Khabbaz Z, Borenstein N, Fabiani J-N. A repositionable valved stent for endovascular treatment of deteriorated bioprostheses. *Journal of the American College of Cardiology* [Internet]. 2006 Oct 3 [cited 2012 Jun 24];48(7):1365–8. Available from: <http://www.ncbi.nlm.nih.gov/pubmed/17010796>
166. Nordmeyer J, Coats L, Lurz P, Lee T-Y, Derrick G, Rees P, et al. Percutaneous pulmonary valve-in-valve implantation: a successful treatment concept for early device failure. *European Heart Journal* [Internet]. 2008 Mar [cited 2012 Apr 23];29(6):810–5. Available from: <http://www.ncbi.nlm.nih.gov/pubmed/18316357>
167. Webb JG, Wood D a, Ye J, Gurvitch R, Masson J-B, Rodés-Cabau J, et al. Transcatheter valve-in-valve implantation for failed bioprosthetic heart valves. *Circulation* [Internet]. 2010

Apr 27 [cited 2012 Mar 16];121(16):1848–57. Available from:  
<http://www.ncbi.nlm.nih.gov/pubmed/20385927>

168. Baird CW, del Nido PJ, Emani SM, Geva T, Marx GR, Mcelhinney DB. Program spotlight: Congenital heart valve center [Internet]. Views Online Children's Hospital Boston. 2010 [cited 2012 Jul 28]. Available from:  
[http://www.childrenshospital.org/views/december10/congenital\\_heart\\_valve\\_center.html](http://www.childrenshospital.org/views/december10/congenital_heart_valve_center.html)
169. Carmen G, Levi D. Researchers develop revolutionary new heart for children. Science Daily Science News [Internet]. Los Angeles; 2006 Feb; Available from:  
<http://www.sciencedaily.com/releases/2006/02/060218114719.htm>
170. Vesely I. Heart valve tissue engineering. Circulation research [Internet]. 2005 Oct 14 [cited 2012 Mar 11];97(8):743–55. Available from: <http://www.ncbi.nlm.nih.gov/pubmed/16224074>
171. Schoen FJ. Heart valve tissue engineering: quo vadis? Current Opinion in Biotechnology [Internet]. Elsevier Ltd; 2011 Oct [cited 2012 Mar 18];22(5):698–705. Available from:  
<http://www.ncbi.nlm.nih.gov/pubmed/21315575>
172. Hoerstrup SP. Media Briefing - EU Research and Innovation in Healthcare: Life Valve Project. Zurich; 2010.
173. Simin P, Kasimir M., Weigel G, Ullrich R, Salzer-Muhar U, Rieder E, et al. Early failure of the tissue engineered porcine heart valve Synergraft in pediatric patients. European Journal of Cardio-thoracic Surgery. 2003;23(6):1002–6.
174. Piazza N, Asgar A, Ibrahim R, Bonan R. Transcatheter mitral and pulmonary valve therapy. Journal of the American College of Cardiology [Internet]. American College of Cardiology Foundation; 2009 May 19 [cited 2012 Apr 21];53(20):1837–51. Available from:  
<http://www.ncbi.nlm.nih.gov/pubmed/19442882>
175. Feldman T, Cilingiroglu M. Percutaneous leaflet repair and annuloplasty for mitral regurgitation. Journal of the American College of Cardiology [Internet]. Elsevier Inc.; 2011 Feb 1 [cited 2012 Apr 11];57(5):529–37. Available from:  
<http://www.ncbi.nlm.nih.gov/pubmed/21272742>
176. Harnek J, Webb JG, Kuck K, Tschöpe C, Vahanian A, Buller CE, et al. Transcatheter Implantation of the MONARC Coronary Sinus Device for Mitral Regurgitation 1-year results from the EVOLUTION phase 1 study (clinical evaluation of the Edwards Lifesciences percutaneous mitral annuloplasty system for the treatment of mitral re. Journal of the American College of Cardiology: Cardiovascular Interventions [Internet]. Elsevier Inc.; 2011;4(1):115–22. Available from: <http://dx.doi.org/10.1016/j.jcin.2010.08.027>
177. Chiam PTL, Ruiz CE. Percutaneous transcatheter mitral valve repair: a classification of the technology. Journal of the American College of Cardiology: Cardiovascular Interventions [Internet]. Elsevier Inc.; 2011 Jan [cited 2012 Apr 17];4(1):1–13. Available from:  
<http://www.ncbi.nlm.nih.gov/pubmed/21251623>
178. Padala M, Keeling WB, Guyton R a., Thourani VH. Innovations in therapies for heart valve disease. Circulation Journal: Official Journal of the Japanese Circulation Society [Internet]. 2011 [cited 2012 Apr 6];75(5):1028–41. Available from:  
<http://joi.jlc.jst.go.jp/JST.JSTAGE/circj/CJ-11-0289?from=CrossRef>

179. Maisano F, Alfieri O, La Canna G. Percutaneous mitral repair with the MitraClip. *Annales françaises d'anesthésie et de réanimation* [Internet]. 2011 May [cited 2012 Jun 4];30 Suppl 1:S33–7. Available from: <http://www.ncbi.nlm.nih.gov/pubmed/21703485>
180. Rodés-Cabau J. Transcatheter aortic valve implantation: current and future approaches. *Nature reviews. Cardiology* [Internet]. Nature Publishing Group; 2012 Jan [cited 2012 Mar 28];9(1):15–29. Available from: <http://www.ncbi.nlm.nih.gov/pubmed/22083020>
181. Attmann T, Quaden R, Jahnke T, Muller-Hulsbeck S, Boening A, Cremer J, et al. Percutaneous pulmonary valve replacement: 3-month evaluation of self-expanding valved stents. *The Annals of Thoracic Surgery* [Internet]. 2006 [cited 2012 Aug 9];82:708–13. Available from: <http://www.sciencedirect.com/science/article/pii/S0003497506002281>
182. Ghanbari H, Kidane AG, Burriesci G, Bonhoeffer P, Seifalian AM. Percutaneous heart valve replacement: an update. *Trends in Cardiovascular Medicine* [Internet]. 2008 May;18(4):117–25. Available from: <http://www.ncbi.nlm.nih.gov/pubmed/18555184>
183. Almond CS. The FDA review process for cardiac medical devices in children: A review for the clinician. *Progress in Pediatric Cardiology* [Internet]. Elsevier Ireland Ltd; 2012 May [cited 2012 May 7];33(2):105–9. Available from: <http://linkinghub.elsevier.com/retrieve/pii/S1058981312000203>
184. Fleming GA, Hill KD, Green AS, Rhodes JF. Progress in Pediatric Cardiology Percutaneous pulmonary valve replacement. *Progress in Pediatric Cardiology* [Internet]. Elsevier Ireland Ltd; 2012;33(2):143–50. Available from: <http://dx.doi.org/10.1016/j.ppedcard.2012.02.007>
185. Chiam PTL, Ruiz CE. Percutaneous transcatheter aortic valve implantation: Evolution of the technology. *American heart journal* [Internet]. Mosby, Inc.; 2009 Feb [cited 2012 Apr 4];157(2):229–42. Available from: <http://www.ncbi.nlm.nih.gov/pubmed/19185629>
186. Condado JA, Burger B. [Percutaneous treatment of heart valves]. *Revista española de cardiología* [Internet]. 2006 Dec;59(12):1225–31. Available from: <http://www.ncbi.nlm.nih.gov/pubmed/17194417>
187. Levi DS, Kusnezov N, Carman GP. Smart materials applications for pediatric cardiovascular devices. *Pediatric research* [Internet]. 2008 May;63(5):552–8. Available from: <http://www.ncbi.nlm.nih.gov/pubmed/18427301>
188. ValveXchange Inc. The Vitality Heart Valve System [Internet]. ValveXchange. 2011 [cited 2012 Aug 2]. Available from: [www.valvexchange.com](http://www.valvexchange.com)
189. Cooper DKC, Wicomb WN, Gould GM, Boonzaier D. Initial experimental experience with a “replaceable” cardiac valve prosthesis. *The Annals of Thoracic Surgery* [Internet]. The Society of Thoracic Surgeons; 1988 May [cited 2012 Jun 4];45(5):554–8. Available from: <http://linkinghub.elsevier.com/retrieve/pii/S0003497510645328>
190. Fukamachi K, Ootaki Y, Ootaki C, Akiyama M, Kamohara K, Cingoz F, et al. Innovative, replaceable heart valve: concept, in vitro study, and acute in vivo study. *Artificial Organs* [Internet]. 2007 Mar [cited 2012 Jun 4];32(3):226–39. Available from: <http://www.ncbi.nlm.nih.gov/pubmed/18201287>
191. Ebner A, Svensson GK-G, Chitwood WR, Sabik III JF, Svensson LG. Valve with exchangeable biologic leaflets. *The Journal of Thoracic and Cardiovascular Surgery* [Internet]. 2012 Aug;144(2):e13–e14. Available from: <http://www.sciencedirect.com/science/article/pii/S0022522312001730>

192. Armstrong EJ, Rogers JH. Next-generation transcatheter aortic valves. *Cardiac Interventions Today*. 2011;(September/October):66–9.
193. Feinstein J a, Kim N, Reddy VM, Perry SB. Percutaneous pulmonary valve placement in a 10-month-old patient using a hand crafted stent-mounted porcine valve. *Catheterization and Cardiovascular Interventions : Official Journal of the Society for Cardiac Angiography & Interventions [Internet]*. 2006 Apr [cited 2012 Aug 2];67(4):644–9. Available from: <http://www.ncbi.nlm.nih.gov/pubmed/16532496>
194. Bonhoeffer P, Boudjemline Y, Qureshi S a, Le Bidois J, Iserin L, Acar P, et al. Percutaneous insertion of the pulmonary valve. *Journal of the American College of Cardiology [Internet]*. 2002 May 15;39(10):1664–9. Available from: <http://www.ncbi.nlm.nih.gov/pubmed/12020495>
195. Boudjemline Y, Khambadkone S, Bonnet D, Derrick G, Agnoletti G, Deanfield J, et al. Percutaneous replacement of the pulmonary valve in a 12-year-old child. *Circulation [Internet]*. 2004 Nov 30 [cited 2012 Aug 2];110(22):e516. Available from: <http://www.ncbi.nlm.nih.gov/pubmed/15569846>
196. McElhinney DB, Hellenbrand WE, Zahn EM, Jones TK, Cheatham JP, Lock JE, et al. Short- and medium-term outcomes after transcatheter pulmonary valve placement in the expanded multicenter US Melody valve trial. *Circulation [Internet]*. 2010 Aug 3 [cited 2012 Apr 17];122(5):507–16. Available from: <http://www.ncbi.nlm.nih.gov/pubmed/20644013>
197. Khambadkone S, Bonhoeffer P. Percutaneous pulmonary valve implantation. *Seminars in thoracic and cardiovascular surgery. Pediatric cardiac surgery annual [Internet]*. 2006 Jan [cited 2012 Jun 15];23–8. Available from: <http://www.ncbi.nlm.nih.gov/pubmed/16638543>
198. Roberts P a, Boudjemline Y, Cheatham JP, Eicken A, Ewert P, McElhinney DB, et al. Percutaneous tricuspid valve replacement in congenital and acquired heart disease. *Journal of the American College of Cardiology [Internet]*. Elsevier Inc.; 2011 Jul 5 [cited 2012 Jun 7];58(2):117–22. Available from: <http://www.ncbi.nlm.nih.gov/pubmed/21718905>
199. Attmann T, Jahnke T, Quaden R, Boening A, Cremer J, Lutter G. Advances in Experimental Percutaneous Pulmonary Valve Replacement. *The Annals of Thoracic Surgery*. 2005;80:969–75.
200. Kütting M, Roggenkamp J, Urban U, Schmitz-Rode T, Steinseifer U. Polyurethane heart valves: past, present and future. *Expert Review of Medical Devices [Internet]*. 2011 Mar;8(2):227–33. Available from: <http://www.ncbi.nlm.nih.gov/pubmed/21381912>
201. Alferiev I, Stachelek SJ, Lu Z, Fu AL, Sellaro TL, Connolly JM, et al. Prevention of polyurethane valve cusp calcification with covalently attached bisphosphonate diethylamino moieties. *Journal of Biomedical Materials Research. Part A [Internet]*. 2003 Aug 1;66(2):385–95. Available from: <http://www.ncbi.nlm.nih.gov/pubmed/12889009>
202. Daebritz SH, Hermanns B, Schroeder J, Groetzner J, Autschbach R, Messmer BJ, et al. Introduction of a flexible polymeric heart valve prosthesis with special design for aortic position. *European Journal of Cardio-thoracic Surgery*. 2004;25:946–52.
203. Daebritz SH, Sachweh JS, Hermanns B, Fausten B, Franke A, Groetzner J, et al. Introduction of a flexible polymeric heart valve prosthesis with special design for mitral position. *Circulation [Internet]*. 2003 Sep 9 [cited 2012 Jun 4];108 Suppl:III134–9. Available from: <http://www.ncbi.nlm.nih.gov/pubmed/12970222>

204. Kidane AG, Burriesci G, Edirisinghe M, Ghanbari H, Bonhoeffer P, Seifalian AM. A novel nanocomposite polymer for development of synthetic heart valve leaflets. *Acta Biomaterialia* [Internet]. *Acta Materialia Inc.*; 2009 Sep [cited 2012 Mar 28];5(7):2409–17. Available from: <http://www.ncbi.nlm.nih.gov/pubmed/19497802>
205. Cardiac Health. Patent Foramen Ovale treatment [Internet]. *Atrial Septal Defect*. 2012 [cited 2012 Jul 28]. Available from: <http://www.cardiachealth.org/cardiac-healthcare-providers/surgical-anatomy/defects-with-a-left-to-right-shunt/asd>